

European
VitreoRetinal
Society



20th EVRS Meeting

*“Combined Retinal Surgeries,
Advances in Medical Retina & Imaging”*

August 31st | **2023**
September 3rd

Perissia Hotel & Convention Center
CAPPADOCIA TÜRKİYE



ABSTRACT BOOK

Dear Colleagues,

The European VitreoRetinal Society meeting will be held in Cappadoccia Türkiye between 31st August-3rd September 2023. The congress venue is unique with its natural volcanic remnants forming fairy chimneys, caves, undergrounds cities which will attract many ophthalmologists.

The theme of the meeting will be “Combined Retinal Surgeries and Advances in Medical Retina and Imaging” to cover cataract and glaucoma surgical topics in addition to retina to some extent.

We will announce our scientific program, which we are preparing with a rich content, as soon as possible.

We wish to meet at an unforgettable congress both scientifically and socially.

Best regards,



Giampaolo Gini
President of EVRS



Şengül Özdek
Secretary of EVRS

EVRS 2023 BOARD



Giampaolo Gini
President
Italy / UK



Barbara Parolini
Vice President
Italy



Şengül Özdek
Secretary
Türkiye



Ron Adelman
Scientific Director
USA



Ferenc Kuhn
ASRS Representative
USA



Hassan Mortada
Additional Board Member
Egypt




Nur Acar Göçgil
Additional Board Member
Türkiye




Ivan Fišer
Treasurer
Czech Republic

PROGRAM AT A GLANCE

AUGUST 31 ST , 2023 • THURSDAY			
HALL 1		HALL 2	
08.00-08.15	WELCOME		
08.15-09.25	Macular Surgery Session		
09.25-10.00	Panel by Turkish Ophthalmological Association on Vitreoretinal Interface	09.00-10.00	Course: Biosimilars in Ophthalmology
10.00-10.15	Debate on ILM (with or without flap)		
10.15-10.35	☕ Coffee Break		
10.35-10.50	OPENING CEREMONY		
10.50-11.25	Panel by All Indian Ophthalmology Society (AIOS): Surgery for Proliferative Diabetic Retinopathy - An Update		
11.25-12.15	Surgery for Proliferative Diabetic Retinopathy		
12.15-15.00	Live Surgery		
12.15-13.45	Live Surgery • 1 st Group		
13.00-14.00	🍴 Lunch		
13.45-15.00	Live Surgery • 2 nd Group		
15.00-15.30	Eurolam	15.00-16.00	Rapid Fire Talks on VMT ERM
15.30-16.00	Ocular Trauma Management		
16.00-16.30	☕ Coffee Break	16.00-17.00	Course: Surgery in Uveitis & Endophthalmitis
16.30-17.40	Surgical Tips & Tricks / Management of Complications (My way)		
17.40-18.10	Late Breaking Developments & Updates on Clinical Trials (BBC Style)		
18.10-18.40	Macular Hemorrhage		
20.00	🥂 WELCOME RECEPTION @ Perissia Hotel		

SEPTEMBER 1 ST , 2023 • FRIDAY			
HALL 1		HALL 2	
08.00-08.30	MEACO Panel	08.00-09.00	Course: Principles, Pitfalls and Artifacts in OCT and OCTA
08.30-09.00	Inherited Retinal Disorders / Stem Cell Treatments		
09.00-09.50	Controversies in Combined Surgeries (VRS with Cataract, keratoplasty or Glaucoma Surgeries)		
09.50-10.30	☕ Coffee Break	09.30-11.00	Course: ROP
10.30-12.00	Techniques on Secondary IOL implantation/IOL Dislocations	11.10-11.50	Rapid Fire Talks on Uveitis
12.00-12.15	Debate on Fixation (Iris vs scleral fixation)		
12.15-12.30	Debate on Scleral Fixation (Carlevale vs Yamane style)		
12.30-13.30	General Assembly and Election		
12.30-14.00	🍴 Lunch		
14.00-15.05	Innovations on Surgical Instrumentation / Artificial Intelligence	13.30-14.30	Rapid Fire Talks on Macular Holes
15.05-15.40	Panel by EGVRs: Challenging Situations in Vitreoretinal Surgery	14.40-15.30	Course: Trauma
15.40-16.05	Panel by ASRS: Advances in Retina	15.30-16.00	Rapid Fire Talks on Trauma
16.05-16.30	☕ Coffee Break	16.00-17.00	Rapid Fire Talks on ROP
16.30-17.00	EVRS Lecture	17.00-18.00	Course: Breaking the Retinal Barrier: Journey to the Subretina and Choroid
17.00-17.25	Challenging Cases of Medical Retina		
17.25-18.00	Panel: Challenging Cases of VRS		
18.00-18.30	EVRS My Worst & More Threatening Video: What to do and Not to do		
20.00	 GALA DINNER @ Kaya Hotel		

SEPTEMBER 2ND, 2023 • SATURDAY

HALL 1		HALL 2	
08.00-09.00	ROP	08.00-09.00	Course: PVR
09.00-09.15	Debate on ROP (to laser, not to laser)	09.00-10.00	Course: Management of Complex RRD and its Complications
09.15-10.35	Updates on Pediatric Vitreoretinal Surgery	10.00-11.00	Course: Social Media Strategies for Ophthalmologists
10.35-11.00	Zivojnovic Award and Lecture		
11.00-11.30	☕ Coffee Break		
11.30-11.55	Ocular Oncology	11.30-12.30	Course: Macular Buckle
11.55-12.30	Panel on Ocular Oncology		
12.30-13.00	Satellite Symposium 		
13.00-13.40	🍴 Lunch		
13.40-14.25	Update on Retinal Detachment (Risk, PNR, Buckle, Laser)	13.40-14.40	Rapid Fire Talks on Surgery
14.25-15.30	Update on Retinal Detachment (PPV)	14.40-15.40	Rapid Fire Talks on Diabetes
15.30-15.45	Debate on RD (PnR vs PPV)		
15.45-16.15	☕ Coffee Break		
16.15-16.45	Panel by GIVRE: VR Surgery - Surgical Management Techniques of ILM in FTMH: Videos Session		
16.45-17.45	Challenging Cases of Surgical Retina	16.45-17.45	Young EVRS Session
17.45-18.45	Course: Pneumatic Retinopexy		
20.00	🎉 FAREWELL PARTY @ Guray Museum		

SEPTEMBER 3RD, 2023 • SUNDAY

HALL 1		HALL 2	
08.00-08.30	Panel by APVRS: Updates on DME / Vein Occlusions		
08.30-09.00	Subthreshold Laser		
09.00-09.40	Updates on Retinal Vascular Diseases	09.00-09.30	EVRS Retina Premier League
09.40-10.20	AMD and Medical Retina		
10.20-10.35	Debate (Biosimilars vs original molecules)	10.00-11.00	Course: Ocular Oncology for Retina Specialists
10.35-11.00	☕ Coffee Break		
11.00-11.30	Panel by Turkish Ophthalmological Association: OCTA is a Must	11.10-12.10	Course: Diabetic Vitrectomy
11.30-12.25	Updates on Imaging		
12.25-14.00	Updates on Uveal Diseases & Endophthalmitis		
14.00-14.15	CLOSING CEREMONY		
14.15-15.00	🍴 Lunch		

AUGUST 31ST, 2023 • THURSDAY

HALL 1

08.00-08.15	WELCOME Moderator: Giampaolo Gini
08.15-09.25	Macular Surgery Session Moderators: Barbara Parolini, Giampaolo Gini
08.15-08.20	Introduction Barbara Parolini
08.20-08.25	Failed temporal inverted ILM flap in cases of FTMH, what to do next?! Mohamed Moghazy Mahgoub
08.25-08.30	Modified Inverted Internal Limiting Membrane Flap Technique in Macular Hole Surgery: Perfluorocarbon Iron Muhammed Nurullah Bulut
08.30-08.35	Surgical outcome of cabbage leaf technique of ILM peeling in large macular holes Neeraj Sanduja
08.35-08.40	A new finishing touch for the temporal inverted internal limiting membrane flap technique Ecem Önder Tokuç
08.40-08.45	Discussion on macular hole
08.45-08.50	Human amniotic membrane graft for chronic macular hole Cumali Değirmenci
08.50-08.55	Determination of postoperative positioning time after macular hole surgery by Optical Coherence Tomography Angiography (OCTA) İrem Kırıcı Doğan
08.55-09.00	Autologous Retinal Transplantation Mexican Consortium, experience of 100 cases Sergio Rojas Juárez
09.00-09.05	Discussion on macular hole
09.05-09.10	Prediction of functional and anatomical progression in lamellar macular holes Emanuele Crincoli
09.10-09.15	Long-term follow-up in the lamellar macular hole without vitrectomy Akın Çakır
09.15-09.20	Surgical outcomes for the treatment of tractional and degenerative lamellar macular holes Dong Young Park
09.20-09.25	Discussion on lamellar hole
09.25-10.00	Panel by Turkish Ophthalmological Association on Vitreoretinal Interface Moderators: Berati Hasanreisioğlu, Murat Öncel
09.25-09.30	Management of VMT - Gürsel Yılmaz
09.30-09.35	Alternative techniques for recurrent macular holes - Levent Karabaş
09.35-09.40	Update on idiopathic ERM - Nilüfer Koçak
09.40-09.45	Lamellar Holes: Whom to operate - Sinan Tatlıpınar
09.45-09.50	Can intraoperative OCT enhance macular surgery?- Murat Öncel
09.50-10.00	Discussion
10.00-10.15	Debate Moderator: Özgür Artunay
10.00-10.05	ILM peel without ILM flap - Gökhan Gürelik
10.05-10.10	ILM peel with ILM flap - Atul Dhawan
10.10-10.15	Votes
10.15-10.35	 Coffee Break

AUGUST 31 ST , 2023 • THURSDAY	
HALL 1	
10.35-10.50	OPENING CEREMONY Giampaolo Gini
10.50-11.25	Panel by All Indian Ophthalmology Society (AIOS): Surgery for Proliferative Diabetic Retinopathy - An Update Moderators: Anand Rajendran, Atul Dhawan
10.50-10.55	Case selection and preoperative consideration Anand Rajendran
10.55-11.00	Tips in diabetic MIVS (Pre-Op Anti-VEGF, Membrane Surgery, Gas vs Oil , Laser) Sangeet Mittal
11.00-11.05	Role of bimanual surgery in diabetic Tractional Retinal Detachment Prashant Bawankule
11.05-11.10	Complication in surgery for diabetic vitrectomy: How to avoid and manage them Vaibhav Sethi
11.10-11.15	Short Video Jayanto Guha
11.15-11.25	Discussion
11.25-12.15	Surgery for Proliferative Diabetic Retinopathy Moderators: Samir El Baha, David Pelayes
11.25-11.30	To the question of proliferative vitreoretinopathy classification Natalia Kisilitsyna
11.30-11.35	Trimanual vitrectomy for severe proliferative diabetic retinopathy Samir El Baha
11.35-11.40	Peripheral streak of pre-retinal hemorrhage after vitrectomy completion - A sign of Vitreoschisis - Sangeet Mittal
11.40-11.45	Diabetic vitrectomy: Mind set & different attack strategies Ahmed Mansour
11.45-11.50	Discussion
11.50-11.55	Surgical Outcomes of Mitomycin C in Severe Proliferative Diabetic Retinopathy Cases Gökhan Gürelık
11.55-12.00	Immediate sequential vitrectomy for diabetic retinopathy Katarzyna Chwiejczak
12.00-12.05	Diabetic tractional retinal detachment in Mexico Fausto Miguel Lechuga
12.05-12.10	ILM peeling in Diabetic Vitrectomy Susana Martinez
12.10-12.15	Discussion
12.15-15.00	Live Surgery
12.15-13.45	Live Surgery 1st Group Moderators: Barbara Parolini, Giampaolo Gini Surgeons: Şengül Özdek, Grazia Pertile, Remzi Avcı, Hassan Mortada Panellists: Sangeet Mittal, Stratos Gotzaridis
13.00-14.00	 Lunch
13.45-15.00	Live Surgery 2nd Group Moderators: Barbara Parolini, Giampaolo Gini Surgeons: Guido Prigione, Nur Acar Göçgil Panelists: Cengiz Aras, Mohamed Moghazy Mahgoub, Hany Hamza, Wei Chi Wu, Jayanto Guha


AUGUST 31ST, 2023 • THURSDAY

HALL 1


15.00-15.30	Eurolam Moderators: David Pelayes, Fausto Miguel Lechuga
15.00-15.05	Subretinal bleeding removal by active irrigation of BSS Jesus Gonzalez Cortes
15.05-15.10	Management of vitreoretinal surgical complex cases Pablo Chiaradia
15.10-15.15	Challenging vitrectomy in herpetic retinitis Rosy Romero
15.15-15.20	IOL iris fixation. Still a good option Susana Martinez
15.20-15.30	Discussion
15.30-16.00	Ocular Trauma Management Moderators: Hakan Durukan, Ahmed Mansour
15.30-15.35	Endoscope-assisted vitrectomy in the treatment of 133 severely traumatized eyes without light-perception - Yang Xun
15.35-15.40	Posterior segment intraocular foreign bodies: A 10-Year review Angelina Meireles
15.40-15.45	Penetrating Ocular Trauma, tips and tricks to expect the unexpected! Mohamed Moghazy Mahgoub
15.45-15.50	Prognostic factors for visual outcomes following intraocular foreign body removal Anum Haneef
15.50-15.55	Effect of adjuvant mitomycin-C in severe traumatic retinal detachments surgery with retinotomy-retinectomy - Burak Acar
15.55-16.00	Discussion
16.00-16.30	☕ Coffee Break
16.30-17.40	Surgical Tips & Tricks / Management of Complications (My way) Moderators: Ahmed Mansour, Çağrı Beşirli
16.30-16.35	Macular hole RD: Our novel flower petal technique - Ahmed Mansour
16.35-16.40	Management of retinal detachment with coexistent macular hole by submacular placement of retinal autograft - Levent Karabaş
16.40-16.45	A case of rhegmatogenous retinal detachment with an unpredictable macular tear treated with autologous retinal graft - Sibel Demirel
16.45-16.50	A sandwich method of amniotic membrane transplantation in a challenging case of high myopic macular hole associated retinal detachment - Omer Othman Abdullah
16.50-16.55	Biopsy techniques for posterior segment tissue sampling - Lyndon da Cruz
16.55-17.00	Toxicity risk in VR surgery - Mario Romano
17.00-17.05	Trans-choroidal hybrid technique in management of subretinal proliferation Maged Mikhael Gergess
17.05-17.10	Discussion
17.10-17.15	Dye-assisted occult retinal break detection in retinal detachment surgery Sema Tamer Kaderli
17.15-17.20	Risk factors and management of cystoid macular edema following pars plana vitrectomy for rhegmatogenous retinal detachment - Oumayma Elmansouri
17.20-17.25	Comparison of the efficacy and ocular surface effects of sutureless, suturation and external diathermy techniques used in the closure of sclerotomies after 25-Gauge Transconjunctival Vitrectomy - İrfan Akalın
17.25-17.30	Use of subretinal BBG Dye to localise a missing retinal hole in Rhegmatogenous Detachment - Nishikant Jaywant Borse
17.30-17.40	Discussion

AUGUST 31ST, 2023 • THURSDAY

HALL 1


17.40-18.10	Late Breaking Developments & Updates on Clinical Trials (BBC Style) Moderators: Mohamed Moghazy Mahgoub, Mohammed Tawfik
17.40-17.45	Update on DRCR clinical trials, 2023 Ron Adelman
17.45-17.50	Efficacy, durability, and safety of faricimab in diabetic macular edema: 2-Year results from the phase 3 YOSEMITE and RHINE trials Sibel Kadayıfçılar
17.50-17.55	Efficacy, safety, and durability of faricimab in neovascular Age-Related macular degeneration: Year 2 results from the phase 3 TENAYA and LUCERNE trials Levent Karabaş
17.55-18.00	Innovation in robotic design for VR surgery Lyndon da Cruz
18.00-18.05	Update on Geographic Atrophy Ron Adelman
18.05-18.10	Discussion
18.10-18.40	Macular Hemorrhage Moderators: Susana Teixeira, Jayanto Guha
18.10-18.15	Vitrectomy for sub ILM hemorrhage: Different causes and visual results? 3rd for the same author? Hany Hamza
18.15-18.20	Interoperative OCT in management of submacular hemorrhage, is it additional tool ?!! Maged Mikhael Gergess
18.20-18.25	Tissue plasminogen activator for the treatment of preretinal blood under silicone oil Fevzi Şentürk
18.25-18.30	Comparison of three different techniques in the management of submacular hemorrhage Anıl Korkmaz
18.30-18.35	Visual and anatomical results after vitrectomy with subretinal tPA injection in the Treatment of submacular hemorrhage secondary to Age-Related macular degeneration Serhat Ermiş
18.35-18.40	Discussion
20.00	 WELCOME RECEPTION @ Perissia Hotel

HALL 2

08.00-08.15	WELCOME Moderator: Giampaolo Gini
09.00-10.00	Course: Biosimilars in Ophthalmology Moderators: Alper Bilgiç, Jesus Gonzalez Cortes Biosimilar concept - Jesus Gonzalez Cortes The use of Biosimilars in Ophthalmology, indications and opportunities Shyamal Dwivedi Advantages and possible disadvantages of biosimilar drugs Aditya Sudhalkar Clinical Trials of Biosimilars in Ophthalmology, Real-world data about Biosimilar Se Joon Woo Biosimilars in the future - Alper Bilgiç Discussion
13.00-14.00	 Lunch

AUGUST 31ST, 2023 • THURSDAY

HALL 2

15.00-16.00	Rapid Fire Talks on VMT ERM Moderators: Maged Mikhael Gergess, Cengiz Aras Intraretinal hyperreflective lines in eyes with vitreomacular adhesion Fatma Bağcı Foveal avascular zone distortion in epiretinal membrane by optical coherence tomography angiography İlkay Kılıç Müftüoğlu Relationship between epiretinal membrane and pseudoexfoliation glaucoma Ekin Ece Oskan Discussion Epimacular membrane surgery. My way Wael Ahmed Ewais Factors related to cotton ball sign secondary to epiretinal membrane İlkay Kılıç Müftüoğlu Role of optical coherence tomography findings in visual prognosis after epiretinal membrane surgery Bilge Tarım The visual outcomes of idiopathic epiretinal membrane surgery in eyes with ectopic inner foveal layers Doğukan Cömerter Comparison of postoperative retinal displacement in diabetic and idiopathic epiretinal membranes Muhammed Numan Işın Discussion
16.00-17.00	Course: Surgery in Uveitis & Endophthalmitis Moderator: Ahmed Sallam Pars plana vitrectomy in uveitis and endophthalmitis - overview Ahmed Sallam Pars plana vitrectomy in uveitis- diagnostic and therapeutic indications Mohamed Moghazy Discussion 1: uveitis surgery How do you approach a post operative endophthalmitis based on presentation and available resources? Giampaolo Gini Surgery for post operative endophthalmitis and traumatic endophthalmitis Mohammed Tawfik
20.00	 WELCOME RECEPTION @ Perissia Hotel

SEPTEMBER 1ST, 2023 • FRIDAY

HALL 1

08.00-08.30 MEACO PanelModerator: **Abdul Aziz Badla**08.00-08.05 Recurrent retinal detachment under silicon oil
Ibrahim Bouassida08.05-08.10 PVR with multiple retinal tears
Hassan Mortada08.10-08.15 Giant retinal tears with PVR
Faisal Fayyad08.15-08.20 Roof-protected surgery in VMT syndrome
Remzi Avcı

08.20-08.30 Discussion

08.30-09.00 Inherited Retinal Disorders / Stem Cell TreatmentsModerators: **Nur Acar Göçgil, Ayşe Öner**08.30-08.35 Bone marrow-derived mesenchymal stem cell therapy in patients with retinitis pigmentosa
Nil İrem Uçgun08.35-08.40 Psychophysical assessment of low visual function in patients with retinitis pigmentosa with the full-field stimulus threshold (FST) test
Ayşe Öner08.40-08.45 Cystoid macular edema in rod dystrophy
Ivan Fišer08.45-08.50 Henle's Fiber Layer volumetric analysis in patients with cone dystrophy
Cem Kesim

08.50-09.00 Discussion

09.00-09.50 Controversies in Combined Surgeries (VRS with Cataract, keratoplasty or Glaucoma Surgeries)Moderators: **Sibel Demirel, Eleonora Lavaque**09.00-09.05 Effect of phacovitrectomy and prior lens status on the surgical outcomes of 23 gauge pars plana vitrectomy for primary rhegmatogenous retinal detachment
Şefik Can İpek09.05-09.10 Outcomes and complications of combined vs. sequential cataract and pars plana vitrectomy
Ahmed Sallam09.10-09.15 Postoperative refractive outcomes in eyes undergoing combined phacovitrectomy surgery for Epiretinal Membrane
Wilson Heriot

09.15-09.20 Discussion

09.20-09.25 Combined surgery of phacoemulsification, vitrectomy and implantation of Ahmed's valve in the treatment of neovascular glaucoma
Marko Ljubiša Zlatanovic09.25-09.30 Visual and anatomical outcomes of pars plana vitrectomy for dropped nucleus
Anum Haneef09.30-09.35 Buckle phaco vitrectomy for retinal detachment with PVR: Technique and outcome
Wael Ahmed Ewais09.35-09.40 InTraocular EMulsion of silicone oil (ITEMS) grading system: an evidence-based expert-led consensus
Mario Romano

09.40-09.50 Discussion

09.50-10.30 ☕ Coffee Break

SEPTEMBER 1ST, 2023 • FRIDAY

HALL 1

10.30-12.00	Techniques on Secondary IOL implantation/IOL Dislocations Moderators: Matteo Forlini, Levent Karabaş
10.30-10.35	Lasso and other techniques for management of dislocated IOLs Dhanashree Ratra
10.35-10.40	Visual and refractive outcomes of an opacified multifocal intraocular lens exchange. Can the bag be trusted? Abbas Fahem
10.40-10.45	Scleral Bridge IOL: A novel technique for IOL fixation in aphakia without capsular support Hany Hamza
10.45-10.50	Intravitreal needle technique for intrascleral haptic fixation of posteriorly dislocated three-piece intraocular lenses Tansu Erakgün
10.50-10.55	Retropupillary Iris-Claw lens Implantation in Aphakic eyes: Technique and Tips Wael Ahmed Ewais
10.55-11.00	Discussion
11.00-11.05	IOL exchange using Iris-Claw IOLs Matteo Forlini
11.05-11.10	Gore-Tex scleral fixed intraocular lenses refractive results Carla Perez Montano
11.10-11.15	Comparison of two sutureless techniques of scleral fixation of intraocular lens in surgical aphakia Gamze Dereli Can
11.15-11.20	Double rectangular scleral mesh (DRSM) for severely subluxated/Dislocated IOLs: A closed vitrectomy approach Ihab Saad Othman
11.20-11.25	Dislocated intraocular lenses - Tips and tricks of removal, repositioning and exchange Neeraj Sanduja
11.25-11.30	Discussion
11.30-11.35	Yamane technique highlights and our conclusions Alperen Bahar
11.35-11.40	Modified Yamane intrascleral haptic fixation results from a tertiary referral clinic Halit Eren Erdem
11.40-11.45	Result of 140 cases of IOL implantation with Yamane technique combined with PPV Gianluca Besozzi
11.45-11.50	A Novel Modified Flapless surgical Technique for sutureless scleral fixation of FIL SSF intraocular lens: a retrospective case series Danilo Iannetta
11.50-11.55	Carlevale scleral fixated IOL. the ultimate solution Stratos Gotzaridis
11.55-12.00	Discussion
12.00-12.15	Debate Moderator: Gianluca Besozzi
12.00-12.10	Iris fixation - Matteo Forlini vs Scleral fixation - Tansu Erakgün
12.10-12.15	Votes
12.15-12.30	Debate Moderator: Danilo Iannetta
12.15-12.25	For secondary IOL implantation scleral fixation carlevale style - Carlo Carlevale vs Scleral fixated IOL - Shin Yamane
12.25-12.30	Votes

SEPTEMBER 1ST, 2023 • FRIDAY

HALL 1

12.30-13.30 General Assembly and Election

12.30-14.00  Lunch

14.00-15.05 Innovations on Surgical Instrumentation / Artificial Intelligence

Moderators: **Levent Akduman, Linda Lam**

14.00-14.05 Developing an artificial intelligence model to detect epiretinal membranes in OCT by using a machine learning platform without typing code

Hakan Baybora

14.05-14.10 Digital Ophthalmology: Role of Augmented and Virtual Reality?

Linda Lam

14.10-14.15 A novel mobile application for communication between parents, pediatricians and ophthalmologists for retinopathy of prematurity screening providing artificial intelligence assisted retinopathy of prematurity diagnosis

Ayşe İpek Akyüz Ünsal14.15-14.20 The use of artificial intelligence in the retina; Where and how? - **Özlem Candan**

14.20-14.25 Tips in dealing with surgical challenges of myopic macular holes with AXL more than 32 mm

Khalid Sabti

14.25-14.30 Discussion

14.30-14.35 Comparative study of commonly used intraocular forceps

Mahmut Doğramacı

14.35-14.40 Application of single-molecule localization microscopy in ophthalmology

Hyun Seung Yang

14.40-14.45 Impact of three-dimensional heads-up display on ergonomics, surgical performance and teaching in vitreoRetinal surgery in a tertiary eye care center

Yassine Malek

14.45-14.50 Modified MACULAR BUCKLE, the ultimate solution

Muhammad Samir Alhadad

14.50-14.55 Myopia support device (Titanium Macular Buckle): Outcomes of the first three cases

Levent Akduman

14.55-15.00 MTM-Stop device: Outcomes of the first 15 years of study on macula buckling

Barbara Parolini

15.00-15.05 Discussion

15.05-15.40 Panel by EGVRs: Challenging Situations in Vitreoretinal Surgery

Moderator: **Hany Hamza, Hassan Mortada**

15.05-15.10 Retinal Detachment Associated with Choroidal Coloboma: Insights from

Hassan Mortada

15.10-15.15 A novel Device for Extra Large Intraocular Foreign Bodies: Samir Elbaha's Perspective

Samir El Baha

15.15-15.20 Managing Challenging Diabetic Tractional Retinal Detachment: Evaluating the Adequacy of Unimanual Probe Vitrectomy

Mohammad Moghazy

15.20-15.25 Retinal Detachment Following Ozurdex Injection for Uveitis: Exploring the Case

Hassan Mortada

15.25-15.30 Iatrogenic Pneumomacular Hole: Analyzing the Incident and Lessons Learned

Hany Hamza

15.30-15.35 Macular Fold following Vitrectomy: Etiology and Management Strategies Explored

Samir El Baha

15.35-15.40 Discussion

SEPTEMBER 1ST, 2023 • FRIDAY

HALL 1

DETAILED PROGRAM

15.40-16.05	Panel by ASRS: Advances in Retina Moderators: Linda Lam, Giampaolo Gini
15.40-15.45	Monitoring nAMD with AI-enabled home OCT Judy Kim
15.45-15.50	Reduce the surgical time by not completely draining the subretinal fluid in retinal detachment cases Stratos Gotzaridis
15.50-15.55	Rhegmatogenous RD in uveitis: Do's and Don'ts Sofia Androudi
15.55-16.00	Management of macular folds Giampaolo Gini
16.00-16.05	Discussion
16.05-16.30	☕ Coffee Break
16.30-17.00	EVRS Lecture Moderators: Giampaolo Gini, Barbara Parolini Giovanni Staurenghi
17.00-17.25	Challenging Cases of Medical Retina Moderators: Bora Eldem, Sibel Kadayıfçılar
17.00-17.05	Different clinical entity findings of patients with polypoidal choroidal vasculopathy Yasin Şakir Göker
17.05-17.10	Early detection and treatment of sympathetic ophthalmia Perfecto Elpidio Octavio Roy Cagampang III
17.10-17.15	Case report of Post-typhoid neuroretinitis: A rare cause of visual morbidity Perfecto Elpidio Octavio Roy Cagampang III
17.15-17.20	Atypical central serous chorioretinopathy in adolescents using oral contraceptives Şevval Efe
17.20-17.25	Discussion
17.25-18.00	Panel: Challenging Cases of VRS Moderators: Hussain Khaqan, Ashraf Shaarawy Tural Galbinur Retinal detachment associated with AIDS related cytomegalovirus retinitis Management of complicated retinal detachment with temporary keratoprosthesis Rachid Tahiri 1. Retinal Inversion in aphakic patient 2. Use of intraoperative oct in prefoveal and retrofoveal hemorrhage Tatyana Avanesova 1. Management of long-standing Rd with intra retinal cyst 2. Case of subretinal hemorrhage Hussain Khaqan 1. Three IOL one eye , Choroidal Detachment ,How to proceed? 2. Silicone Band intrusion , Nightmare 3. Failed macular Hole Surgery , What Next? Marcello Casellas We have retinal fold,What to do now? Use of cosine law to choose the correct forcep shaft length for macular surgery in high myopes. Muhammad Samir Alhadad GRT, How to manage Discussion

SEPTEMBER 1ST, 2023 • FRIDAY

HALL 1

18.00-18.30 **EVRS My Worst & More Threatening Video: What to do and Not to do**Moderator: **Mario Romano**

Pole to pole and more

Susana Cura

Two IOLs dropped in Vitreous Chamber

Matteo Forlini

Post RD PVR peeling – Haemorrhage

Stratos Gotzaridis

Fluid air exchange ... in the wrong site

Danilo Iannetta20.00  **GALA DINNER @ Kaya Hotel**

HALL 2

08.00-09.00 **Course: Principles, Pitfalls and Artifacts in OCT and OCTA**Moderator: **Ali Erginay**Instructors: **Ali Erginay, Şengül Özdek, Figen Şermet**

Course will focus on:

- Principle of OCT and OCTA
- Imaging modalities, advantages and disadvantages
- Which imaging protocols for which pathologies
- Artifacts and pitfalls
- Interpretation errors
- Use of multimodal Imaging for better diagnosis

09.30-11.00 **Course: ROP**Moderator: **Şengül Özdek, Anna Ells**

Introduction

Şengül Özdek

ICROP 3 update

Anna Ells

Anti-VEGF treatment for ROP and its systemic side effects

Wei Chi Wu

Long term sequelae of ROP as a lifelong disease

Susana Teixeira

Laser treatment for ROP and long term consequences of exudative RD after laser for ROP

Michael Blair

Stage 4a ROP : Surgical treatment

Çağrı Beşirli

Update on surgery for Stage 5 ROP

Antonio Capone Jr.

Discussion

SEPTEMBER 1ST, 2023 • FRIDAY

HALL 2

DETAILED PROGRAM

11.10-11.50

Rapid Fire Talks on UveitisModerators: **Perfecto Elpidio Octavio Roy Cagampang III, Sibel Demirel**

Combined ocular signs leading to a diagnosis of rare systemic disease: Bilateral Angioid Streaks with Optic Nerve Head Drusen and abnormal retinal haemorrhage in a case of Pseudoxanthoma Elasticum (PXE)

Mahjabeen Choudhury

CNVM in vogt koyanagi harada disease

Kshitij Raizada

To report three cases of unilateral Eales disease with presumed tubercular etiology and management, including a combination of oral steroids plus antituberculosis (anti-TB) therapy. Methods: The clinical, serological, tuberculin skin test, a

Omer Othman Abdullah

Peripapillary and macular choroidal vascularity index in migraine patients during acute attacks

Dilara Özkoyuncu Kocabaş

Sympathetic Ophthalmia: Three years

Perfecto Elpidio Octavio Roy Cagampang III

Posterior segment parameters after uveitic cataract surgery: a prospective study with 1-year results

Nur Doğanay Kumcu

Discussions

13.30-14.30

Rapid Fire Talks on Macular HolesModerators: **Hany Hamza, Fevzi Şentürk**

When the macula acts tough

Pooja Sinha

Combined ILM flap under perfluorocarbon liquid and laser ablation for optic disc pit maculopathy: technique and rationale

Wael Ahmed Ewais

Optical coherence tomography angiography changes after surgery for optic disc pit maculopathy: a case series and literature review

Muhammet Kazım Erol

Lamellar macular holes: Which ones to touch

Hany Hamza

Discussions

Microperimetric findings could explain subjective visual complaints in patients, whose vision improved to 20/20 (logMAR 0) after macular hole surgery

Fevzi Şentürk

Evaluation of retinal microvascular differences after successful macular hole surgery with superior inverted flap technique or temporal inverted flap technique

Utku Limon

Superior inverted internal limiting membrane flap technique in idiopathic macular hole surgery

Emre Avcı

Discussions

14.40-15.30

Course: TraumaModerator: **Giampaolo Gini**

Timing in Ocular Trauma Surgery

Giampaolo Gini

Complex Retina Surgery in Open Globe Injuries

Faisal Fayyad

Anterior Segment Reconstruction in Severe Trauma

Matteo Forlini

SEPTEMBER 1ST, 2023 • FRIDAY

HALL 2

15.30-16.00	Rapid Fire Talks on Trauma Moderators: Nilüfer Koçak, Mohammed Tawfik
	Full thickness corneal patch graft outcomes in traumatic or spontaneous corneal perforation - Sibel Ahmet
	Giant Macular Hole in complex Trauma
	Wael Ahmed Ewais
	The clinic outcome of open ophthalmic injuries in western of turkey
	Erdoğan Aydın
	The epidemiology of open globe injuries: A ten-year retrospective analysis at a tertiary care center in Istanbul, Turkey
	Nursel Melda Yenerel
	Large retinal hole following injury by q-switched nd:yag laser
	Kshitij Raizada
	Discussions
16.00-17.00	Rapid Fire Talks on ROP Moderators: Susana Teixeira, Ayşe İpek Akyüz Ünsal
	Clinical and demographic characteristics of treatment requiring retinopathy of prematurity (ROP) in big premature infants in turkey - big-rop study report no:1
	Hüseyin Baran Özdemir
	ROP multiple injections, when to stop?
	Sara Ahmed Tawfik
	Optometrist based screening for retinopathy of prematurity - a validation study using portable wide-field paediatric imaging system - Vishal Govindahari
	Discussions
	The effect of retinopathy of prematurity on corneal topography and corneal endothelial function parameters - Sibel Yavuz
	Do we need to screen very big babies for retinopathy of prematurity?
	Ayşe İpek Akyüz Ünsal
	ROP Screening & Imaging modalities...our way - Ahmed Mansour
	Coats Disease: The whole spectrum - Ihab Saad Othman
	Discussions
17.00-18.00	Course: Breaking the Retinal Barrier: Journey to the Subretina and Choroid Moderator: Jayanto Guha
	Chorio-retinectomy - Sangeet Mittal
	Choroidal detachments and choroidal drainage techniques - Nishikant Jaywant Borse
	Sub-retinal PVR - Jayanto Guha
	Restoring traumatic choroidal ruptures/ tears with choroidal detachments
	Gökhan Gürel
	Management of submacular haemorrhage - small to large
	Agnieszka Nowosielska
	Supra-choroidal haemorrhage - causes, prevention and management
	Sangeet Mittal
	Management of old massive sub-macular haemorrhage with autologous RPE choroid transplant - Barbara Parolini
	Choroidal tumor surgery - Hany Hamza
20.00	 GALA DINNER @ Kaya Hotel

SEPTEMBER 2ND, 2023 • SATURDAY

HALL 1

08.00-09.00	ROP Moderators: Michael Blair, Anna Ells
08.00-08.05	Smartphone application links severity of retinopathy of prematurity to early motor behavior in a cohort of high-risk preterm infants - Michael Blair
08.05-08.10	Refractive evaluation of prophylactic laser treatment for persistent avascular retina in eyes treated with primary intravitreal bevacizumab Nihat Sayin
08.10-08.15	ROP stage 5 different strategies- Muhammad Samir Alhadad
08.15-08.20	The emergence of AROP in Bangladesh: A report on the prevalence, treatment and visual outcome of ROP from January 2021- September 2022 in a tertiary hospital in Bangladesh Mahjabeen Choudhury
08.20-08.25	Discussion
08.25-08.30	ROP surgery in older children: Can you help? - Ihab Saad Othman
08.30-08.35	Pulmonary function in school-age children following intravitreal injection of bevacizumab for retinopathy of prematurity - Wei Chi Wu
08.35-08.40	The war on retinopathy of prematurity: Where are we now? - Lalit Agarwal
08.40-08.45	Five year follow-up results of retinopathy of prematurity cases treated by laser or injection Semra Acer
08.45-08.50	ROP behind the scene imaging ! - Sara Ahmed Tawfik
08.50-09.00	Discussion
09.00-09.15	Debate
	Persistent Peripheral Avascular Retina in ROP:
09.00-09.10	To treat - Michael Blair vs Not to treat Susanna Teixeira
09.10-09.15	Votes
09.15-10.35	Updates on Pediatric Vitreoretinal Surgery Moderators: Antonio Capone Jr., Şengül Özdek
09.15-09.20	Wnt retinopathies - Antonio Capone Jr.
09.20-09.25	Anti-VEGF drugs for pediatric retinal diseases? - Anna Ells
09.25-09.30	Importance of FFA in ROP - Susana Teixeira
09.30-09.35	Surgical management of adult ROP complications - Çağrı Beşirli
09.35-09.40	Laser prophylaxis in stickler syndrome - Michael Blair
09.40-09.45	Discussion
09.45-09.50	The Long-term surgical outcomes of patients with posterior and combined PFV Wei Chi Wu
09.50-09.55	Severe anterior persistent fetal vasculature: the role of anterior retinal elongation on prognosis - Şengül Özdek
09.55-10.00	Surgical outcomes of posterior persistent fetal vasculature syndrome: Cases with Tent-Shaped and closed Funnel-Shaped retinal detachment - Ece Özdemir
10.00-10.05	Discussion
10.05-10.10	Subfoveal nodule in coats' Disease: Stages, prognosis, and treatment - Şengül Özdek
10.10-10.15	Complex syndromic pediatric rhegmatogenous retinal detachment: Surgical technique & outcome - Hassan Mortada
10.15-10.20	Development of cataract following Lens-Sparing vitrectomy in pediatric eyes - Merve Oral
10.20-10.25	Congenital X-Linked Retinoschisis: Surgical needs and outcomes in long term a retrospective multicenter international study - Hüseyin Baran Özdemir
10.25-10.30	Long-term surgical outcomes of pediatric retinal detachment associated with congenital glaucoma - Merve Özbek
10.30-10.35	Discussion

SEPTEMBER 2ND, 2023 • SATURDAY

HALL 1

10.35-11.00	Zivojnovic Award and Lecture
	Introduction by Şengül Özdek
	The Philosophy of Pediatric Vitreoretinal Surgery - Antonio Capone Jr.
11.00-11.30	 Coffee Break
11.30-11.55	Ocular Oncology Moderators: Ihab Saad Othman, Martina Angi
11.30-11.35	Strawberry eyes: A case of multiple bilateral orbital masses in an infant Josemaria Castro
11.35-11.40	Biopsy for choroidal and retinal tumors: why and how ! - Hany Hamza
11.40-11.45	Update on surgical management of complex retinal detachment associated with retinal capillary hemangioblastoma in Von Hippel-Lindau disease - Remzi Avci
11.45-11.50	Mystery of the mass- Choroidal granuloma as the presenting sign of disseminated tuberculosis - Monisha Apte
11.50-11.55	Discussion
11.55-12.30	Panel on Ocular Oncology Moderators: Murat Hasanreisioğlu, Tuba Atalay Mystery case
11:55-12:00	Pukhraj Rishi
12:00-12:05	Tuba Atalay
12:05-12:10	Martina Angi
12:10-12:15	Murat Hasanreisioğlu
12:15-12:20	Ihab Saad Othman
12:20-12:30	Discussion
12:30-13.00	Satellite Symposium
	 Faricimab "Power of Two": Advancing the management of nAMD and DME via Ang-2/VEGF-A dual inhibition - Bora Eldem, Figen Şermet
13.00-13.40	 Lunch
13:40-14.25	Update on Retinal Detachment (Risk, PNR, Buckle, Laser) Moderators: Rajeev Muni, Mariano Irós
13:40-13.45	In vivo generated autologous plasmin (IVAP) assisted vitrectomy, oral retinotomy, silicone oil injection for the treatment of chronic retinal detachment - Cengiz Aras
13:45-13.50	Reattachment rate with pneumatic retinopexy for rhegmatogenous retinal detachment with a single break in detached retina - Aurora Pecaku
13:50-13.55	The implementation of pneumatic retinopexy in the Japanese population Kunihiko Akiyama
13:55-14.00	Chandelier-Assisted Scleral Buckling with Illuminated Endolaser Retinopexy Nur Acar Göçgil
14:00-14.05	Discussion
14:05-14.10	Bacillary layer detachment in the pathophysiology of secondary macular hole in fovea-off rhegmatogenous retinal detachment - Rajeev Muni
14:10-14.15	High-frequency electric current welding with suprachoroidal approach to treat retinal detachment: timing of morphological changes and strength of chorioretinal adhesion Andrii Sergiienko
14:15-14.20	Direct laser photocoagulation of the Retinal pigment epithelium: A novel method to seal retinal breaks during pars plana vitrectomy for retinal detachment - Du Shu
14:20-14.25	Discussion

SEPTEMBER 2ND, 2023 • SATURDAY

HALL 1

DETAILED PROGRAM

14.25-15.30	Update on Retinal Detachment (PPV) Moderators: Stratos Gotzaridis, Khalid Sabti
14.25-14.30	Results of peripheral vitrectomy under air in rhegmatogenous retinal detachment Tuğrul Altan
14.30-14.35	Primary pars plana vitrectomy with silicone oil tamponade for rhegmatogenous retinal detachment Mehmet Orkun Şevik
14.35-14.40	Comparison of macular slippage rates in patients with primary rhegmatogenous retinal detachment undergoing pars plana vitrectomy with silicone-oil or perfluoropropane gas tamponade Sadık Altan Özal
14.40-14.45	Lyophilized amniotic membrane for Rhegmatogenous retinal detachment treatment Sergio Rojas Juárez
14.45-14.50	A novel technique of subretinal fluid drainage in eyes with rhegmatogenous retinal detachment Ziya Kapran
14.50-14.55	Discussion
14.55-15.00	Outcomes of “minimal drainage” vitrectomy for retinal detachment repair Ahmed Sallam
15.00-15.05	The impact of short-term postoperative face-up position on unintentional retinal displacement after pars plana vitrectomy for rhegmatogenous retinal detachment Mariano Irós
15.05-15.10	Photoreceptor integrity following pars plana vitrectomy for primary rhegmatogenous retinal detachment Muzaffer Şahin
15.10-15.15	PVR game Samir El Baha
15.15-15.20	Surgical technique for closed funnel retinal detachment repair Ahmed Mohamed Habib
15.20-15.30	Discussion
15.30-15.45	Debate Moderator: Gürsel Yılmaz
15.30-15.40	RD: Rajeev Muni for PnR vs Remzi Avcı for PPV
15.40-15.45	Votes
15.45-16.15	☕ Coffee Break
16.15-16.45	Panel by GIVRE: VR Surgery - Surgical Management Techniques of ILM in FTMH: Videos Session Moderator: Mario Romano
	Flower petals inverted flap cover technique Danilo Iannetta
	Hemicircular ILM peeling with temporal inverted flap Tomaso Caporossi
	Inverted ILM flap technique for secondary MH coexistent recurrent RD Rodolfo Mastropasqua
	Visco-assisted free ILM-flap Mario Romano
	Treatment of myopic persistent macular hole Barbara Parolini
	Discussion

SEPTEMBER 2ND, 2023 • SATURDAY

HALL 1

16.45-17.45	Challenging Cases of Surgical Retina Moderators: Faisal Fayyad, Tansu Erakgün
16.45-16.50	Anatomical and functional outcomes of vitrectomy with silicone punctal plug for optic disc pit and associated serous macular detachment Hussain Khaqan
16.50-16.55	Outcomes of pars plana vitrectomy for retinal detachment with chorioretinal coloboma Murat Arıcı
16.55-17.00	A mysterious case of retinal detachment- is it really rhegmatogenous? Katarzyna Chwiejczak
17.00-17.05	Repair with two ILM flaps in a patient with optic disc pit maculopathy who developed a full-thickness macular hole at the first surgery Semra Tiryaki Demir
17.05-17.10	Discussion
17.10-17.15	Free ILM flap for retinal detachment secondary to juxta-papillary holes in peripapillary staphylomas Sangeet Mittal
17.15-17.20	Early results of autologous retinal pigment epithelium-choroid transplantation for the treatment of eyes with subretinal disciform scar formation Eyyup Karahan
17.20-17.25	Surgical results of Vitrectomy for Central Retinal Artery Occlusion Nishikant Jaywant Borse
17.25-17.30	Hungry eyes! Management of live intravitreal cysticercus cyst with retinal detachment Saurabh Luthra
17.30-17.35	Internal limiting membrane (ILM) surgery for myopic traction maculopathy (MTM): Should macular buckle be abandoned ? Hassan Mortada
17.35-17.45	Discussion
17.45-18.45	Course: Pneumatic Retinopexy Moderator: Rajeev Muni
	PIVOT Trial Results - Kunihiko Akiyama
	Integrity in Retinal Detachment Repair - Rajeev Muni
	Pneumatic Retinopexy Basic Technique - Rajeev Muni
	Pneumatic Retinopexy Complications - Kunihiko Akiyama
	Pneumatic Retinopexy Cases: Standard and Extended Criteria - Kunihiko Akiyama, Rajeev Muni
	Extreme Pneumatics - Rajeev Muni
	How to Integrate PnR into your Practice - Kunihiko Akiyama, Rajeev Muni
20.00	 FAREWELL PARTY @ Guray Museum*

SEPTEMBER 2ND, 2023 • SATURDAY

HALL 2

08.00-09.00	Course: PVR Moderator: Nur Acar Göçgil Introduction; Surgical Management of PVR-Pearls and Tricks - Nur Acar Göçgil Pearls for the Management of PVR - Hassan Mortada Surgical Treatment of and Pharmacological Adjuvant Therapy with Intravitreal Methotrexate for PVR - Özgür Artunay Intraoperative Adjuvant Therapy in the Treatment of PVR - Gökhan Gürelik
09.00-10.00	Course: Management of Complex RRD and its Complications Moderator: Hussain Khaqan Trocar Gauges, Types, Endo light, Viewing Systems, Cutter, Endotamponade Tural Galbinur Case management of Complex Retinal Detachment, video based case presentations Tatyana Avanesova Video based techniques, Retinectomy, PVR peel, Buckle plus Vitrectomy Hussain Khaqan Management of redetachment Muhammad Samir Alhadad
10.00-11.00	Course: Social Media Strategies for Ophthalmologists Moderator: Mohammed Tawfik How to do your personal brand - Mohammed Tawfik Social Media for Unsocial - Ahmed Habib Branding Teaching and Research - Ahmed Salam
11.00-11.30	☕ Coffee Break
10.30-12.30	Course: Macular Buckle Moderator: Barbara Parolini Lecturers: Levent Akduman, Ahmed Bedda, Emanuele Crincoli, Jaime Francisco Rosales Padrón Introduction to the course - Barbara Parolini History of macular buckle - Emanuele Crincoli Indications: MTM staging system Explanations and interactive time - Emanuele Crincoli Experience of real-life users in Egypt: indications, results, complications and comparison with cases treated only with vitrectomy Ahmed Magdy Bedda Experience of real-life users in USA: indications, results, complications and comparison with cases treated only with vitrectomy Levent Akduman Experience of real-life users in Italy: indications, results, complications and comparison with cases treated only with vitrectomy Barbara Parolini Is there progression of atrophy after macular buckle? Long term result in a large case series Jaime Francisco Rosales Padrón Wetlab and Q&A interacting with the speakers - Demonstration of the use of buckle
12:30-13.00	Satellite Symposium  Faricimab “Power of Two”: Advancing the management of nAMD and DME via Ang-2/ VEGF-A dual inhibition - Bora Eldem, Figen Şermet
13.00-13.40	🍽 Lunch

SEPTEMBER 2ND, 2023 • SATURDAY

HALL 2

13.40-14.40 Rapid Fire Talks on Surgery

Moderators: **Wael Ahmed Ewais, Mahmut Doğramacı**Comparison of 27-gauge unimanual and 25-gauge bimanual vitrectomy outcomes of tractional retinal detachment in diabetic patients - **Yusuf Cem Yılmaz**Retinal Push Technique during vitrectomy for primary retinal detachment in children
Wael Ahmed EwaisTo drain or not to drain - **Mahmood Othman Mekkawy**Method for vitreous body microsurgical anatomy studying - **Natalia Kislitsyna**Vitrectomy for silicone band intrusion in vitreous cavity - **Hussain Khaqan**

Discussions

Evaluation of the effects of silicone oil and C3F8 gas tamponade with pattern-multifocal electroretinography in patients with rhegmatogenous retinal detachment

Murat KarapapakChanges in the Schlemm's canal microarchitecture after silicone oil removal in retinal detachment - **Gülay Yalçinkaya Çakır**Gonioscopic and anterior segment optical coherence tomographic findings after low viscosity silicon oil removal - **Çiğdem Bengi Güngör**Experimental laboratory modelling of choroidal vasculature: a study of the dynamics of intraoperative choroidal hemorrhage during pars plana vitrectomy - **Mahmut Doğramacı**Cystic Retinal Detachment - **Fathi Omar Zenbil**

Discussions

14.40-15.40 Rapid Fire Talks on Diabetes

Moderators: **Ahmed Mansour, Pukhraj Rishi**

The effect of dexamethasone implant application on the morphological and vascular structure of the choroid in diabetic macular edema with inflammatory biomarkers

Cemal Özsaygılı

Comparative analysis of OCTA and ultra-wide field angiography in cases of branch retinal vein occlusion

Muhammed Altınışık

Investigation of choroidal vascularity changes after dexamethasone treatment in diabetic macular edema

Murat Arıcı

Relation of optical coherence tomography biomarkers and visual function in diabetic epiretinal membrane

Güner Üney

Discussions

Vascular Occlusion in young patients - **Kshitij Raizada**Comparison of aflibercept and bevacizumab analyzing central macular thickness on optical coherent tomography and best corrected visual acuity in patients with diabetic macular edema - **Amila Alikadic Husovic**Changes in the density of the vitreous body in patients with diabetic vitreopapillary traction syndrome - **Dilara Babaeva**Examining the correlation of lymphangiogenesis biomarkers with clinical condition in age-related macular degeneration (AMD) - **Bağım Ayçin Çakır İnce**


Discussions

15.45-16.15

☕ Coffee Break

SEPTEMBER 2ND, 2023 • SATURDAY

HALL 2

16.45-17.45	Young EVRS Session Moderators: Matteo Forlini, Emanuele Crincoli
16.45-16.50	Myopic macular hole-related retinal detachment in children Hüseyin Baran Ozdemir
16.50-16.55	Unexpected complication following temporal inverted ILM flap technique for macular hole Aysegül Mavi Yıldız
16.55-17.00	The importance of structural OCT in the assessment of patients with central serous chorioretinopathy Enrico Borrelli
17.00-17.05	Lens sparing surgery for retrolental stalk in persistent fetal vasculature Youssef Abdelmassih
17.05-17.10	Is it true that macular buckle induces atrophy? A Long term review and comparison with natural history Jaime Francisco Rosales Padrón
17.10-17.15	Phenomenology of spontaneous closure in degenerative and mixed type lamellar macular hole Fiammetta Catania
17.15-17.20	N-Glycosylation Patterns across the Age-Related Macular Degeneration Spectrum Ivona Bucana
17.20-17.45	Discussion
20.00	 FAREWELL PARTY @ Guray Museum*

SEPTEMBER 3RD, 2023 • SUNDAY

HALL 1

DETAILED PROGRAM

08.00-08.30 Panel by APVRS: Updates on DME / Vein OcclusionsModerator: **Adrian Koh**08.00-08.05 The roles of recently approved medications for the treatment of DME - **Adrian Koh**08.05-08.10 The current clinical practice for the treatment of DME - **Angie Fong**08.10-08.15 Novel optical coherence tomography angiography biomarker in branch retinal vein occlusion macular edema - **Wei-Chi Wu**08.15-08.20 The current clinical practice for the treatment of ME secondary to RVO - **Marten Brelen**

08.20-08.30 Discussion

08.30-09.00 Subthreshold LaserModerator: **Barbara Parolini**08.30-08.35 Micropulse laser for the treatment of subretinal fluid - **Barbara Parolini**08.35-08.40 Micropulse subthreshold yellow laser in the treatment of central macular edema in central serous chorioretinopathy - **Mladen Zoran Brzakovic**08.40-08.45 5-year prospective RCT comparing micropulse with 1/2dose PDT - **Marten Brelen**08.45-08.50 Central Serous ChorioRetinopathy treated with subthreshold 3 ns laser: A retrospective case series - **Wilson Heriott**08.50-08.55 Subthreshold stimulation laser in central serous chorioretinopathy - **Ivan Fišer**

08.55-09.00 Discussion

09.00-09.40 Updates on Retinal Vascular DiseasesModerators: **Ivan Fišer, Vladimir Poposki**09.00-09.05 CME: Traditional approaches still work - **Ivan Fišer**09.05-09.10 Evaluation of bioclinical markers to predict short term response to intravitreal anti-VEGF in treatment-naïve diabetic macular edema and the "Fried Egg" sign: a novel OCT feature **Indu Govindaraj**09.10-09.15 Long-term outcomes of intravitreal dexamethasone implant for the treatment of macular edema following surgical removal of epiretinal membranes - **Ali Altan Ertan Boz**

09.15-09.20 Discussion

09.20-09.25 Does epiretinal membrane affect diabetic macular edema treatment results? **Büşra Güner Sönmezoğlu**09.23-09.30 Foveal sparing ILM peeling in the treatment of the tractional diabetic macular edema **Bernardete Bela Pessoa**09.30-09.35 Psychophysical changes due to visual loss in diabetic patients - **Vladimir Poposki**

09.35-09.40 Discussion

09.40-10.20 AMD and Medical RetinaModerators: **Judy Kim, Daniela Bacherini**09.40-09.45 The impact of OCT double layer sign characteristics on long-term visual prognosis of patients with non-exudative age related macular degeneration - **Ayşegül Mavi Yıldız**09.45-09.50 Future of anti-VEGF- Biosimilars and biobetters - **Dhanashree Ratra**09.50-09.55 Effect of vitreomacular traction on the intraocular vascular endothelial growth factor and placental growth factor levels in patients with neovascular age-related macular degeneration - **Tugçe Horozoğlu Ceran**09.55-10.00 Prognostic impact of the vitreomacular interface in the treatment of neovascular age-related macular degeneration - **Püren Işık**10.00-10.05 High dose aflibercept treatment in naïve neovascular age-related macular degeneration: A real life data - **Seren Mert Pehlivanoglu**10.05-10.10 Long-term retinal pigment epithelium detachment and drusen changes in eyes with non-neovascular aged related macular degeneration - **Aylin Karalezli**

10.10-10.20 Discussion


SEPTEMBER 3RD, 2023 • SUNDAY


HALL 1

10.20-10.35	Debate Moderator: Adrian Koh
10.20-10.30	Deveraj Supramaniam for biosimilars vs Figen Şermet for original molecules
10.30-10.35	Votes
10.35-11.00	Coffee Break
11.00-11.30	Panel by Turkish Ophthalmological Association: OCTA is a Must Moderator: Sema Oruç Dündar
11.00-11.05	CSR-Pachychoroid disease Sibel Demirel
11.05-11.10	Exudative MNV Nurten Ünlü
11.10-11.15	Inflammatory MNV Sibel Kadayıfçılar
11.15-11.20	Myopic MNV Selçuk Sızmaz
11.20-11.25	Nonexudative MNV Figen Şermet
11.25-11.30	Discussion
11.30-12.25	Updates on Imaging Moderators: Mehmet Numan Alp, Ali Erginay
11.30-11.35	Evaluation of retinal microvascular structures changes by optical coherence tomography angiography in rheumatoid arthritis using hydroxychloroquine Ayna Sariyeva Ismayilov
11.35-11.40	Oral fluorescein angiography using broadline imaging technology for retinal disease Sangeet Mittal
11.40-11.45	Comparing the effects of silicone-oil and perfluoropropane gas tamponade on macular microcirculation in rhegmatogenous retinal detachment treated with vitrectomy: an optical coherence tomography angiography study Ece Özal
11.45-11.50	Correlation of the clinical findings with the extend of deep vascular plexus changes in patients with macular telangiectasia type 2: An OCTA study Özge Yanık Odabaş
11.50-11.55	Discussion
11.55-12.00	The place of a new Wide-Field swept source optical coherence tomography angiography canon xephilio in retinal diseases Ali Erginay
12.00-12.05	Prominent henle fiber layer in optical coherence tomography Pınar Kaya
12.05-12.10	Long Term OCT changes after treatment in chronic CSCR Figen Bezci Aygün
12.10-12.15	The role of Peripheral retinal OCT in vitreoretinal disorders Daniela Bacherini
12.15-12.20	Peripheral and central retinal vascular changes in asymptomatic family members of patients with familial exudative vitreoretinopathy Atike Burçin Tefon Arıbaş
12.20-12.25	Discussion

SEPTEMBER 3RD, 2023 • SUNDAY

HALL 1

12.25-14.00	Updates on Uveal Diseases & Endophthalmitis Moderators: Ahmed Sallam, Süleyman Kaynak
12.25-12.30	Adjunctive intravitreal anti-VEGF and moxifloxacin therapy in the management of intraocular tubercular granulomas Manisha Agarwal
12.30-12.35	Clinical presentation and outcome of patients with endogenous endophthalmitis: A case series Şerife Çiloğlu Hayat
12.35-12.40	Retrospective analysis of characteristics and visual outcomes of patients with endogenous endophthalmitis - Furkan Çam
12.40-12.45	Posterior segment ocular findings in critically ill patients with COVID-19 Rosa Maria Romero Castro
12.45-12.50	Discussion
12.50-12.55	OCT/OCTA biomarkers in uveitis Omer Othman Abdullah
12.55-13.00	Choroidal vascularity index and iris thickness in bilateral acute iris transillumination Pinar Kaya
13.00-13.05	Posterior vitreous attachment as a risk factor for endophthalmitis following intravitreal antivascular endothelial growth factor injection Durgul Acan
13.05-13.10	Visual and clinical outcomes of pars plana vitrectomy in patients with uveitis Berru Yargı Özkoçak
13.10-13.15	Discussion
13.15-13.20	Silicone Oil in the Surgical Management of Endophthalmitis Murat Öncel
13.20-13.25	Decoding the enigma of Serpiginous Choroiditis Kshitij Raizada
13.25-13.30	Retrospective evaluation of neuroretinitis cases in a tertiary care clinic Meryem Feyza Çiçek
13.30-13.40	Discussion
14.00-14.15	CLOSING CEREMONY
14.15-15.00	 Lunch

SEPTEMBER 3 RD , 2023 • SUNDAY	
HALL 2	
09.00-09.30	EVRS Retina Premier League Moderators: Sangeet Mittal, Giampaolo Gini TEAM RETINA RANGERS Barbara Parolini, Nishikant Jaywant Borse, Maged Mikhael Gergess, Neeraj Sanduja, Jayanto Guha, Susana Teixeira TEAM VITREOUS WIZARDS Eleonara Beatriz Lavaque, Prashant Bawankule, Manisha Agarwal, Hussain Khaqan, Şengül Özdek, Saurabh Luthra
10.00-11.00	Course: Ocular Oncology for Retina Specialists Moderator: Murat Hasanreisioğlu
10:00-10:10	Intraocular metastatic lesions Martina Angi
10:10-10:20	Is it genuine or pseudo? Tuba Atalay
10:20-10:30	The Great Masquerade Pukhraj Rishi
10:30-10:40	Uveal Pigmented Lesions; Beauty or the Beast? Murat Hasanreisioğlu
10:40-10:50	Intraocular tumors in opaque ocular media Ihab Saad Othman
10:50-11:00	Discussion
11.10-12.10	Course: Diabetic Vitrectomy Moderator: Hassan Mortada Management of Diabetic traction RD Samir El Baha Management of combined traction/rhegmatogenous RD Tansu Erakgün Diabetic Vitreomacular interface disorders Hassan Mortada Postoperative recurrent RD Hassan Mortada Discussion
14.00-14.15	CLOSING CEREMONY
14.15-15.00	 Lunch

ORAL PRESENTATIONS

[Abstract:0089]**Evaluation of retinal microvascular structures changes by optical coherence tomography angiography in rheumatoid arthritis using hydroxychloroquine**Ayna Sariyeva Ismayilov¹, Aynura Sariyeva Aydamirov²¹Bursa Yüksek İhtisas Training and Research Hospital, Bursa, Türkiye²Alanya Alahattin Keykubat University Training and Research Hospital, Antalya, Türkiye

Purpose: To evaluate retinal microvascular structure changes in patients with rheumatoid arthritis (RA) using hydroxychloroquine (HCQ) by optical coherent tomography angiography (OCTA).

Methods: In this cross-sectional study 67 eyes of RA patients and 36 eyes of healthy controls were evaluated. The vascular structures of RA patients using short (<5 years) (n=34), and long-term (>5 years) (n=33) HCQ without retinopathy were evaluated with OCTA. Vessel density (VD) (%) in superficial (SCP) and deep capillary plexus (DCP), flow area of outer retina (mm²), flow area of choriocapillaris (mm²) and foveal avascular zone (FAZ) were compared with healthy controls.

Results: The mean VD in SCPlayer parafovea-temporal region was significantly lower than healthy controls (p=0.042) and patients using HCQ >5 years (p=0.041). There was found a significantly reduced VD in DCP layer whole retina, superior-hemi, fovea, parafovea-superior-hemi, parafovea-inferior-hemi, parafovea-temporal, parafovea-nasal, parafovea-inferior regions in the using HQ <5 years compared with healthy controls and using HQ>5 years. There was a significantly decreased FAZ in the using HQ <5years group (control and HCQ<5years p=0.004; HCQ<5years and HCQ>5years p=0.045). FAZ values of the control group and using HCQ >5 years group were similar (p=0.598). It was found positive correlation between VD in DCP layer whole (%) region and daily dose (mg/day) (r=0.297, p=0.043). There was positive correlation between VD in DCP layer whole (%) region and cumulative dose (g) (r=0.406, p=0.009).

Conclusion: While VD in SCP layer parafovea-temporal region and VD in DCP layers reduced in patients using HCQ < 5 years, it was found similar in control group and patients using HCQ >5 years. Long-term use of HCQ may have a protective effect on retinal vascular structures in RA. OCTA may be a useful imaging modality to evaluate the ocular vascular structure of patients with RA using HCQ.

Keywords: Optical coherence tomography angiography, rheumatoid arthritis, hydroxychloroquine

[Abstract:0109]**Akduman Myopia Support Device (Titanium Macular Buckle): Outcomes of the First Three Cases**Levent Akduman¹, Sengul Ozdek², Serhat Ermis³,Ozgur Artunay⁴¹Eye Care Partners, St. Louis, MO, USA²Gazi University Department of Ophthalmology, Ankara, Turkey³University of Health Sciences, Department of Ophthalmology, Basaksehir City Hospital, Istanbul, Turkey⁴University of Health Sciences, Department of Ophthalmology, Beyoglu Eye Research Hospital, Istanbul, Turkey

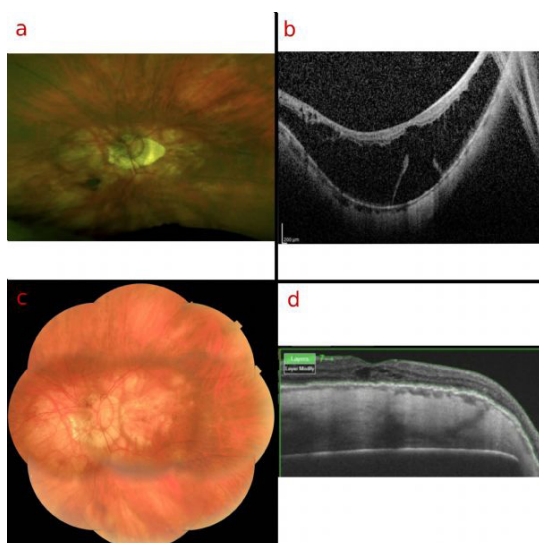
Purpose: To present the outcomes of the first three cases of the Akduman myopia support device (titanium macular buckle) in patients with pathologic myopia.

Methods: To date, three patients have received the Akduman myopia support device (Figure 1). In the first case, the device was used in a combined vitrectomy and macular buckle surgery to close a recurrent myopic macular hole. The surgery involved a combination of vitrectomy and macular buckle. In the second case, the buckle was placed and no vitrectomy was done to treat a myopic posterior pole detachment with maculoschisis. In the third case, a combined vitrectomy and macular buckle was performed to repair a posterior pole retinal detachment.

Results: The macular hole was successfully closed in the first case and remained closed 15 months after surgery. The buckle was removed at two months. In the second case (Figure 2), follow-up was 6 months: the posterior pole retinal detachment and maculoschisis were resolved. In the third case, which involved persistent posterior pole detachment and maculoschisis with an inner retinal hole, the detachment and the maculoschisis were completely resolved at 1 month when the buckle was used in combination with vitrectomy.

Conclusion: The Akduman myopia support device effectively addresses primary posterior pole pathology requiring surgical repair, with or without vitrectomy, based on the pathophysiology of the macular problem as previously described in the myopic traction maculopathy (MTM) classification by Parolini et al. The device's easier placement procedure, concave natural design that supports the posterior pole, and stability with no dislocation after placement are advantageous aspects. Macular buckles can be a valuable addition to surgical procedures with vitrectomy or as a standalone procedure for repairing macular pathology in myopic degeneration

Keywords: Macular buckle, myopic degeneration, retinal detachment

Akduman myopia support device (Titanium macular buckle)**Preoperative (a and b) and post-operative (c and d) color and OCT****[Abstract:0110]****Severe anterior persistent fetal vasculature: the role of anterior retinal elongation on prognosis**

Sengül Özdek², Ece Özdemir Zeydanlı¹, Burak Acar², Hüseyin Baran Özdemir², Hatice Tuba Atalay²

¹Ankara Retina Clinic, Ankara, Turkey

²Ophthalmology Department, Gazi University School of Medicine, Ankara, Turkey

Purpose: To investigate surgical outcomes of eyes with severe anterior PFV and the role of associated anatomical anomalies on prognosis.

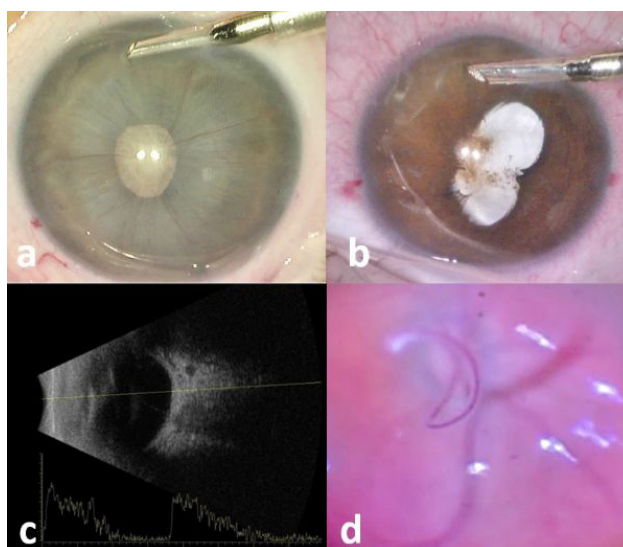
Methods: Consecutive series of 32 eyes of 31 patients with severe anterior PFV, defined as fibrovascular tissue totally covering the back of cataractous lens. Based on the degree of anterior retinal elongations, cases were classified as follows: Group 1, eyes with well-developed pars plana and

minor/no abnormalities (n=11, 34%); Group 2, eyes with partially-developed pars plana and broader-based elongations (n=9, 28%). Group 3, eyes with no visible pars plana and fibrovascular membrane (FVM) having 360-degree continuity with peripheral retina (n=12, 38%). Complications, functional and anatomical outcomes were investigated.

Results: The median surgical age was 2 (1-12) months. The median follow-up was 26 (6-120) months. Seventy-three percent in Group 1 achieved finger counting or better vision with a single surgery and without any pupillary/retinal complication. Group 2 and 3 required 2.1 ± 0.9 and 2.6 ± 1.2 surgeries on average. Pupillary obliteration and RD occurred in 33% and 22% in Group 2, and 58% and 67% in Group 3. Retina remained attached after silicone oil removal in 89% of Group 2 and in 25% of Group 3. Phthisis developed in one eye (11%) in Group 2 and 6 eyes (50%) in Group 3. Incomplete removal of FVM was associated with a 4-fold increased risk of pupillary obliteration and a 3-fold increased risk of postoperative RD.

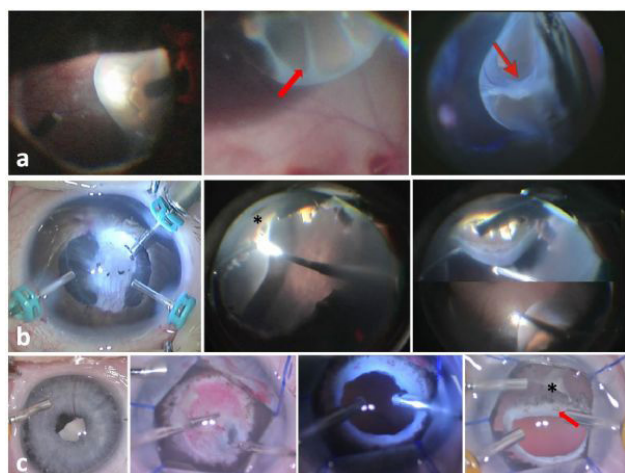Conclusion: Peripheral retinal anomalies are common in severe anterior PFV and have a major impact on prognosis. Prognosis is favorable in cases with mild to moderate anomalies with complete removal of FVM and appropriate management of possible retinal tears. In eyes with 360-degree retinal elongations, severe fibrous proliferation and eventual eye loss are common.

Keywords: persistent fetal vasculature, anterior PFV, peripheral retinal elongation

Figure 1

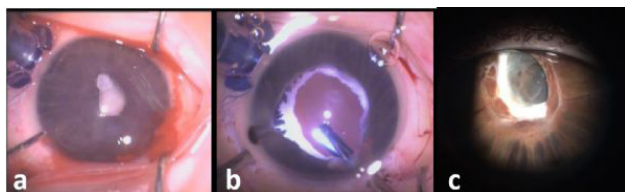
Severe Anterior PFV. Anterior segment features include total leukocoria and an extensive fibrovascular membrane obliterating the pupil, often accompanied by radial iris vessels, posterior synechiae, shallow anterior chamber and cataract (a, b). Ultrasonography shows a subtle hyperechoic stalk extending from the optic nerve, which may sometimes be overlooked (c). Thin hyaloid artery remnants are seen during surgery without other apparent posterior segment pathology (d).

Figure 2



Group 1 included eyes with a well-developed pars plana and without any peripheral retinal abnormalities or those with thin finger-like projections (arrows) extending anteriorly beyond the ora serrata (a); Group 2 eyes had broader-based peripheral retinal elongations with partially-developed pars plana, as in this case where elongated retina and a tear (asterisk) are seen in the nasal quadrant, while the remaining peripheral retina-pars plana region was normal (b); Group 3 had no pars plana formation at all and the retina had 360-degree continuity with the pupillary membrane as in this example (c). Note that in this case, following central opening of the fibrovascular membrane, preparations were made for a 360-degree retinotomy by separating the posterior hyaloid first. At this point, the ciliary body and the retina (asterisk), which are the continuation of the ring-shaped fibrovascular tissue remnant (arrow), were dramatically detached just before the retinotomy was made, and the operation could only be continued by holding this tissue with the iris retractors.

Figure 3



Surgical images of a patient with severe anterior PFV who underwent lensectomy-vitreotomy at 1 month of age; the peripheral part of the fibrovascular membrane had been left intact during the surgery (a, b). Within 4 years of follow-up, the patient developed gradual peripheral tractional RD caused by 360-degree continuity of the residual fibrotic membrane with the peripheral retina. Although the posterior pole was not affected at first, RD progressed over time reaching the pupillary plane and causing leukocoria at 5 years of age (c).

[Abstract:0111]

Surgical Outcomes of Posterior Persistent Fetal Vasculature Syndrome: Cases with Tent-Shaped and Closed Funnel-Shaped Retinal Detachment

Ece Ozdemir Zeydanli², Sengul Ozdek¹, Burak Acar¹,

Huseyin Baran Ozdemir¹, Hatice Tuba Atalay¹

¹Ophthalmology Department, Gazi University School of Medicine, Ankara, Turkey

²Ankara Retina Clinic, Ankara, Turkey

Purpose: To determine the role of vitreoretinal surgery (VRS) for two different forms of posterior persistent fetal vasculature syndrome (PFVS); with tent-shaped tractional retinal detachment (TRD) and closed funnel-shaped TRD.

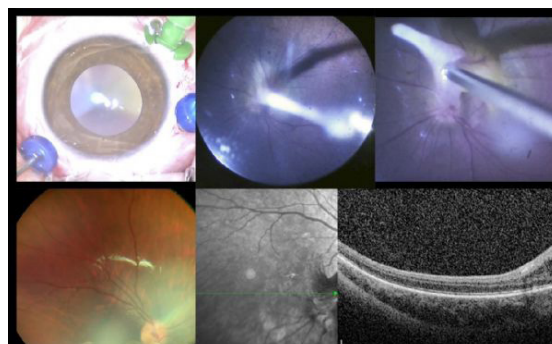
Methods: Retrospective, single-surgeon, consecutive series of 52 eyes of 44 patients with posterior PFVS who underwent VRS. Cases were divided into “tent-shaped RD” and “funnel-shaped RD” groups based on the preoperative TRD configuration. Functional and anatomical outcomes were evaluated.

Results: 30 eyes of 29 patients presented with tent-shaped TRD; 67% obtained counting fingers or better vision, 90% achieved complete or near-complete attachment of the retina. 22 eyes of 15 patients presented with leukocoric pupils associated with funnel-shaped TRD; 45% achieved LP vision, and cosmetically acceptable appearance in 86%. Of the patients with bilateral funnel-shaped RD, 70% had LP in at least one eye. The median length of follow-up was 12 (3-70) months.

Conclusion: VRS often provides functional vision and anatomy in posterior PFVS with tent-shaped TRD morphology. In funnel-shaped TRD morphology, where no treatment has historically been recommended, VRS may be considered with an aim of restoring LP and cosmesis, particularly in bilateral cases.

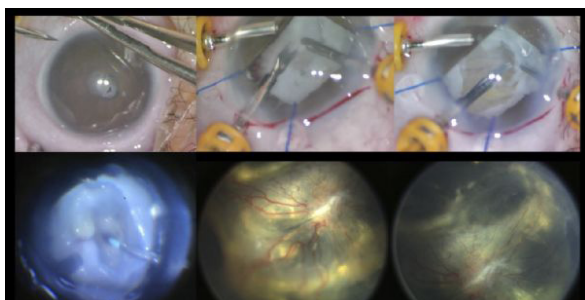
Keywords: Persistent fetal vasculature, posterior PFV, retinal detachment

Figure 1



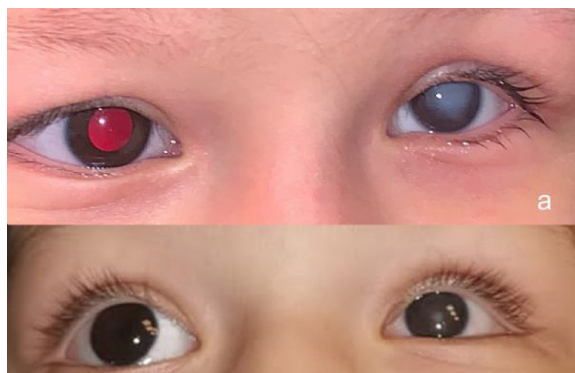Surgical images of a patient with a mild form of predominantly posterior PFV with a tent-shaped eccentric stalk TRD who underwent lens-sparing vitrectomy; the narrow and eccentric attachment of the fibrovascular stalk to the posterior capsule and the fibrovascular stalk causing peripapillary tenting are seen (upper row). After 5 years of follow-up, visual axis remained clear with a very small paracentral opacity at the back of the lens and the visual acuity was 20/100. Color fundus and optical coherence tomography images show complete flattening of the retina with residual fibrosis at the optic nerve head (bottom row).

Figure 2



Surgical images of a patient with severe closed-funnel posterior PFV. Leukocoric pupil with synechiae, elongated ciliary processes, and removal of membranes are demonstrated (upper row). Wide opening of the funnel was possible with painstaking dissection of membranes in both eyes. Dysplastic retina remained detached but receded and became shallow over time (bottom row). Patient achieved light perception vision.

Figure 3



An 18-month-old baby girl with severe form of mixed PFV coming for a second opinion to reverse the increasing corneal opacification in the left eye that causes worsening cosmetic problem every month. B-scan ultrasonography revealed a closed funnel retinal detachment. Note the large central corneal opacification (a) secondary to irido-lenticulo-corneal adhesions, which was significantly reversed after lensectomy and synechiolysis done for cosmesis. (b) Picture taken 6 months after the operation shows a central leukocoria with very mild corneal edema in the left eye. The parents were very satisfied with the cosmetic result.

[Abstract:0119]

The Impact of OCT Double Layer Sign Characteristics on Long-Term Visual Prognosis of Patients with Non-Exudative Age Related Macular Degeneration

Aysegul Mavi Yildiz

Bursa Retina Göz Hastanesi

Purpose: To assess the predictive value of optical coherence tomography (OCT) double layer sign (DLS) features on subclinical, non-exudative macular neovascularization (NE-MNV) and visual prognosis in patients with non-exudative age-related macular degeneration (NE-AMD).

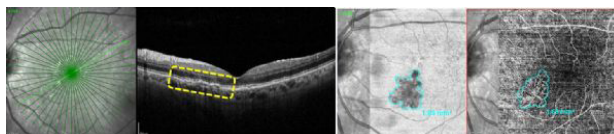
Methods: 48 patients with DLS on OCT who were diagnosed with NE-AMD between 2016-2020 were included. The minimum follow-up was 12 months. The presence of NE-MNV on OCT angiography, the maximum area of the DLS and type 1 MNV on en-face structural OCT, the thickness of the choroid beneath the DLS, and its topographically symmetrical area with respect to the horizontal raphe on EDI-OCT and the maximum base width and height of the DLS were recorded. The relationship between the features of the ‘double layer sign’ and the presence and exudation rates of NE-MNV during the follow-up period were recorded.

Results: The mean age was 75.9 ± 7.5 years. The mean follow-up period was 20.9 ± 9.5 months. NE-MNV was detected in 83.3% of the patients and signs of exudation were observed in 30% of these cases. The mean area of ‘DLS and MNV’ were 3.1 ± 3.6 (0.1-13.2) mm² and 2.9 ± 2.9 (0.4-10.0) mm² respectively. The thickness of the sub-DLS and topographically symmetrical choroid were 301.4 ± 74.1 μ m and 221.9 ± 64.3 μ m respectively ($p < 0.001$). The base width and height of the DLS were 1895.0 ± 1114.6 μ m and 105.5 ± 50.2 μ m respectively. The mean area and base width of the ‘DLS’ were significantly correlated with the presence exudation rate of MNV ($p < 0.05$).

Conclusions: A significant correlation of 70-85% has been reported between the type 1 MNV and DLS in AMD cases. Upon the current literature, our study revealed that the base width and the area of the DLS are also significant predictive features to estimate the presence and exudation rate of NE-MNV.

Keywords: Age related macular degeneration, double layer sign, macular neovascularization

Figure 1



The B-scan optical coherence tomography (OCT), en-face OCT and OCT-angiography images of the same patient with non-exudative macular neovascularization. The base diameter and area of the double layer sign on OCT is consistent with the area of type 1 neovascularization on OCT angiography.

[Abstract:0127]**Different Clinical Entity Findings of Patients with Polypoidal Choroidal Vasculopathy**

Yasin Sakir Goker

Goker Eye and Retina Center, Ankara, Turkey

Purpose: To present the different clinical entity findings of patients with polypoidal choroidal vasculopathy (PCV) disease.

Cases: Case 1: A 53-year-old female patient applied to our outpatient clinic for routine eyeglass examination. BCVA is 20/20 and biomicroscopic evaluation is unremarkable. On fundus examination she has pigment epithelial detachment (PED), double layer sign of PED with no subretinal fluid on spectral domain oct (SD-OCT). OCTA showed branching vascular network in choriocapillaries segmentation but not reached outer retina. The patient was followed monthly with OCTA. At 6th month examination subretinal fluid was developed and a loading dose of anti-vegf therapy was started. Case 2. A 62-year-old male patient admitted to our clinic with a complaint of low vision in the right eye for three months. BCVA is 20/1250 and 20/25 respectively. Fundus examination revealed massive dehemoglobinized subretinal hemorrhage on the right eye and PEDs on the left eye. SD-OCT showed double layer sign with subretinal fluid on the left eye. Polyps were observed in the OCTA and FFA on left eye. A loading dose of anti-vegf therapy was started for both eyes. At 3rd month examination BCVA was 20/640 and 20/20 respectively. One week later the patient presented with massive subretinal hemorrhage in the left eye. Case 3-4. A 65-year-old female one-eyed patient with a macular scar in her left eye and A 67-year-old female one-eyed patient with a macular scar in her right eye were being followed in the retina clinic. Both of the patients developed double layer sign on SD-OCT and OCTA demonstrated PCV in both eyes. The patients were followed 5-7 years. Case 5-6. Patients with high and steep PEDs with double-layer sign with subretinal fluid on SD-OCT were demonstrated. OCTA showed polyps in choriocapillaries segmentation.

Conclusion: Combination of SD-OCT and OCTA can be used to screen PCV.

Keywords: Spectral domain optical coherence tomography angiography, pigment epithelial detachment, polypoidal choroidal vasculopathy

[Abstract:0130]**Oral Fluorescein Angiography using Broadline Imaging Technology for retinal disease**

Sangeet Mittal

Thind Eye Hospital, Jalandhar

Purpose: To evaluate use of oral fluorescein angiography using broadline imaging widefield fundus camera in various retinal diseases.

Methods: 445 eyes in 236 patients underwent Oral Fluorescein Angiography. 25 mg/kg body weight (1 ampule for every 25 Kg) Dye dissolved in 30 ml sugar free juice was given to patient followed by another 30 ml juice without the dye. Angiograms were taken at regular intervals (Every minute for first 5 minutes followed by every two minutes for 5 10 minutes followed by every 5 minutes upto 30 minutes).

Observations: Good to average quality images were obtained in 99.1% images. Earliest images were obtained as soon as 1 min 35 seconds (Mean 8'45"). Incidence of nausea/vomiting was significantly less with oral angiography as compared to IV FFA(0.84% vs 5.79%).

Discussion: Oral FA is safer with less side effects. It is less invasive with no risks of venipuncture. It is specially preferable in children and in patients with previous problems with IV use. Oral FA is dynamic, reproducible & multiple procedures can be done simultaneously.

Conclusions: OFA is safe, less invasive, well tolerated procedure with high sensitivity. Quality images can be obtained in >99% eyes. It can be performed in most indications. To obtain a comprehensive evaluation in common retinal diseases and to reduce risks and discomfort of the IVFA, oral FA may be considered for clinical purposes.

Keywords: Fluorescein, Angiography, Optical Coherence Tomography

[Abstract:0132]**Adjunctive intravitreal anti-VEGF and moxifloxacin therapy in the management of intraocular tubercular granulomas**Manisha Agarwal¹, Chanda Gupta¹, Varsha K Mohan²,Pramod Upadhyay², Aditi Dhawan², Vivek Jha¹¹DR SHROFF'S CHARITY EYE HOSPITAL²NATIONAL INSTITUTE OF IMMUNOLOGY

Purpose: To report pre and post treatment levels of anti-VEGF in the aqueous humour of patients with intraocular tubercular granulomas and study the effect of a combined intravitreal anti-VEGF bevacizumab and moxifloxacin therapy on their regression

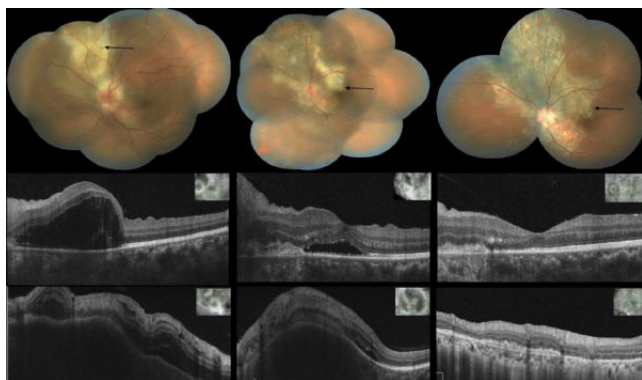
Methods: Aqueous humour samples of 10 consecutive patients with intraocular tubercular granulomas obtained before and after initiating treatment were subjected to ELISA for analysing intraocular VEGF-A levels. Intravitreal injections of bevacizumab (off label use) and moxifloxacin were given weekly till complete regression of these granulomas. All patients received the usual four drug ATT and oral corticosteroids.

Results: mean baseline VEGF-A levels was 1004.27 +/- 411.40 pg/ml which reduced significantly to 27.62 +/- 46.86 pg/ml. Mean number of injections required were 3.1 (2-4). There was a significant correlation between the clinical regression of the granulomas and VEGF-A levels in the aqueous humour.

Conclusion: Intraocular TB granulomas have high levels of VEGF-A. Weekly intravitreal injections of anti-VEGF bevacizumab with moxifloxacin as an adjunct to the standard care may cause prompt regression of tubercular granulomas

Keywords: Tubercular granulomas, VEGF

tubercular granuloma



tubercular granuloma regression with decrease in VEGF levels after giving intravitreal anti-VEGF and moxifloxacin

[Abstract:0135]

Evaluation of bioclinical markers to predict short term response to intravitreal anti-VEGF in treatment-naïve diabetic macular edema and the "Fried Egg" sign: a novel OCT feature

Indu Govindaraj, Neethu Pradeep, Mugundhan Tulasiraman, Anand Rajendran, Damodaran Vasudevan, Bharg N N Kariya, Aruna Kothandaraman

Aravind eye care system- Chennai

Objective: To determine the incidence of suspended scattering particles in motion (SSPiM) and to assess baseline bioclinical markers in treatment-naïve diabetic macular edema (DME) which can predict the short term response to intravitreal anti-VEGF.

Design: Prospective observational study.

Participants: Treatment-naïve DME patients from January 2022 to June 2022 were included in the study.

Methods: Treatment-naïve DME cases were included and followed up for three months. Best corrected visual acuity (BCVA), SSPiM, HbA1c levels, hyperreflective dots (HRD), sub retinal fluid (SRF), central subfoveal thickness (CSFT), optical density ratio (ODR) of the largest cyst near the fovea, type of cyst (uniformly hyperreflective or fragmented intracystic hyperreflectivity called "fried egg" sign) at baseline were studied to predict response to treatment after anti-VEGF.

Results: 123 eyes of 88 patients were included in the study. Incidence of SSPiM was 64.5%. The mean incidence of poor responders was 35%. BCVA, ODR, hyperreflective cysts and

presence of SSPiM were not associated with response to anti-VEGF. Higher CSFT, SRF, higher number of HRD, presence of SSPiM in the outer nuclear layer (ONL) and outer plexiform layer (OPL) were associated with short term good response to anti-VEGF. High HbA1c and presence of "fried egg" sign in the hyperreflective cysts were associated with poor response.

Conclusion: Higher CSFT, SSPiM in the ONL and OPL, and higher HRD were associated with good response to anti-VEGF. High HbA1c and "fried egg" sign was associated with poor response to anti-VEGF. BCVA, presence of SSPiM and ODR were not associated with anti-VEGF response.

Keywords: SSPiM, Hyperreflective dots, optical density ratio

[Abstract:0138]

Clinical Presentation and Outcome of Patients with Endogenous Endophthalmitis: A Case Series

Serife Çiloğlu Hayat, Yusuf Cem Yılmaz, Serhat Ermiş, Ece Özal, Murat Karapapak, Hakan Baybora, Sadık Altan Özal
Basaksehir Cam and Sakura City Hospital Ophthalmology, Istanbul, Turkey

Endogenous endophthalmitis (EE) is a rare but severe ocular infection that can lead to permanent vision loss. The aim of this study was to evaluate the clinical characteristics, risk factors, microbiological findings, and visual outcomes of patients diagnosed with EE. This retrospective study of 15 eyes from 10 patients diagnosed with EE was conducted. The mean age of presentation was 56.5 years, with a male predominance. The most common predisposing factors were diabetes mellitus and recurrent urinary tract infections. The initial vision of the thirteen eyes was 0.1 or less. Five eyes (33.3%) had hypopyon at the initial examination. Positive blood cultures were found in 40% of patients, while positive vitreous cultures were found in 20% of patients. The majority of cases were caused by bacterial infections. All patients received systemic antibiotics as well as appropriate intravitreal antibiotics. Initial treatment, which included obtaining a vitreous sample via a vitrectomy probe and administering intravitreal antibiotics, was performed in all eyes (100%) upon clinical diagnosis. Pars plana vitrectomy was performed in nine out of the 15 eyes (60%). It was observed that pars plana vitrectomy was performed in both eyes of two patients in the same session. The mean final visual acuity was 1.57 ± 1.02 logMar, with no significant difference between the bacterial and fungal groups. These findings provide insight into the clinical characteristics and outcomes of EE, which can aid in the diagnosis and management of this rare but potentially severe condition.

Keywords: Endogenous endophthalmitis, vitreous cultures, pars plana vitrectomy

[Abstract:0140]**Free ILM flap for Retinal Detachment secondary to Juxta-Papillary holes in Peripapillary Staphylomas**Sangeet Mittal

Thind Eye Hospital, Jalandhar, India

Purpose: To evaluate the use of ILM flap to close holes lying inside the peripapillary staphylomas associated with Retinal Detachment (RD)

Methods: Seven patients of RD associated with holes lying inside the peripapillary staphyloma underwent vitrectomy. ILM flaps were used to stuff the holes. Peripapillary laser was done in select cases. Silicon Oil/Gas was used as a tamponade as required.

Results: Six patients had high pathological myopia associated with peripapillary type 3 staphyloma. One patient had staphyloma associated with optic disk coloboma. All patients presented with sudden decrease of vision. All patients were discovered to have micro holes within area of chorio-retinal atrophy associated with posterior staphyloma. Laser was done around the optic nerve head in 4 eyes. Silicon Oil was used for tamponade in 3 eyes and Per-fluoro Octane gas was used in 4 eyes. Retina was attached in all eyes. In 6 eyes, the retina was attached with single surgery.

Conclusion: Long term success was achieved by vitrectomy using free ILM flap over juxta-papillary holes. ILM flap worked even in eyes where laser was not possible around the holes.

Keywords: Retinal Detachment, Posterior Staphyloma, ILM flaps

[Abstract:0144]**To the question of proliferative vitreoretinopathy classification**Natalia Kislitsyna¹, Sergey Novikov²¹Eye Microsurgery Complex Institute of Professional Education²Eye Microsurgery Complex SEP Ltd

The purpose of this work was to study the anatomic and topographic specifics of vitreous body (VB) and vitreoretinal interface (VRI) changes at different proliferative diabetic vitreoretinopathy (PDVR) during chromovitrectomy of A,B,C stages of proliferative diabetic vitreoretinopathy (P.Kroll's classification of PDVR, 2007).

Vitreocontrastography – original vitreous visualisation technology. The first group included 52 patients (52 eyes) with diagnosed PDVR, stage A. According to B-scanning, 22 patients had PVD with local fixations causing local tractional elevation 0.7-0.9 high; 30 patients had hemophthalmia, the retina is attached. In the stage B group 47 patients (47 eyes). In the third group stage C were 32 (32 eyes). Vitreocontrastography

Results: Definition of the new stage– A-1: It is necessary to note that the application of the developed technique of VB

imaging (in comparison with the reference classification) made it possible to identify the new stage of PDVR defined by us A-1. A1. Anterior cortical layers are preserved, VB structures are preserved (cisterns.), The retina is fully attached without the visible ophthalmological changes of the vitreous and retina, VB layer with certain topography (taking the central area of the eye fundus.) vitreous layers in the central zone of VB layers in the central area of VRI vascular arcades. In 70% of the cases this layer can be quite easily separated from the retina by the forceps (average level of adhesion), in 30% the VB layer is characterized by a high level of adhesion with the possibility of their partial removal. Stage A-2. - Anterior cortical layers and VB structures are preserved. In the central zone 2-3 layered VB cortical layer is preserved. The layers are formed by vitreoschisis zones. On the retinal surface VB layer firmly fixed to the ILM in the macular zone is contrasted.

Keywords: diabetic retinopathy, vitreocontrast, vitreocontrastography

[Abstract:0148]**Subfoveal Nodule in Coats' Disease: Stages, Prognosis, and Treatment**

Şengül Özdek¹, Murat Yuksel¹, Ece Ozdemir Zeydanli², Hatice Tuba Atalay¹, Huseyin Baran Ozdemir¹, Murat Hasanreisoglu³, Gokhan Gurelik¹

¹Ophthalmology Department, Gazi University School of Medicine, Ankara, Turkey²Ankara Retina Clinic, Ankara, Turkey³Ophthalmology Department, Koc University School of Medicine, Istanbul, Turkey

Purpose: To investigate the prevalence, developmental stages, clinical and demographic factors affecting subfoveal nodule (SFN) development in Coats' disease.

Methods: The medical records and multimodal images of patients with Coats' disease were reviewed retrospectively in a tertiary university setting. Patients with Coats' disease at stages from 2A to 3A were included. SFN development was divided into five stages as follows: Stage 0, macular exudation without subfoveal hard exudate; stage 1, subfoveal exudation; stage 2, packaging of exudates; stage 3, vascularization of SFN; stage 4, subfoveal fibrotic scar. The factors which may have role in the formation and the tempo of SFN development were analyzed.

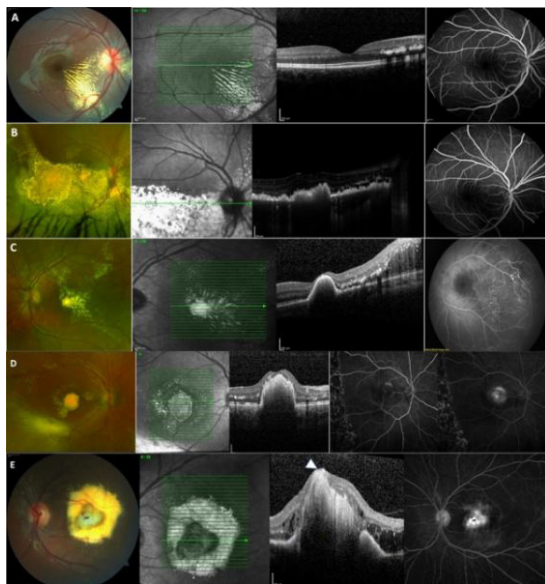
Results: Study included 43 eyes of 42 patients with Coats' disease with a mean age of 6.9±3.9 years and a mean of follow-up of 31.1±29.5 months. The prevalence of SFN was 48% at the beginning and 95% at final follow-up. There was no difference in baseline demographic and clinical characteristics among patients with different SFN stages. Patients developing SFN earlier than 9 months were significantly younger than those in longer period (>9 months) (5.6±3.2 vs 8.9±4.5, p=0.010), and the mean number of intravitreal (IV) anti-vascular endothelial growth factor (anti-VEGF) injection per year was lower in the latter group (3.6±1.2 vs 1.4±1.2, p=0.001). The risk of early SFN development was 2.4 times higher in patients younger than 7 years of age and 4 times higher in patients who received 3 or less IV anti-VEGF injections per year. Patients with considerably good final best-corrected visual acuity (BCVA)

(<1.3 logMAR) had a higher mean number of IV anti-VEGF injections per year than those with poor final BCVA (≥ 1.3 LogMAR) ($p=0.025$).

Conclusion: SFN is commonly seen in Coats' disease and its prevalence was found 95% in our study. Anti-VEGF injection seems to decelerate SFN development and improve the functional result.

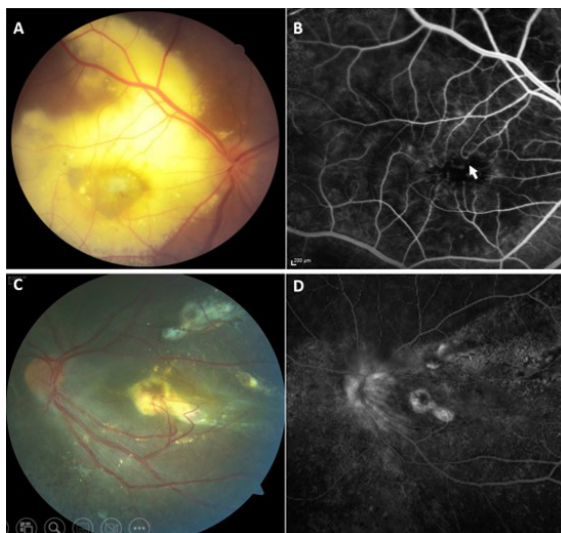
Keywords: Coats' disease, subfoveal nodule, intravitreal Anti-VEGF injection

Figure 1



Developmental stages of subfoveal nodules. A) Stage 0-Macular Exudation without subfoveal hard exudate B) Fundus photograph of a Stage 1- Subfoveal Exudation with dense and scattered subretinal exudates in the fovea C) Stage 2-Packaging of exudates in the subfoveal area with a well-circumscribed dome-shaped hyperreflective line. D) Stage 3- Vascularization of SFN. E) Stage 4-Subfoveal Fibrotic Scar with hyperpigmentation and severe sensorineural retinal atrophy

Figure 2



Vascular features of subfoveal nodules. A) Fundus photograph of a patient with Stage 3-Subfoveal Nodule shows vascular structures diving into the nodule and R-R vascular anastomosis. B) Note the R-R vascular

anastomosis (arrow) in FA in the same patient. C) Fundus photograph of a patient with Stage 4-Subfoveal Fibrosis shows vascular structures diving into the nodule and hyperpigmentation. D) In the same patient, hyperfluorescent staining at the edges of the lesion along with central hypofluorescence due to the blockage of increased fibrosis/scarring are observed in the FA.

[Abstract:0153]

Early detection and treatment of sympathetic ophthalmia

Janin Lou Camangeg Billano, Maria Angelica Villano

Torres, Perfecto Elpidio Octavio Roy Cagampang III

Department of Ophthalmology, Southern Philippines Medical Center, Davao City, Philippines

Sympathetic ophthalmia is a sight-threatening, bilateral granulomatous panuveitis following unilateral trauma or ocular surgery. The epidemiology, management, and prognosis of this disease are poorly described in literature because of its rarity. The purpose of this report is to present the clinical manifestations and subsequent treatment following early recognition of sympathetic ophthalmia. We report a case of a 34-year-old female who developed sympathetic ophthalmia on the right eye, three weeks after a penetrating eye trauma on the left, to which she underwent evisceration. The patient presented with a 2-day history of eye pain, photophobia and blurring of vision on the only seeing eye. Fundus examination revealed serous retinal detachments on the posterior pole as corroborated by ocular coherence tomography and fluorescein angiography. High dose oral and topical corticosteroids were immediately initiated and patient was monitored for progression of the disease. After two months of oral corticosteroids (2mg/kg/day), visual acuity improved from Counting Fingers at 3 feet to 20/20 (-0.5 sph). Our case showed that current medical management with systemic corticosteroids present effective treatment of this potentially devastating disease. Early detection of sympathetic ophthalmia is paramount to achieve favorable visual outcome.

Keywords: sympathetic ophthalmia, ocular trauma, corticosteroids

[Abstract:0157]**Efficacy, Durability, and Safety of Faricimab in Diabetic Macular Edema: 2-Year Results From the Phase 3 YOSEMITE and RHINE Trials**Sibel Kadayifcilar¹, John A. Wells², Zdenka Haskova³, Shaun Mohan³, David Silverman⁴, Yunnan Tang³, Hugh Lin³¹Department of Ophthalmology, Hacettepe University School of Medicine, Ankara, Türkiye²Palmetto Retina Center, Retina Consultants of America, Columbia, SC, USA³Genentech, Inc., South San Francisco, CA, USA⁴Roche Products Ltd., Welwyn Garden City, UK

Purpose: Year 1 data from YOSEMITE/RHINE suggest that dual angiopoietin-2/vascular endothelial growth factor (VEGF)-A blockade with faricimab may promote vascular stability in diabetic macular edema (DME) and extended durability with up to every-16-week (Q16W) dosing. Year 2 evaluated the longer-term efficacy, durability, and safety of faricimab in patients with DME.

Methods: YOSEMITE / RHINE (NCT03622580 / NCT03622593) were double-masked, phase 3 trials. Patients were randomized 1:1 to faricimab 6.0 mg Q8W, faricimab 6.0 mg per personalized treatment interval (PTI), or aflibercept 2.0 mg Q8W. The primary endpoint was mean BCVA change from baseline at 1 year (weeks 48/52/56 average). Other efficacy and safety endpoints were assessed through week 100.

Results: Overall, 1891 patients were enrolled in YOSEMITE/RHINE (N = 940/951). Noninferior vision gains achieved at 1 year were maintained through year 2; mean BCVA change from baseline at 2 years (weeks 92/96/100 average) with faricimab Q8W (YOSEMITE/RHINE, +10.7/+10.9 letters) or PTI (+10.7/+10.1 letters) were comparable with aflibercept Q8W (+11.4/+9.4 letters). In the faricimab PTI arms, durable vision gains were maintained with extended dosing, with > 60% of patients on Q16W dosing and almost 80% on ≥ Q12W dosing at week 96. Mean CST reductions were greater with faricimab versus aflibercept through year 2. More patients achieved absence of DME (CST < 325 µm) and absence of intraretinal fluid with faricimab Q8W or PTI versus aflibercept Q8W through week 100. Faricimab was well tolerated through study end; intraocular inflammation event rates were low across treatment arms (1.1–1.7%). No cases of retinal vasculitis or occlusive retinal vasculitis were reported.

Conclusion: Robust vision gains, anatomic improvements, and extended durability with faricimab up to Q16W were maintained through year 2. Treat-and-extend-based PTI dosing suggests that dual angiopoietin-2/VEGF-A inhibition with faricimab may promote vascular stability and durable efficacy beyond current anti-VEGF therapies for DME.

Keywords: faricimab, YOSEMITE/RHINE, PTI

[Abstract:0158]**Efficacy, Safety, and Durability of Faricimab in Neovascular Age-Related Macular Degeneration: Year 2 Results From the Phase 3 TENAYA and LUCERNE Trials**Levent Karabas¹, David Silverman², Balakumar Swaminathan³, Vaibhavi Patel², Hugh Lin⁴, Jeffrey R. Willis⁴, Aachal Kotecha²¹Department of Ophthalmology, Kocaeli University School of Medicine, Kocaeli, Türkiye²Roche Products Ltd., Welwyn Garden City, UK³F. Hoffmann-La Roche Limited, Mississauga, Canada⁴Genentech, Inc., South San Francisco, CA, USA

Purpose: Year 1 data from the TENAYA/LUCERNE trials support the hypothesis that dual inhibition with faricimab may promote vascular stability and durable efficacy beyond current anti-VEGF therapies for neovascular age-related macular degeneration (nAMD). Year 2 of the TENAYA/LUCERNE trials evaluate longer-term efficacy, durability, and safety of faricimab up to every 16 weeks (Q16W) in patients with nAMD.

Methods: TENAYA (NCT03823287) / LUCERNE (NCT03823300) were identical, global, randomized, double-masked, active comparator-controlled, 112-week, phase 3 trials of faricimab in nAMD. Treatment-naïve patients were randomized 1:1 to faricimab 6.0 mg up to Q16W dosing through week 60 after 4 initial Q4W doses or aflibercept 2.0 mg fixed Q8W dosing through week 108 after 3 initial Q4W doses. After week 60, faricimab-treated patients were treated using a treat-and-extend-based personalized treatment interval regimen. The primary efficacy endpoint was mean change in BCVA from baseline at 1 year, averaged over weeks 40, 44, and 48. Other efficacy/safety endpoints were assessed through week 112.

Results: 1329 patients were enrolled (TENAYA, N = 671; LUCERNE, N = 658). In both trials, mean BCVA for faricimab up to Q16W was noninferior to aflibercept Q8W at year 1. Faricimab offered durability with ~80% of patients on ≥ Q12W dosing intervals and ~45% on Q16W dosing intervals at week 48. Despite reduced injection frequency, mean reductions in CST were comparable between treatment arms. Faricimab up to Q16W was well tolerated, with low rates of intraocular inflammation. Year 2 data will be presented and inform longer-term efficacy, durability, and safety of faricimab.

Conclusion: Year 2 of the TENAYA/LUCERNE trials will explore whether early vision gains, CST reductions, and extended dosing with faricimab (up to Q16W) seen at year 1 are maintained over 2 years in patients with nAMD.

Keywords: faricimab, nAMD

[Abstract:0172]**Anatomical and Functional Outcomes of Vitrectomy with Silicone Punctal Plug for Optic Disc Pit and associated Serous Macular Detachment**

Hussain Khaqan

PGMI, AMC, LGH, Lahore

Purpose: To evaluate the efficacy in terms of anatomical and functional outcomes of vitrectomy with punctal plug for optic disc pit and associated serous macular detachment.

Methods: A non-comparative interventional case series was conducted at the Ophthalmology Department of Lahore General Hospital, Lahore between 2017 and 2023. The study included 07 patients (05 males and 02 females) between the age 25 to 55 years who presented with unilateral optic disc pit associated with serous macular detachment. After informed consent, a detailed preoperative examination was carried out. All the patients underwent 23-gauge pars plana vitrectomy, silicone punctal plug in the pit. The follow up period is 05 years for 03 cases, 03 years for 02 patients while 02 patients had a follow up of 01 year. Anatomic outcome and visual acuity was analysed for all eyes. Optical coherence tomography (OCT) was used to observe the anatomic changes.

Results: This study included 07 patients in which 05 were males (71.43%) and 02 were females (28.57%). The mean age was 40 years. Postoperative visual acuity improved from counting finger (CF) to 6/60 in 02 patients, 6/24 in 03 patients, from hand motion (HM) to 6/36 in 01 eye while 01 patient attained the postoperative visual acuity of 6/9 from perception of light. The serous macular detachment resolved completely between 03 to 18 months postoperative period. No patient had a recurrence of the disease in the follow up period.

Conclusion: Plugging the optic disc pit with the appropriate sized silicone punctal plug is a safe and efficient surgical procedure to achieve both the anatomical and visual outcomes in patients with optic disc pit associated serous macular detachment.

Keywords: Pit, Plug, Punctal

[Abstract:0178]**Does Epiretinal Membrane Affect Diabetic Macular Edema Treatment Results?**

Büşra Güner Sönmezoğlu, Emine Doğan, Erkan Çelik

Sakarya Training and Research Hospital, Ophthalmology, Sakarya

Purpose: To evaluate the effect of epiretinal membrane (ERM) on the results of intravitreal ranibizumab (IVR) injection in the treatment of diabetic macular edema (DME).

Methods: Data of DME patients who treated with IVR injection between 2015 and 2019 were retrospectively analyzed. Patients diagnosed with DME divided into two

groups according to presence of ERM; Group 1 consisted of 26 eyes with ERM, Group 2 consisted of 26 eyes without ERM. Best corrected visual acuity (BCVA) and central macular thickness (CMT) were analyzed and compared between the groups after three consecutive IVR injections.

Results: The mean age of patients were 71.5 ± 6.6 and 65.5 ± 7.7 years, respectively ($p:0.736$). The initial BCVA was 0.88 and 0.77 logMAR in groups, respectively ($p:0.430$). The initial CMT was 363.6 and 413 μ respectively ($p:0.153$). After three consecutive doses of IVR; BCVA was 0.70 and 0.59 logMAR, and CMT was 297.52 and 340 μ in groups respectively, ($p1:0.043$ and $p2:0.096$). CMT decreased significantly in both groups after IVR treatment ($p<0.001$). While BCVA was significantly increased in Group 2 ($p<0.008$), there was no significant improvement in Group 1 ($p=0.082$).

Conclusion: Although there was a significant decrease in CMT after IVR injection in DME patients with and without ERM, visual improvement was not significant in patients with ERM. The presence of ERM may adversely affect visual outcomes in the treatment of DME patients.

Keywords: macular edema, epiretinal membrane, ranibizumab

[Abstract:0191]**The impact of short-term postoperative face-up position on unintentional retinal displacement after pars plana vitrectomy for rhegmatogenous retinal detachment**Mariano Irós¹, Juan Manuel Lopez²¹Instituto de Microcirugía Ocular Córdoba. Córdoba, Argentina.²Department of Ophthalmology, Intercommunal Hospital Center and Henri Mondor Hospital, Paris-Est Créteil University (UPEC, Paris XII University). Creteil, France

Purpose: To evaluate the efficacy and safety of strict short term supine position in preventing the occurrence of unintentional retinal displacement after pars plana vitrectomy (PPV) with gas tamponade for rhegmatogenous retinal detachment (RRD).

Methods: A retrospective observational study was conducted in two ophthalmological surgical centers. Twenty five patients with diagnosis of macula off RRD assumed a strict face-up posture for 2 hours immediately after PPV and 20 % sulfur hexafluoride (SF6) tamponade. Fundus autofluorescence (FAF) imaging was subsequently recorded to detect unintentional retinal displacement using ultrawide-field imaging system Optos, Daytona (Optos Inc, Marlborough, MA, USA) at 1 month postoperatively. Unintentional retinal displacement detected by the presence of retinal vessel printings (RVPs) on the fundus autofluorescence (FAF) imaging.

Results: The mean age of these 25 patients was 58,08 years, range of 28 to 78 years. Of the 25 eyes, retinal detachment involved 1 quadrant in 6 eyes, 2 quadrants in 14 eyes, 3 quadrants in 4 eyes and 4 quadrants in 1 eye. Fundus autofluorescence imaging after complete reattachment of the

retina, FAF photography demonstrated RVPs in 2 of the 25 eyes.

Conclusion: Our findings suggest that strict face up positioning for 2 hours after PPV with gas tamponade for macula off RRD, was associated with a reduction in the incidence and degree of postoperative unintentional retinal displacement.

Keywords: retinal detachment, retinal displacement, vitrectomy

[Abstract:0192]

Posterior segment ocular findings in critically ill patients with COVID-19

Rosa Maria Romero Castro¹, Matilde Ruiz Cruz²,
Claudia Alvarado¹, María González Cannata¹,
Yara Luna Villalobos¹, Ana García Morales¹,
Yuria Ablanado Terrazas³, Mauricio González Navarro¹,
Santiago Avila Ríos¹

¹Centro de Investigación en Enfermedades Infecciosas, Instituto Nacional de Enfermedades Respiratorias Ismael Cosío Vil- legas, Mexico City, Mexico;

²Asociación Para Evitar la Ceguera en México, I. A. P., Mexico City, Mexico

³Centro Médico ABC Santa Fe, Mexico City, Mexico.

Purpose: To describe ophthalmological fundoscopic findings in patients with COVID-19 admitted to the intensive care unit of the largest third-level referral center for COVID-19 in Mexico City.

Methods: In this cross-sectional single-center study, consecutive patients admitted to the intensive care unit with a diagnosis of COVID-19 underwent fundus examination with an indirect ophthalmoscope. Clinical photographs were taken using a posterior-pole camera. We explored the association between ocular manifestations and demographic characteristics, inflammatory markers, hemodynamic factors, and comorbidities.

Results: Of 117 patients examined, 74 were men; the median age was 54 years (range: 45–63 years). Forty-two patients had ophthalmological manifestations (unilateral in 23 and bilateral in 19), and 10 of these patients had more than one ophthalmological manifestation. Ocular findings were papillitis (n = 13), cotton wool spots (n = 12), retinal hemorrhages (n = 5), retinal nerve fiber layer edema (n = 8), macular whitening (n = 5), retinal vascular tortuosity (n = 4), papillophlebitis (n = 3), central retinal vein occlusion (n = 1), and branch retinal vein occlusion (n = 1). Ocular fundus manifestations were not associated with demographic characteristics, inflammatory markers, hemodynamic factors, or comorbidities.

Conclusion: More than one-third of patients with severe COVID-19 had ophthalmological manifestations. The most frequent fundoscopic findings were optic nerve inflammation, microvasculature occlusion, and major vascular occlusions. We recommend long-term follow-up to prevent permanent ocular sequelae.

Keywords: Covid-19, papillitis, retina vein occlusion

Papillitis

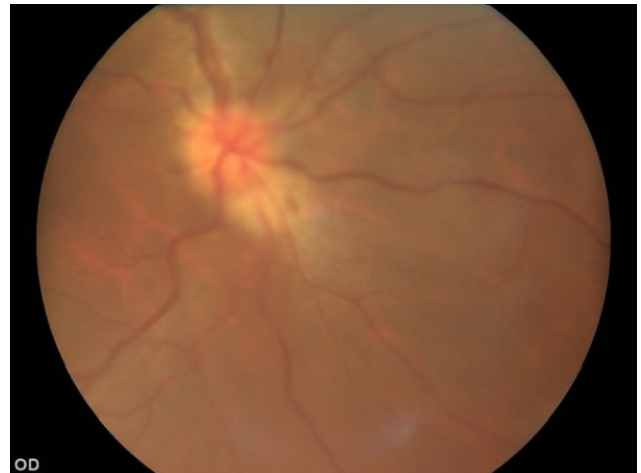


Fig 1. Color fundus photograph showing papillitis and microhemorrhage in a patient with severe COVID-19.

[Abstract:0193]

Trans-choroidal Hybrid Technique In Management Of Subretinal Proliferation

Maged Mikhael Gergess
Al Watany Eye Hospital

Purpose: To evaluate combined techniques and the surgical impact in management of sub retinal proliferation in old standing retinal detachment

Introduction: Subretinal proliferation in retinal detachment may complicate the surgical procedure and postoperative visual outcome and its location may add difficulties in removal with carrying risk for more interoperative complications

Methods: Approaching the SRF through posterior placed 23G cannula after removal of cortical vitreous with posterior hyaloid and insertion of crocodile forceps in the subretinal space through the trocar in the area of highest fluid level till reaching the good point of attack with good grasping and gradual withdrawal of membranes to get out from the globe through posterior placed trocar. Other sub retinal proliferation especially peripherally place was removed by regular techniques either from above the surface of the retina through small retinotomy or from under surface of the retina through large retinotomy and folding of the retina.

Conclusion: The commonest way for removal of sub retinal perforation either above surface of the retina through small retinotomy or from under surface of the retina through large retinotomy and folding of the retina and removal of sub retinal proliferation either unimanually or bimanually but the main problem in these techniques in posterior placed sub retinal proliferation especially under macula is the high incidence of post operative PVR in posterior placed retinotomy while

on doing large peripheral retinotomy and folding the retina to grasp the sub retinal proliferation under the macula is interoperative trauma to the choroid under the macula while reaching to posterior placed proliferation so the best way for removal of these proliferation is transchoroidal approach in sub retinal space without any additional retinal tear grasping the membranes and their removal out from the eye the postoperative recovery in these patient was rapid with least post operative complication

Keywords: Subretinal fibrosis, PVR, old standing retinal detachment

[Abstract:0194]

Interoperative OCT in Management Of Submacular Hemorrhage, Is it additional tool ?!!

Maged Mikhael Gergess
Al Watany Eye Hospital

Purpose: To evaluate a new technique and the surgical impact with visual outcomes in management of sub macular hemorrhage caused by choroidal neovascularization (CNV), trauma, and ruptured retinal arterial macroaneurysm (RAM) operated with iOCT-assisted vitrectomy with subretinal injection of recombinant tissue plasminogen activator (rt-PA) followed by aspiration of liquified blood under monitoring of interoperative OCT

Methods: iOCT-assisted vitrectomy was performed with subretinal injection of recombinant tissue plasminogen activator (rt-PA) of a dose of 25 ug in 0.1 ml using a 38G needle with soft tip and for a submacular hemorrhage caused by choroidal neovascularization (CNV), trauma, and ruptured retinal arterial macroaneurysm (RAM). injection of small bubble of perfluorocarbon liquid (PFO) after finalizing the vitreous base shaving to give time for the action of r-TPA with aspiration of liquified blood using the same subretinal needle under clear visualization of the site of the needle using iOCT after frequent shaking of the glob making dancing PFO bubble to help in liquefaction and drainage of liquified blood by compression and shifting of blood to the site of aspirating needle

Conclusion: iOCT-assisted vitrectomy with subretinal rt-PA injection and aspiration of liquified blood with the aid of PFO bubble and gas tamponade were accurate in removing and displacing the submacular blood with rapid visual recovery. Also the use of iOCT helps monitoring the site of injection as well as the site of aspiration of liquified blood and the most important value is monitoring the stretching effect of the fovea during injection to avoid development of iatrogenic macular hole.

Keywords: iOCT, Submacular hemorrhage

[Abstract:0195]

Trimanual vitrectomy for severe proliferative diabetic retinopathy

Samir El Baha, Islam Sherin Ahmed
Alexandria University, Egypt

Purpose: To describe and evaluate a novel technique of pars plana vitrectomy (PPV) under chandelier illumination which is aided with the vital dyes and perfluorocarbon liquids for the management of the complex diabetic vitrectomy cases.

Methods: We conducted a prospective interventional comparative study on 40 eyes of 36 patients with advanced diabetic eye disease requiring PPV. The study was conducted in a single tertiary referral center. Eyes were divided on 1:1 basis by stratified randomization into two groups. Group 1 had trimanual vitrectomy done assisted with chandelier illumination, perfluorocarbon liquid (PFCL) and vital dyes. Group 2 had the conventional bimanual vitrectomy done assisted with chandelier illumination only. All patients were followed up for a minimum of 6 months after the surgery.

Results: Forty eyes of 36 patients with the mean age of 51.42 years (range 28-69) were evaluated. The anatomical success at 6 months could be achieved in all the eyes in both groups. The complete removal of the pre-retinal proliferations could be accomplished in all the eyes in the trimanual PPV group, and only in 85% of the eyes in the bimanual PPV group. Operative time was significantly shorter in the trimanual PPV group ($p < 0.001$). More eyes in the trimanual PPV group (55.0%) could achieve better vision ($> 6/60$) 6 months after the operation compared to the bimanual PPV group (50.0%), but this difference was not statistically significant.

Conclusion: Trimanual PPV is a novel, safe and effective technique that can improve the results of the complex diabetic PPV.

Keywords: Diabetic vitrectomy; Pars plana vitrectomy; Perfluorocarbon liquids; Vital dyes

[Abstract:0196]

PVR Game

Samir El Baha
Alexandria University

This presentation demonstrate how to manage ERM and starfolds in cases of PVR. Also how to deal with Subretinal bands and napkins ring. Different techniques of retinotomy and retinectomy.

Keywords: Retinotomy, napkins ring, Subretinal band

[Abstract:0203]

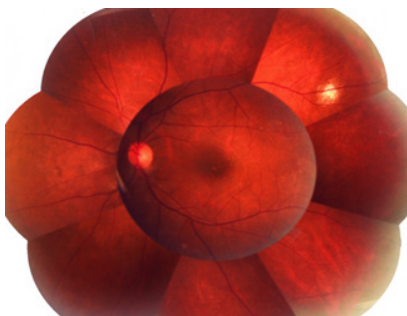
Case Report of Post-typhoid Neuroretinitis: A Rare Cause of Visual Morbidity

Charmaine Grace Malabanan Cabebe, Redentor Caesar G Gonzales, Perfecto Elpidio Octavio Roy Cagampang III
Department of Ophthalmology, Southern Philippines Medical Center, Davao City, Philippines

Post-typhoid fever neuroretinitis is a rare presentation, which is not well recognized and established. A 55-year-old female, previously admitted for typhoid fever, presented with a sudden onset, painless blurring of vision of the left eye. Visual acuity was 20/20 OD and counting fingers at 3 feet OS. Grade 1 relative afferent pupillary defect with dyschromatopsia was noted on the left eye. Fundus examination of the left eye revealed disc edema and a macular star exudate. Areas of retinitis at the peripapillary area and distal third of the supero-temporal arcade were noted. Patient was given prednisolone (1mg/kg/day) and was gradually tapered for 8 weeks with regular monitoring. At 6 months follow-up, vision of the left eye improved to 20/40. Fundus exam revealed moderate resolution of disc edema with residual exudates at the macula, and retinitis at the distal third of the supero-temporal arcade.

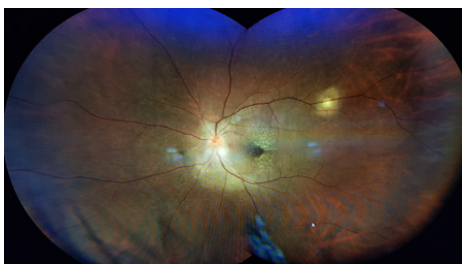
Keywords: case report, neuroretinitis, typhoid fever

Fundus photo of left eye after treatment



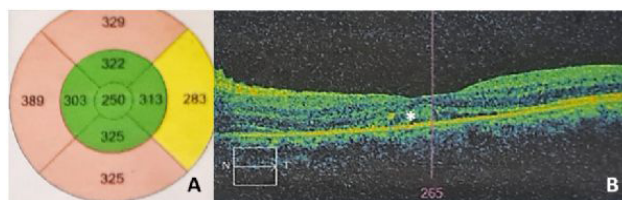
Fundus photo of the left eye at 6 months follow-up. There is resolution of disc edema with residual exudates at the macula, and retinitis at the distal third of the supero-temporal arcade

Fundus photo of left eye prior to treatment



Pretreatment fundus photograph of left eye. Disc edema and macular star exudates (arrow) are present with retinitis at the peripapillary area and distal third of the supero-temporal arcade (asterisk).

OCT of the left eye at presentation



A. Perifoveal area is thickened (outer circle). B. There is accumulation of subretinal fluid with multiple hyperreflective foci in the OPL layer, representing exudates. There is also hyporefective areas in the outer neurosensory retina suggestive of edema (asterisk).

[Abstract:0206]

Effect of vitreomacular traction on the intraocular vascular endothelial growth factor and placental growth factor levels in patients with neovascular age-related macular degeneration

Kenan Sonmez¹, Tugce Horozoglu Ceran²

¹University of Health Sciences, Ankara Etlik City Hospital, Department of Ophthalmology, Ankara, Turkey

²University of Health Sciences, Ankara Diskapi Yildirim Beyazit Training and Research Hospital Department of Ophthalmology, Ankara, Turkey

Purpose: The aim of this study is to investigate the effect of vitreomacular traction (VMT) on intraocular VEGF and PIGF levels in patients with neovascular age-related macular degeneration (nAMD).

Methods: The study group consisted of 10 patients opting for pars plana vitrectomy (PPV) or pneumatic vitreolysis (PVL) due to VMT with nAMD; the control groups included 17 patients opting for PPV or PVL due to VMT, 24 nAMD patients opting for vitrectomy due to posterior capsule rupture during cataract surgery and 19 healthy patients opting for vitrectomy due to posterior capsule rupture during cataract surgery. VEGF and PIGF levels were measured by sandwich-ELISA method in vitreous samples obtained during surgery from all patients participating in the study and in aqueous humor samples from some patients with nAMD.

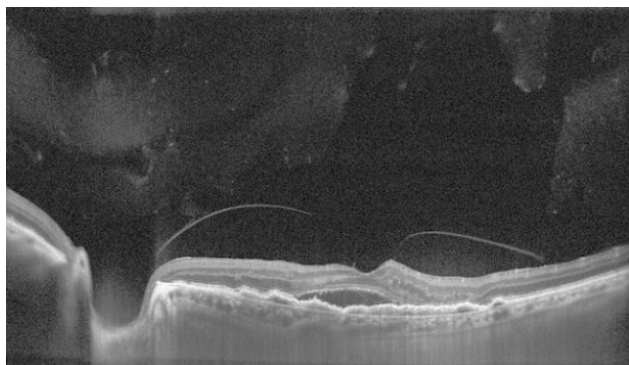
Results: The mean vitreous VEGF level was 34.7±4.98 pg/ml in the study group; 32.36±4.55 pg/ml in the VMT group; 34.02±3.79 pg/ml in the AMD group, and 32.33±2.4pg/ml in the healthy control group having cataract otherwise healthy patients. The mean vitreous PIGF level was 58.92±20.83 pg/ml in the study group; 46.29±3.45pg/ml in the VMT group; 54.64±16.88 pg/ml in the nAMD group; 53.66±19.35 pg/ml in the healthy control group. There was no statistically significant difference among the groups when the vitreous VEGF and PIGF levels were examined ($p>0.05$ and $p>0.05$, respectively). Humor aqueous VEGF and PIGF levels were found to be significantly higher than vitreous levels ($p=0.005$ and $p=0.005$, respectively).

Conclusion: Vitreous VEGF and PIGF levels having not been increased in both VMT+nAMD and VMT cases may suggest that their coexistence may be more likely due to chronic inflammation. In addition, the fact that the aqueous humour

PIGF and VEGF levels are significantly higher than the levels in the vitreous may suggest the role of plasma angiogenic factors in the development of CNV.

Keywords: neovascular type age-related macular degeneration, vascular endothelial growth factor, vitreomacular traction

Figure 1



OCT image of an eye with CNV shows subretinal fluid and shallow irregular PED associated with vitreomacular traction.

[Abstract:0207]

Foveal displacement and metamorphopsia after successful macular surgery

Remzi Avcı, Sami Yılmaz, Ayşegül Mavi Yıldız
Ophthalmology department, Retina eye hospital, Bursa-Türkiye

Purpose: We aimed to compare conventional 360° internal limiting membrane (ILM) peeling and temporal inverted ILM flap technique with regard to postoperative foveal displacement and metamorphopsia.

Methods: Patients who underwent 23 G vitrectomy with either 360° ILM peeling (Group 1) or temporal inverted ILM technique (Group 2) for idiopathic macular hole with a minimum follow up of 12 months were included. The metamorphopsia rates and distances between fovea and 3 retinal landmarks were compared on MultiColor SLO and near-infrared reflectance images. In addition, papillofoveal distance was measured on B-scan optical coherence tomography (OCT).

Results: A total of 57 eyes were recruited (Group 1, n = 25; Group 2, n = 32). The visual acuity at month-1 was significantly higher in Group 2 than Group 1 (p = .007). A significant postoperative foveal displacement towards the disc was observed in Group 1 and Group 2 (p < .001 and p = .002 respectively). Shortening of the papillofoveal distance was greater in Group 1 than Group 2 at all postoperative visits (p < .05 for all). Furthermore, significant changes in papillofoveal distance continued until 6 months in Group 1 (p < .05 for all), whereas no significant changes occurred in Group 2 after month-1 (p > .05 for all). The complaints of metamorphopsia were significantly higher in Group 1 (n = 18/25) compared with Group 2 (n = 10/32) (p = .002).

Conclusion: Temporal inverted ILM flap appear to be superior to 360° ILM peeling with regard to faster visual rehabilitation, lower rates of subjective metamorphopsia and less foveal displacement.

Keywords: Foveal displacement, internal limiting membrane peeling, metamorphopsia

[Abstract:0208]

Update on surgical management of complex retinal detachment associated with retinal capillary hemangioblastoma in Von Hippel-Lindau disease

Remzi Avcı, Ayşegül Mavi Yıldız, Sami Yılmaz
Ophthalmology department, Retina eye hospital, Bursa-Türkiye

Purpose: The aim of our study was to assess results of vitreoretinal surgery with excision of retinal capillary hemangioblastomas in von Hippel-Lindau (VHL) disease.

Methods: This retrospective, study included 24 consecutive eyes who underwent 23 G vitrectomy and tumor resection for complex retinal detachment (RD) associated with RCHs between January 2001 and January 2022. Primary outcome measures were anatomic success rate and final visual acuity (VA).

Results: The mean age was 32.04±12.08 (range 12-58) years and mean follow up was 20.7±12.68 (range 4-48) months. Of the patients, 33.3% (n=8/24) got unilateral onset and 66.6% (n=16/24), suffered bilaterally. All of the patients had exudative retinal detachment, 75% (n=18/24) also had severe proliferative vitreoretinopathy. Of the patients/detachments; 45.8% (n=11/24) were total. All patients underwent 23 G pars plana vitrectomy, tumor resection and endolaser photocoagulation. In addition, relaxing retinectomy (n=8/24) and proliferative membrane removal (n=18/24) was performed if needed. Silicone oil was used in 9 cases, 14% C3F8 gas was used in 13 cases and air tamponade was used in 2 cases. Visual acuity improved in 19 patients (mean 0.58±0.84 LogMAR; range -1.0/2.6), remained stable at hand motion, perception in 3 patient and decreased in 2 patients due to recurrent tractional RD. No intraoperative complications occurred.

Conclusion: Vitrectomy with RCH excision is a safe and effective method for the treatment of large tumors complicated with exudative and/or tractional retinal detachment. Surgical resection of large retinal hemangioblastomas and complete removal of proliferative membranes with limited retinectomy when necessary are the most important points of surgery.

Keywords: Retinal capillary hemangioblastoma, Complex retinal detachment, Tumor resection surgery

[Abstract:0211]**Atypical central serous chorioretinopathy in adolescents using oral contraceptives**

Sevval Efe, Hakan Koc

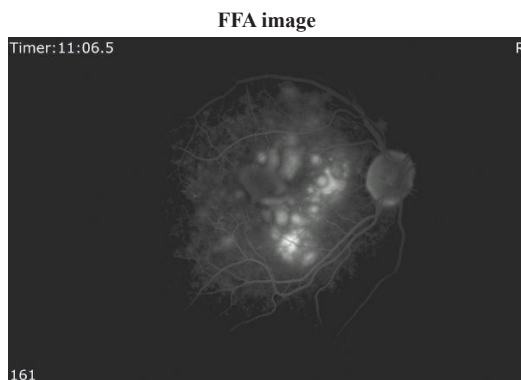
Ophthalmology Department, Giresun University, Giresun, Turkey

A 17-year-old female patient came to our clinic complaining that for three days she had been seeing a yellow halo in front of her right eye.

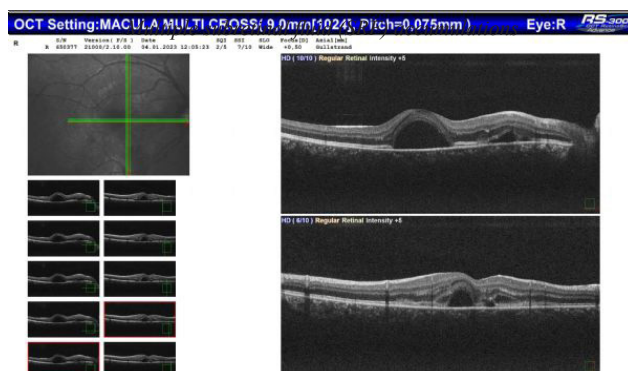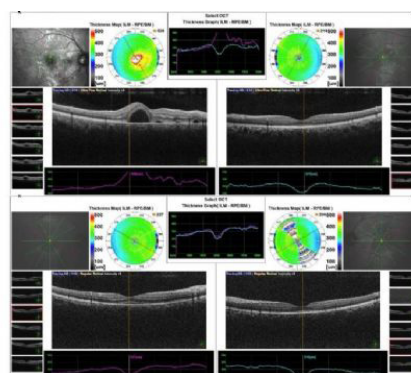
She did not have any history of systemic or ophthalmic diseases. She recently started using oral contraceptive pill (OCP) for her ovarian cyst. She was using 2 mg siproteron asetat ve 0,035 mg etinilestradiol oral tablet once a day for one month. Other than that she was not taking any other medications.

Initial best-corrected visual acuity was 5 metres counting fingers in the right eye and 1.0 in the left eye. Anterior segment examination was normal in both eyes. Fundus examination of the right eye revealed a normal coloration of the optic nerve and retinal elevation at the fovea. And some subretinal fluid images in some other locations in the posterior pole in the right eye. Fundus examination of the left eye was normal. Right eye OCT showed an accumulation of subretinal fluid at the fovea and other multiple subretinal fluid spots. FA showed active points of leakage at the fovea and other multiple locations which are near to the inferior temporal arcade in the right eye. There were extra-macular leaking sides. Left eye OCT and FA findings was normal. Based on these findings the patient was diagnosed with atypical central serous chorioretinopathy (CSC). We decided to stop OCP intake immediately and observe the patient. Two weeks later her initial best-corrected visual acuity was 1.0 in the right eye. And subretinal fluids in the OCT were decreased. Atypical CSC has been described in women with a history of taking corticosteroids and multiple spots of subretinal fluid. Discontinuation of the oral contraceptive pill (OCP) in atypical CSC helped in obliteration of RPE leaks and retinal reattachment in the eye, and improvements in VA was observed.

Keywords: Atypical, CSCR, Oralcontraceptivepill



FA showed active points of leakage at the fovea and other multiple locations which are near to the inferior temporal arcade in the right eye.

Macula OCT**Macula OCT during oral contraceptive use / Macula OCT after discontinuation of oral contraceptive therapy****[Abstract:0213]****Smartphone application links severity of retinopathy of prematurity to early motor behavior in a cohort of high-risk preterm infants**

Michael Blair, Sarah Hilkert Rodriguez

Department of Ophthalmology and Visual Science, Pritzker School of Medicine, University of Chicago, Chicago, USA

Purpose: To evaluate the General Movement Assessment (GMA) with the Motor Optimality Score-Revised (MOS-R) as a neurodevelopmental marker in infants with retinopathy of prematurity (ROP).

Methods: Infants screened prospectively for ROP were evaluated at 3 months' post-term age using a smartphone application to complete the GMA and MOS-R. Results were analyzed by ROP severity.

Results: Of 105 enrolled infants, 83 completed the study. Of these, 54 (65%) had any ROP, 32 (39%) had severe ROP, and 13 (16%) had type 1 ROP. The proportion with aberrant GMA was significantly higher in infants with severe ROP (14/32 [44%]) compared with infants who had milder ROP

(8/51 [16%]; $P = 0.006$). Of those with severe ROP, there was no significant difference comparing infants with type 1 ROP treated with bevacizumab (7/13 [54%]) to infants with type 2 ROP without treatment (7/19 [37%]; $P = 0.47$). Although the presence of any ROP, stage of ROP, and severe ROP each predicted lower MOS-R scores on univariate analyses, only severe bronchopulmonary dysplasia and markers of brain injury remained significant in the multivariate analysis.

Conclusion: The GMA was a convenient, short-term method of data collection with low attrition. Although severe ROP initially appeared linked to poor early motor scores, this association is likely confounded by neurological and respiratory complications, which frequently accompany severe ROP.

Keywords: ROP, neurodevelopment, General Movement Assessment

[Abstract:0214]

A mysterious case of retinal detachment- is it really rhegmatogenous?

Katarzyna Chwiejczak

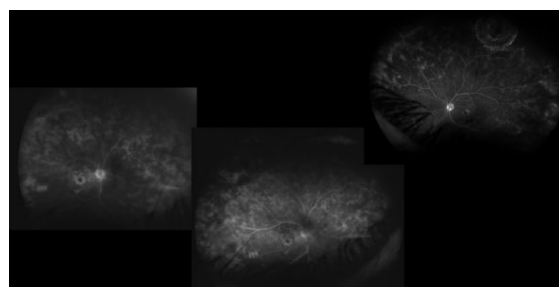
Sheffield Teaching Hospitals NHS FT, The University of Sydney

Case presentation: A 47-year old male with no previous ophthalmic or medical history presented in July 2022 with 4 day history of loss of vision in the right eye (RE). His best corrected visual acuity (BCVA) was Hand movements in the RE and 0.6 LogMAR in the left eye (LE) intraocular pressure: RE 5mmHg, LE 21mmHg. Additionally, in the RE: AC cells ++ and flare ++ and mild phacodonesis. In the RE total macula off retinal detachment (RD) with retinal tears was found, in the LE horse-shoe tears. The left eye underwent laser retinopexy and RE-pars plana vitrectomy (ppV), laser, cryotherapy. Intraoperatively unusual retinal appearance of was noted with schitic changes and ghost vessels and silicone oil was used as a tamponade. Despite initial successful attachment, RD recurred under oil without obvious tears or proliferative vitreoretinopathy (PVR). Fluorescein angiography revealed bilateral vasculitis with leakage, more prominent on the right side. No obvious association was identified. He was treated with topical, periorbital and oral steroids. The treatment did not improve subretinal fluid. Second surgery (ppV, laser, fluid drainage via retinotomy, laser, oil tamponade) was performed with no breaks or PVR found. Despite initial successful attachment and vision 1.3 LogMAR, fluid recurred again despite good oil fill. Mycophenolate Mofetil was started to preserve the left eye.

Conclusion: In case of failed RD repair with no obvious reason exudative detachment should be considered and combined aetiology (rhegmatogenous and exudative) is possible. In such cases prognosis is guarded and further surgery does not guarantee success, especially if the underlying inflammatory condition is not controlled

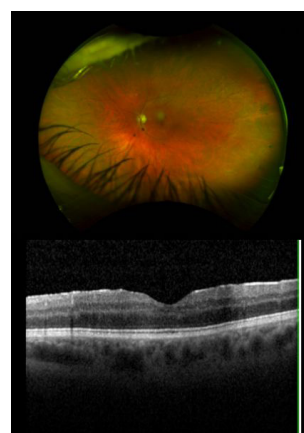
Keywords: exudative retinal detachment, vasculitis, vitrectomy

Fluorescein angiography

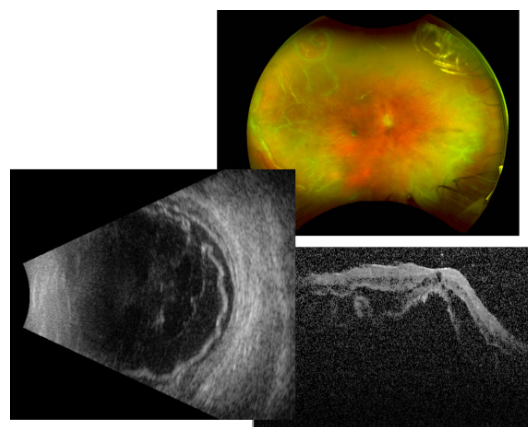


RE and LE wide field images

Left eye preoperatively



Wide field image and macular OCT scan of the LE
Right eye preoperatively

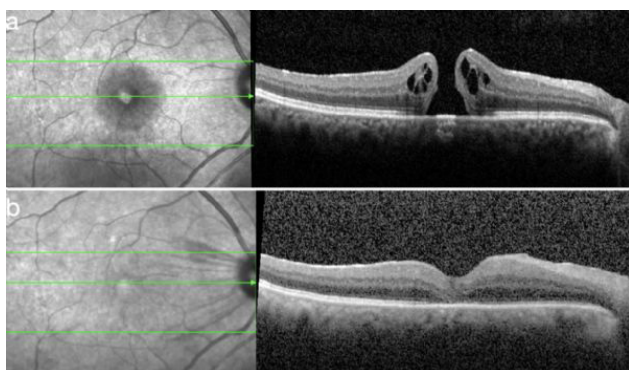


From the top: Wide field image showing total retinal detachment with retinal schisis and ghost vessels Ultrasound confirming retinal detachment and a retinal tear OCT subretinal fluid and macular oedema

[Abstract:0219]**A New Finishing Touch For The Temporal Inverted Internal Limiting Membrane Flap Technique**Ecem Onder Tokuc¹, Sevim Ayca Seyyar², Levent Karabas¹¹Kocaeli University School of Medicine, Department of Ophthalmology²Gaziantep University School of Medicine, Department of Ophthalmology

The temporal inverted internal limiting membrane (ILM) flap technique was developed in an effort to improve vitreoretinal surgery for large macular holes (MH). However, in addition to the difficulty of the surgical procedure, the main concern is the displacement of the ILM flap due to small fluid leakage into the posterior pole, even in the short time required to close the sclerotomies after fluid-air exchange. Here, a new approach to the temporal inverted ILM flap technique is described. In this approach, when the ILM flap is inverted over the MH, a closed-ended ILM forceps is gently pressed over the fold edge and passed over (just like folding a paper in half). Thus, it can be seen that the minimal fluid leaking into the posterior pole ventilates the free edge of the flap, but the force formed along the fold edge prevents the flap from being aired. In cases where the standard temporal inverted ILM flap technique is applied, it can be thought that this new finishing touch will increase the postoperative stability of the flap.

Keywords: inverted internal limiting membrane flap technique; macular hole; vitrectomy

Figure 1.

A 53-year-old woman developed a macular hole in the right eye. Preoperative optical coherence tomography image shows a macular hole with elevated edges and intraretinal cystic spaces (a). The postoperative image shows a closed macular hole (b).

[Abstract:0220]**Repair with two ILM flaps in a patient with optic disc pit maculopathy who developed a full-thickness macular hole at the first surgery**

Semra Tiryaki Demir, Turgay Uçak, Mehmet Egemen Karataş, Oğuz Kaan Kutucu

Department of Ophthalmology, Sisli Hamidiye Etfal Training and Research Hospital, University of Health Sciences, Istanbul, Turkey

Purpose: To report the effect of repair with two ILM flaps on visual and anatomical success in a patient with optic disc pit maculopathy who developed a full-thickness macular hole in the first operation.

Case presentation: A 28-year-old female patient was admitted to our clinic with the complaint of loss of vision in her left eye for about 2 months. The patient's visual acuity was 20/20 in the right eye and counting fingers at 1 meter in the left eye. Biomicroscopic examination was normal. Fundus examination revealed optic disc pit maculopathy in the left eye (Figure 1). The patient underwent pars plana vitrectomy and C3F8 gas injection in the first surgery. In the 2nd month follow-up examination of the patient, full thickness macular hole was observed and reoperation was recommended (Figure 2). In the second vitrectomy surgery, two ILM flaps were created from the nasal and temporal aspect of the fovea. The temporal ILM flap was placed over the fovea, the nasal ILM flap was placed over the optic disc pit, and C3F8 gas injection was applied. In the 3rd months after the second surgery, the patient's left eye visual acuity was 20/50. OCT imaging showed that the left eye full-thickness macular hole was closed, and retinoschisis and serous macular detachment regressed (Figure 3).

Conclusion: In cases of optic disc pit maculopathy that develops full thickness macular hole with standard vitrectomy and gas injection, the creation of ILM flaps from the nasal and temporal aspects of the fovea in the second surgery may contribute positively to visual and anatomical success.

Keywords: Full-thickness macular hole, internal limiting membrane (ILM) flap, optic disc pit maculopathy

Figure 1: Preoperative OCT through the fovea showing optic disc pit maculopathy with dome-shaped subretinal fluid with inner and outer retinal layer schisis, and outer lamellar hole.

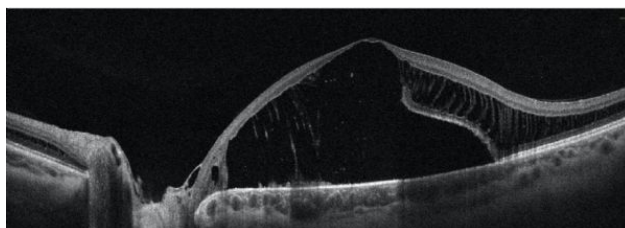


Figure 2: OCT image of full-thickness macular hole that developed in the patient after the first surgery.

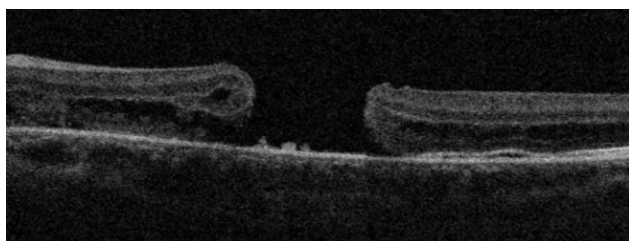
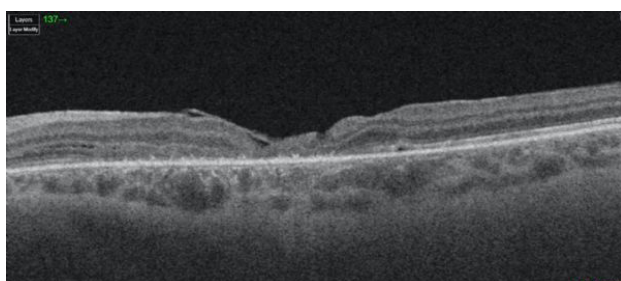


Figure 3: OCT image showing full thickness macular hole closure and regression of retinoschisis and serous macular detachment findings in the patient after the second surgery.



[Abstract:0225]

Reduce the Surgical Time by Not Completely Draining the Subretinal Fluid in Retinal Detachment Cases

Stratos Gotzaridis

My Retina Athens Eye Center, Athens, Greece

A minima presedure for the treatment of uncomplicated RRD is presented. This technique included PPV without the use of PFCL or posterior drainage retinotomies. Instaed postoperative positioning based on the presence or absence of residual subretinal fluid at the end of surgery is required. The results of this study suggest that complete subretinal liquid drainage is not mandatory for all RRD cases treated with PPV and that using PFCL and performing a drainage retinotomy are not essential in eyes with primary RRD and PVR less than grade B. Moreover, postoperative positioning after PPV for uncomplicated RRD based on the presence or absence of residual subretinal fluid at the end of surgery could limit the occurrence of postoperative retinal displacement, while promoting patient compliance.

Keywords: retinal detachment, residual fluid

[Abstract:0238]

Peripheral streak of pre-retinal hemorrhage after vitrectomy completion - A sign of Vitreoschisis

Sangeet Mittal

Thind Eye Hospital, Jalandhar

Vitreoschisis is well documented during surgery for complications of Diabetic Retinopathy. It may lead to incomplete removal of vitreous and postoperative complications. It is important to recognise and remove second membranes during vitrectomy. Several methods like use of Triamcinolone or shiny appearance of retina help to identify these membranes. After completion of vitrectomy, streaks of loose pre-retinal blood are often seen in the equatorial or pre-equatorial retina. Despite repeated attempts the vitrectomy cutter is not able to remove them. This mostly appears innocuous and is often left as such. This presentation describes how these peripheral streaks of blood are not harmless, they are in fact a sign of incomplete vitreous removal. A sheet of vitreous is usually present over these pre-retinal haemorrhages. This sheet is very adherent to underlying retina and cannot be removed using conventional suction techniques. This sheet has to be removed using active suction in anterior to posterior direction. Once this sheet is separated from retina the remaining peripheral blood can be easily removed with vitrectomy cutter. Non removal of this sheet resulted in postoperative complications like ERM and RD. Recurrent vitreous cavity hemorrhage was significantly more in these eyes.

Keywords: Proliferative Diabetic Retinopathy, Vitrectomy, Vitreoschisis

[Abstract:0241]

Dye-assisted occult retinal break detection in retinal detachment surgery

Sema Tamer Kaderli¹, Sabahattin Sül², Elçin Osmanlı², Aylin Karalezli²

¹Muğla Training and Research Hospital, ophthalmology department

²Muğla Sıtkı Kocman University, ophthalmology department

Purpose: To demonstrate that subretinal blue dye injection can be considered a useful tool in finding occult rhegmatogenous tiny retinal breaks in eyes with recurrent retinal detachment (RD).

Method: 11 eyes of 11 patients with recurrent retinal detachment were treated between 2018 and 2021. In all cases, the preoperative and intraoperative internal search did not demonstrate any obvious break or hole. MembraneBlue-Dual (Trypan Blue 0.15% + Brilliant Blue G 0.025% + 4% PEG) was then injected into the subretinal space using a 41-gauge cannula. Perfluorocarbon heavy liquid was then injected into the vitreous cavity displacing the subretinal fluid toward the retina periphery. The eye was rotated such that the dye was vented out of a very tiny break located. After silicone oil removal and absorption of the gas tamponade, retinas

remained attached at six-months follow-up.

Results: All patients had the clinical history of retinal detachment surgery (8 eyes PPV, 3 eyes pneumatic retinopexy) In all eyes, the retinal breaks were identified successfully intraoperatively with subretinal dye technique. In five cases (38.4%) the tears was identified at the posterior edge of the laser retinopexy scar. In four cases (30.7%) the redetachment was attributed to a previously unidentified, unlasered break. In four cases (30.7%) the dye leakage was seen from the edge of a previously lasered break. Postoperative BCVA was 0.8 ± 0.1 logMAR at third month and 0.7 ± 0.1 logMAR at sixth month.

Discussion: Failure to identify a retinal tear during RD surgery is a well-known clinical challenge that may adversely affect the outcome. The detection of retinal tears with dye may be a useful surgical technique.

Keywords: occult retinal break, retinal detachment surgery, rhegmatogenous retinal detachment

[Abstract:0242]

Cystoid macular edema in rod dystrophy

Ivan Fişer

Lexum Eye Clinic Prague

A case report of CME in a 35year old male patient suffering from rod dystrophy.

His left eye affected with CME was treated with non-steroidal anti-inflammatory eyedrops, systemic steroids, acetazolamide, dorzolamide, and dexamethasone intravitreal implant. The recurrence of CME, always appearing after several weeks after its regression, necessitated permanent oral steroid use. Adverse effects of this treatment included cataract, urolithiasis, striae, obstipation, moonface, overweight, neuropathy, and dyspnoea. A parabulbar steroid (triamcinolone) injection brought a two months lasting regression of edema and temporary withdrawal of oral steroids. After the second injection, the benefit lasted one month only with vision drop down to 0.05. We performed vitrectomy with ILM peeling in his left eye, which was followed by an improvement lasting three months. The third parabulbar steroid stabilized the residual edema. After the cataract surgery, the vision improved to 0.5. In the meantime, the CME appeared in the right eye. A parabulbar injection brought an immediate benefit lasting nine months, enabling the withdrawal of oral steroids for one year. The benefit of the second parabulbar steroid lasted almost four months after which the recurrence of CME necessitated oral steroids with many adverse effects. The benefit of the third injection lasted two months only. We started treating his eye using aflibercept intraocular injections. The benefit lasted one month only; the patient had to continue oral steroids. We continued with aflibercept injections in three monthly intervals and in the meantime, we applied parabulbar triamcinolone. After the fifth aflibercept and tenth triamcinolone we switched to brolucizumab. The benefit lasted two to three months and the eleventh parabulbar triamcinolone was applied. The patient is

now treated with brolucizumab applied in bimonthly intervals. He is waiting for the cataract surgery in his right eye, and we think about possible vitrectomy with ILM peeling in his right eye.

Keywords: CME, rod dystrophy, treatment

[Abstract:0243]

Penetrating Ocular Trauma, tips and tricks to expect the unexpected!

Mohamed Moghazy Mahgoub

Ain-shams University Cairo, Egypt

Penetrating ocular trauma always presents challenges during surgery.

This presentation is aimed at showing different types of situations in a variety of penetrating ocular traumas with and without IOFB(s), showing tips and tricks on how to deal with a variety of challenges including visualization, IOFB managements and other challenges related to complications. with this presentation I aim at presenting my way in management of such challenging cases in all aspects while expecting the unexpected in penetrating ocular trauma surgery surprises.

Keywords: Penetrating ocular trauma, IOFB, challenges

[Abstract:0245]

Failed temporal inverted ILM flap in cases of FTMH, what to do next?!

Mohamed Moghazy Mahgoub

Ain-Shams University, Cairo, Egypt.

The aim of this presentation is to highlight the temporal inverted ILM flap technique for different types of FTMH, focusing on failed hole closure and how can those cases be managed on a second surgery and how are the visual and anatomical results after the second intervention.

Keywords: Macular hole, Temporal inverted ILM flap, Failed Hole closure

[Abstract:0248]**A sandwich method of amniotic membrane transplantation in a challenging case of high myopic macular hole associated retinal detachment**

Omer Othman Abdullah¹, Sengul Ozdek Ozdek²,
Ece Ozdemir Zeydanli³

¹Ibnisina Modern Eye and Retina Center

²Gazi University Hospital

³Ankara Retina Clinic

Purpose: To describe a surgical technique using a double-layer amniotic membrane graft to repair a high myopic macular hole (MH) related chronic retinal detachment (RD) with subretinal bands.

Method: Video presentation.

Case: A 3-year-old boy with a diagnosis of Knobloch syndrome presented with tapetoretinal degeneration and macular atrophy in the right eye and a chronic total retinal detachment (RD) with subretinal bands associated with myopic macular hole (MH) in the left eye. A surgery of 360 encircling band followed by a pars plana vitrectomy and subretinal band extraction through a retinotomy was performed. The retinotomy and MH were closed utilizing an amniotic membrane graft and tamponaded by 5000 cs silicone oil. RD recurred in two weeks postoperatively due to contracture of the amnion graft inside the MH. A second intervention included removal of the contracted graft via the MH and transplantation of one amniotic graft prepared in a larger size, placed into the hole and a second one placed over the hole in a sandwich fashion with a 5000cs silicone oil tamponade. Retina stayed reattached with MH closed and the amniotic grafts in place providing ambulatory vision.

Conclusion: Sandwich technique for amniotic membrane graft can be used to provide a strong seal for RD associated with high myopic MH where other procedures fail.

Keywords: Knobloch syndrome, Myopia Macular hole, Retinal detachment

[Abstract:0251]**OCT/OCTA biomarkers in uveitis**

Omer Othman Abdullah

Ibnisina Modern Eye and Retina Center

Uveitis can cause transient or permanent physiological and anatomical changes. For this purpose, OCT and OCTA, as non-invasive investigations, often have specific findings. The disease progression, resolution, and complications can be revealed to aid in shortening the list of differential diagnoses. Some entities have specific patterns that allow for immediate diagnosis. Also, these modalities can predict the risk factors for complications in some types of uveitis.

Keywords: Uveitis, Biomarker, non-invasive investigation

[Abstract:0257]**Retrospective evaluation of neuroretinitis cases in a tertiary care clinic**

Meryem Feyza Çiçek, Burcu Yücekul, Deniz Kumova,
Feyza Önder

Department of Ophthalmology, University of Health Science, Haseki
Training and Research Hospital, Istanbul, Turkey

Purpose: Neuroretinitis is a particular form of optic neuropathy typically characterised by acute unilateral visual loss with optic disc edema and macular exudates. It is unclear whether clinical features vary among forms of neuroretinitis of different etiology. In this study, it was aimed to retrospectively evaluate the demographic, clinical characteristics and treatment results of patients with neuroretinitis.

Methods: the demographic, clinical features, treatment modalities and follow-up features of the neuroretinitis cases that diagnosed in our clinic were evaluated retrospectively.

Results: 58 attacks of 34 patients were evaluated. The mean age was 38.3±12.3 (17-69) years, the F/M ratio was 1,25/1. Twenty five patients had unilateral, 9 had bilateral attacks. 8 patients had recurrent attacks. Initial visual acuity ranged from 0.001(hand motion) to 1.0 (Mean±SD 0.30±0.27), and final visual acuity ranged from 0.01 to 1.0 (Mean±SD 0.74±0.35). 10 patients were evaluated as idiopathic wheares bartonella, toxo, borrelia and brucella serologies were positive in 9,9,3 and 2 patients respectively. One patient was diagnosed with Behçet disease. Initial visual acuities at the time of attack were 0.43±0.30, 0.33±0.25, 0.33±0.28, 0.28±0.28 in the groups received only antibiotic treatment, antibiotic and oral steroid treatment, pulse steroid and antibiotic treatment, only steroid treatment, respectively. And the final visual acuity after the attack were 0.95±0.09, 0.89±0.23, 0.83±0.24, 0.61±0.49 in this groups respectively.

Conclusion: In cases with optic disc edema and vision loss, careful examination of the macula and papillomacular region, macular optical coherence tomography(OCT), follow-up of fluid or star formation with short-term control examinations in the first 2 weeks are important for the diagnosis of neuroretinitis. We found high rate of infectious etiology in our neuroretinitis cases which underlines the importance of comprehensive research for etiology. Steroid treatment, which is not accompanied by antibiotic therapy, may adversely affect the patient's visual prognosis.

Keywords: Macular Star, Neuroretinitis, Optic Disc Edema

[Abstract:0264]**Strawberry eyes: a case of multiple bilateral orbital masses in an infant**

Josemaria Castro, Gary John Mercado
Manila Doctors Hospital

Orbital tumors in children comprise a variety of pathologies, some of which commonly grow unnoticed until considerable cosmetic concern, compression, visual symptoms, amblyopia, and even irreversible blindness ensue. This is a case of a 6-month old female who had a 2-month history of disseminated papulovesicular rashes consequently involving the periobital and eyelid region with swelling at the upper and lower lids, zygomatic, malar, and temporal regions bilaterally. Ophthalmologic examination grossly showed a prominent forehead with a soft moveable mass at the right frontal region, periorbital and lid swelling with a bilateral epicanthus palpebralis. There was also evident capillary hemangiomas bilaterally. The presence of disseminated papulovesicular lesions warranted a skin punch biopsy and the results were consistent with the diagnosis of Langerhans cell histiocytosis. Langerhans cell histiocytosis is a rare clonal disease resulting in uncontrolled proliferation and accumulation of CD1a and CD207 dendritic cells. These form and deposit in various tissues and organs as manifested in the patient, particularly the skin and cranial bones. Histologically, it shows the characteristic birbeck granules which were present in the skin punch biopsy. It presents with painful bone lesions and rashes similar to the patient. Lesions from Langerhans cell histiocytosis may spontaneously regress or repeatedly reactivate and are sensitive to chemotherapy. The cranial MRI findings support the diagnosis of a disseminated type of Langerhans cell histiocytosis which has not only affected the skin but also metastasized to the bony orbit.

Keywords: orbital, mass, metastasis

[Abstract:0268]**Lasso and other techniques for management of dislocated IOLs**

Dhanashree Ratna
Department of Vitreoretinal Diseases, Sankara Nethralaya, Chennai, India

IOLs dislocate in a bimodal fashion either early or late. Early dislocation following the surgery occurs due to posterior capsular dehiscence whereas a zonular dehiscence leads to a late dislocation often following trauma or chronic uveitis. Dislocated IOLs can pose unique challenges. This presentation focuses on several such unique situations. Several techniques are illustrated using videos. Lasso technique is shown where a completely internal refixation of the IOL is done without externalizing the IOL. A 10-0 prolene suture is fashioned into lasso loops which are passed around the haptics of the IOL in the vitreous cavity using bimanual technique. A cow-hitch technique using Gore Tex suture is also shown for dislocated IOLs. In the bag dislocation where the entire IOL -capsular bag complex dislocates requires a different approach. Here

the needle of the prolene suture can be passed through the capsular bag and the entire complex can be refixed without externalizing or dissecting. A dislocated scleral fixated IOL with eyelets on the haptics can be refixed using Gore Tex suture in a 4 point fixation. All these techniques are shown in videos.

Keywords: Posterior dislocation of IOL, total internal refixation, Lasso

[Abstract:0269]**High-frequency electric current welding with suprachoroidal approach to treat retinal detachment: timing of morphological changes and strength of chorioretinal adhesion**

Andrii Sergiienko¹, Omar Saoud², Mykola Turchyn², Anatoliy Korol³, Mykola Umanets⁴, Goran Petrovski⁵, Goran Petrovski⁶, Lyubomyr Lytvynchuk⁷, Taras Ardan⁸, Knut Stieger⁹, Matus Rehak⁹

¹Ophthalmological Clinic of Professor Sergiienko (Vinnytsia, Ukraine).

²Department of Otorhinolaryngology, Ophthalmology and Neurosurgery, Ternopil National Medical University (Ternopil, Ukraine).

³Department of Histology, Vinnytsia National Pirogov Medical University (Vinnytsia, Ukraine).

⁴Vitreoretinal Department, The Filatov Institute of Eye Diseases and Tissue Therapy (Odessa, Ukraine).

⁵Center for Eye Research, Department of Ophthalmology, Oslo University Hospital and Institute of Clinical Medicine, Faculty of Medicine, University of Oslo (Oslo, Norway).

⁶Department of Ophthalmology, University of Split School of Medicine and University Hospital Centre, Split, Croatia.

⁷Karl Landsteiner Institute (Vienna, Austria).

⁸Institute of Animal Physiology and Genetics, Academy of Sciences, Czech Republic.

⁹Department of Ophthalmology, Justus Liebig University, University Hospital Giessen and Marburg GmbH, Campus Giessen (Giessen, Germany).

Purpose: Chorioretinal adhesions (CRA) are essential in retinal detachment surgery. To evaluate the morphological changes (MC) and CRA strength (CRAS), a high-frequency electric current welding (HFECW) was applied with suprachoroidal approach on experimental animal model to cause CRA.

Methods: For HFECW, a modified generator EK-300M1 with pre-settings (three groups: 10-12 Volts (V), 12-14 V and 14-16 V) was used. Treated eyes were enucleated in 1 hour (h), 3, 7, 14 and 30 days after treatment. A study of the MC of the CRA was performed on 54 (108 eyes) rabbits (32 eyes per group, 12 control eyes); the retina was treated with suprachoroidal approach using 25-gauge tip (treated area diameter/size 0.260 mm/0.053 mm²). Study of CRAS was performed on 52 (104 eyes) rabbits (32 eyes per group, 8 control eyes). CRAS was measured using a biomechanical force elongation tester. The reduction in weight at the time of CRA rupture was registered as a measure for adhesion strength.

Results: The MC showed an instant increase in the CRA in the area of HFECW application, which further strengthened with time. The retina responded by apparent destruction of rods, cones, loss of bipolar, amacrine, horizontal and ganglion

cells, development of cysts and migration of RPEs, while the choroid showed damage and migration of melanocytes. By day 30, a tissue reaction showed a partial cell regeneration and connective tissue degeneration. The study of CRAS showed that after application of 10-12 V at 1 h from treatment with HFECW a CRAS was 8.75% and 25.74% higher than that of 12-14 V and 14-16 V, respectively, and at 1 week it was 10.18% and 9.54% higher than that of 12-14 V and 14-16 V, respectively.

Conclusion: Application of HFECW with suprachoroidal approach can induce an instant CRA, which strengthens within first weeks from surgery. Application of lower electromotive force (10-12 V) showed a higher CRA strength. HFECW with suprachoroidal approach could be an alternative method to treat retinal tears, reducing the need for endotamponade and vitreoretinal surgery.

Keywords: suprachoroidal approach, morphological changes, retinal detachment

[Abstract:0271]

Future of anti-VEGF- Biosimilars and biobetters

Dhanashree Ratna

Department of Vitreoretinal Diseases, Sankara Nethralaya, Chennai, India

Anti-VEGFs are now the gold standard of treatment for many diseases including wet AMD, diabetic retinopathy, and others. But the exorbitant cost of the treatment is a major factor responsible for non-compliance and suboptimal visual results. Biosimilars which are copies of the original molecule can prove to be the saviors owing to their cost-effectiveness and easy availability. Biobetters are better than the original biologic but require more research and development. Very soon numerous biosimilars are expected to get approved for therapeutic use from the US FDA and the EMA. There are several misconceptions in the mind of ophthalmologists and it is believed that biosimilars might not be as effective as the original biologics. It is important that we have in depth knowledge about biosimilars. This presentation will introduce the biosimilars, and elaborate on their manufacturing and regulatory processes. Data from several clinical and real world studies will be presented to show the non-inferiority of biosimilars.

Keywords: anti-VEGF, biosimilars, biologics

[Abstract:0272]

Our Visual and Anatomical Results After Vitrectomy with Subretinal tPA Injection in the Treatment of Submacular Hemorrhage Secondary to Age-Related Macular Degeneration

Serhat Ermiş, Şerife Çiloğlu Hayat, Ece Özal, Murat Karapapak, Yusuf Cem Yılmaz, Hakan Baybora, Sadık Altan Özal
Basaksehir Cam and Sakura City Hospital, Ophthalmology, Istanbul

Purpose: To investigate the results of vitrectomy, subretinal tissue plasminogen activator (tPA) injection, hemorrhage displacement with liquid perfluorocarbon, gas tamponade, and face-down positioning in patients with submacular hemorrhage (SMH) secondary to age-related macular degeneration (AMD).

Methods: The medical records of 8 patients who applied to our clinic with large SMD due to age-related macular degeneration (AMD) and underwent PPV, subretinal tPA injection and gas tamponade between January 2020 and January 2022 were reviewed. Data collected includes preoperative visual acuity (VA), SMH extent and duration, intraoperative and postoperative complications, postoperative anatomical and VA responses, and the need for additional postoperative treatments.

Results: Overall, six patients were male and two patients were female, with a mean (SD) age of 71.75 (6.25) and a mean (SD) follow-up of 16.5 (3.70) months. Preoperative mean VA values were 2.20 (.185). Mean (SD) SMH duration was 7.87 (9.77) days, and mean (SD) SMH coverage was 4.68 (2.49) disc diameter. Complete displacement of hemorrhage occurred in all patients at postoperative 1 month. At 1 month postoperatively, mean SMH coverage was 2.31 (2.18), mean (SD) VA 1.40 (.489), ($P = 0.018$) significantly improved. Additional therapy (anti-vascular endothelial growth factor (anti-VEGF) monotherapy, photodynamic therapy or in combination) was given to all patients during follow-up. Mean (SD) LogMAR VA was 1.112 (.646) at 6 months postoperatively, which was significantly improved from baseline ($P = 0.018$). SMH recurrence was not observed in any of the patients postoperatively. Retinal detachment (RD) developed in one (12.5%) patient after surgery.

Conclusion: Vitrectomy, subretinal tPA injection, replacement of hemorrhage with liquid perfluorocarbon, gas tamponade, and prone positioning were associated with better anatomical and visual outcomes in patients with large hemorrhagic neovascular AMD. The duration and area of SMH and preoperative visual acuity seems to correlate with the success of the relocation.

Keywords: Submacular hemorrhage, Tissue plasminogen activator, Exudative macular degeneration

[Abstract:0273]**Long-term follow-up in the lamellar macular hole without vitrectomy**

Akın Çakır¹, Gülderen Karaca², Gamze Karataş¹,
Mustafa Nuri Elçioğlu¹

¹Department of Ophthalmology, Prof. Dr. Cemil Tascioglu City Hospital, Istanbul, Türkiye

²Department of Ophthalmology, Mus State Hospital, Mus, Türkiye

Purpose: To demonstrate long-term morphological and functional changes in the patients with lamellar macular hole (LMH) without vitrectomy

Methods: The medical records of patients with a diagnosis of LMH in the retina department of Prof. Dr. Cemil Tascioglu City Hospital, who were followed up for at least one year and did not undergo surgical treatment, were retrospectively reviewed. The patients were divided into three groups; degenerative LMH, tractional LMH and mixed LMH. Main outcome measures were best-corrected visual acuity (BCVA), inner diameter of LMH (opening), maximum diameter of LMH, minimum outer retinal thickness (ORT), area of LMH associated epiretinal proliferation (LHEP) and the status of ellipsoid zone (EZ) and external limiting membrane (ELM).

Results: Thirty-nine eyes of 35 patients were included in the study. Mean follow-up was 25.8 ± 13.5 (12-53) months. The mean age was 70.8 ± 11.8 years. The mean minimum ORT was significantly lower in the patients with LHEP than without LHEP both at baseline and at last visit ($p=0.011$ and $p=0.010$; respectively). BCVA decrease was found only in the mixed group, but it was not statistically significant ($p=0.105$). The mean area of LHEP increased statistically significant over time ($p=0.043$ and $p=0.030$; respectively). There was no difference between groups in the mean inner diameter and maximum diameter values, or in intragroup changes over time ($p=0.775$, $p=0.680$, $p=0.407$, $p=0.716$; respectively). In the correlation analysis, BCVA change was found to be negatively correlated with the baseline and final minimum ORT, the presence of LHEP and EZ defect ($r=-0.381$, $p=0.017$; $r=-0.406$, $p=0.010$; $r=0.332$, $p=0.039$; $r=-0.362$, $p=0.023$; respectively).

Conclusion: LMH can remain stable for a very long time. However, the presence of LHEP may be a sign of poor prognosis.

Keywords: Lamellar macular hole, lamellar hole-associated epiretinal proliferation, Optical coherence tomography

[Abstract:0275]**Choroidal vascularity index and iris thickness in bilateral acute iris transillumination**

Pınar Kaya, Anıl Güngör, Yasemin Özdamar Erol
Etlik Şehir Hastanesi, Göz Kliniği, Ankara

Purpose: To investigate the subfoveal choroidal thickness (CT), choroidal vascularity index (CVI), and iris thickness (IT) in bilateral acute iris transillumination (BAIT) and compare with healthy individuals.

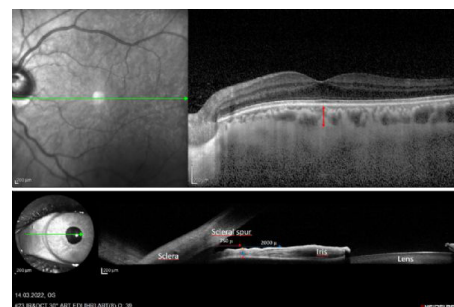Methods: This study included 28 eyes of 14 patients (Group 1) and 30 eyes of 15 healthy individuals (Group 2). Enhanced depth imaging-optical coherence tomography (EDI-OCT) was performed for subfoveal CT. CVI was defined as the proportion of luminal area to the total circumscribed choroidal area and calculated using ImageJ software. Spectral-domain OCT (SD-OCT) in “angle scan” mode was used to evaluate IT. The ciliary zone and pupillary zone were determined using callipers in 750μ and 2000μ from the anterior chamber angle, respectively. The parameters of iris measurement, total, maximum, stromal IT, anterior border layer (ABL), and posterior pigment epithelial layer (PEL) thicknesses were measured after at least 3 months of inactive uveitis period.

Results: There was no significant difference between the groups regarding age and gender ($p=0.086$, $p=0.19$). The best corrected visual acuity was 0.81 ± 0.17 in group 1, 0.99 ± 0.02 in group 2 ($p<0.01$). Posterior synechia was detected in 14 eyes (50%), cataract was detected in 10 eyes (35.7%), and persistent glaucoma in 6 eyes of 3 patients. CT was $225.3 \pm 109.6 \mu$ in group 1, $339.1 \pm 86.8 \mu$ in group 2 ($p<0.01$). The luminal area and total choroidal area were significantly lower in group 1 ($p<0.01$ for both). CVI were 67.9 ± 4.6 for group 1, 67.0 ± 3.9 for group 2 ($p=0.23$). Maximum IT, ABL, and PEL values of the pupillary and ciliary region in the temporal and nasal quadrants were significantly lower in group 1 ($p<0.01$ for all). There was no statistical difference in the total and stromal IT for both temporal and nasal quadrants.

Conclusion: The effects on melanin-containing tissues may occur not only in the iris but also in the choroid of BAIT patients.

Keywords: Bilateral acute iris transillumination, iris thickness, choroidal vascularity index

Figure 1



Enhanced depth imaging-optical coherence tomography (OCT) was performed for subfoveal choroidal thickness. Spectral-domain OCT in “angle scan” mode was used to evaluate iris thickness.

Figure 2

Table 1. Comparison of clinical features of BAIT patients between admission and final visit.

	Admission	Final	P value
Best-corrected visual acuity	0.61±0.23 (0.1-1)	0.81±0.17 (0.4-1)	0.001
Intraocular pressure	27.61±7 (14-39)	15.75±3.7 (10-23)	0.001

Results indicate mean ± standard deviation.
Wilcoxon signed-rank test was used.

Table 2. Clinical features of BAIT patients at the final visit.

	n=28 eyes (%)
Follow-up time (months)	25.7±4.81 (3-72)*
Posterior synechia at the last visit	14 (50%)
Cataract at the last visit	10 (35.7%)
Glaucoma	14 (50%)

*St error: 4.81 (follow-up time)

Table 3. Descriptive and clinic characteristics of groups.

	Group 1- BAIT (n=14 patients)	Group 2 - Control (n=15 patients)	p value
Age (year)	51.71±11.9 (34-69)	45.93±8.4 (33-66)	0.086*
Female (%)	9 (64.3%)	7 (46.7%)	0.19**
Best-corrected visual acuity	0.81±0.17 (0.4-1)	0.99±0.02 (0.9-1)	<0.01*
Intraocular pressure (mmHg)	15.75±3.7 (10-23)	13.97±2.5 (10-18)	0.09*

Results indicate mean ± standard deviation (minimum-maximum).
Statistically significant

*Mann Whitney U was used. **Fisher exact test was used.

Tables 1-3

Figure 3

Table 4. Comparison of iris and choroid thickness, and choroidal vascularity index between groups.

	Group 1 (baist)	Group 2 (control)	p value
Choroidal thickness	225.3±109.6 (76-488)	339.1±86.8 (201-510)	<0.01
Choroidal vascularity index	67.9±4.6 (59.3-78)	67.0±3.9 (61.8-80)	0.23
LA	211518.60±49523.9 (111385.4-285786.5)	318853.3±51307 (229288.8-476856.8)	<0.01
CA	311182.5±67347.4 (187537.7-434124.2)	467293.7±79934.2 (334008.8-730115.4)	<0.01
n750_ABL	43,25±12.2 (31-76)	52,6±13.4 (31-90)	=0.01
n750_stroma	276,0±80.8 (159-406)	271,1±55.4 (189-404)	0.972
n750_PEL	45,19±13,61 (13-76)	74,27±15,7 (47-125)	<0.01
n750_total	361,4±86,9 (231-502)	398,0±58,8 (313-558)	0.146
n2000_ABL	37,53±13,0 (25-72)	68,0±11,3 (47-88)	<0.01
n2000_stroma	278,5±77,1 (138-363)	305,6±96,2 (159-538)	0.721
n2000_PEL	38,6±13,3 (25-72)	68,0±11,3 (47-88)	<0.01
n2000_total	351,8±87,7 (194-470)	427,8±105,8 (252-701)	0.06
Q ₀₀₈₅	473,8±55,2 (376-567)	567,6±80 (413-744)	<0.01
t750_ABL	54,7±12,4 (31-75)	71,5±14,2 (44-101)	0.002
t750_stroma	267,6±56,2 (156-350)	268,4±72,7 (122-410)	0.845
t750_PEL	54,2±12,1 (31-75)	71,5±14,2 (44-101)	<0.01
t750_total	363,6±52,7 (263-438)	392,0±75,0 (237-538)	0.140
t2000_ABL	45,2±12,4 (25-75)	66,5±10,8 (41-94)	<0.01
t2000_stroma	283,2±81,4 (169-463)	299,4±86,0 (197-613)	0.460
t2000_PEL	44,8±12,1 (25-75)	66,0±1,08 (41-94)	<0.01
t2000_total	363,8±84,9 (250-539)	420,1±86,0 (312-723)	0.024
t ₀₀₈₅	515,7±90,6 (353-713)	573,1±87,0 (417-807)	0.025

Results indicate mean ± standard deviation. Mann Whitney U test was used.

Table 4

[Abstract:0277]

Visual and refractive outcomes of an opacified multifocal intraocular lens exchange. Can the bag be trusted?

Abbas Fahem¹, Amr Wassef¹, Anthony Shinton¹, Steve Lash²

¹University Hospital Southampton

²University Hospital Southampton; Optegra Eye Hospital Hampshire, UK

Purpose: To assess the visual, refractive and safety outcomes of an opacified multifocal intraocular lens (IOL) exchange using two different secondary IOL implant techniques.

Methods: Consecutive retrospective series of 88 eyes (82 patients) with opacified multifocal IOL underwent IOL exchange between March 2017 and April 2022 carried out by a single surgeon in two centres. Outcome measures included are mean postoperative best corrected visual acuity (BCVA), refractive accuracy, intraoperative and postoperative complications. All patients received monofocal IOL either implanted in the capsular bag or using scleral haptic fixation (SHF) lens using Modified Yamane Technique in case of capsular bag instability.

Results: 88 eyes in 82 patients underwent explant of an opacified Lentis Mplus multifocal IOL. The mean interval after the primary surgery was 8 years. 59 eyes (67%) went on to have SHF lens whilst 29 eyes (33%) had their secondary IOL implanted in the bag. All patients in the SHF group had combined pars plana vitrectomy done. The mean BCVA postoperatively in the SHF group was 76 ±12 ETDRS letters and 78 ±6 ETDRS Letters in the capsular bag implanted IOL group. The mean predicted refractive error for the SHF group was 0.56D ±0.9D and -0.008D ±0.7D in the capsular bag implanted IOL group. Mean follow up duration was 10 months in the SHF group and 4.8 months in the capsular bag group. The most common encountered post-operative complication was CMO 11/59 18% in the SHF group. No other significant differences in complication rates between both groups.

Conclusion: The secondary IOL choice in cases of opacified multifocal IOL largely determined by the integrity of the capsular bag. Where the capsular bag is compromised, SHF lens represent an effective and safe method. Both groups achieved improvement in their visual activity with low intraoperative and postoperative complication rates.

Keywords: IOL Exchange, scleral haptic fixation, multicocal IOL

[Abstract:0279]**Management of Retinal Detachment with Coexistent Macular Hole by Submacular Placement of Retinal Autograft**

Levent Karabas¹, Ecem Onder Tokuc¹, Sevim Ayca Seyyar², Ece Basaran Emengen¹

¹Kocaeli University School of Medicine, Department of Ophthalmology

²Gaziantep University School of Medicine, Department of Ophthalmology

The aim of this report is to describe the technique of submacular autologous neurosensory retinal transplantation in patients with retinal detachment with a coexistent macular hole. Initially, 23G pars plana vitrectomy was performed. Subsequently, a peripheral vitrectomy under indentation was carried out. If necessary, 360-degree broad internal limiting membrane (ILM) peeling was performed after ILM staining. An autologous neurosensory retinal patch, which is larger than the macular hole diameter, was released from the upper nasal quadrant for the left eye and the upper temporal quadrant for the right eye. The retinal tissue was prehended by 23G microforceps and then inserted under the macular hole. Fluid perfluorocarbon (PFCL) was injected and the retina was re-attached. A subfoveal autologous neurosensory retinal patch was repositioned in the center of the macular hole with gentle manipulation under PFCL, if necessary. After the fluid-air exchange, laser retinopexy was performed for the peripheral tears. Subsequently, 5000 cs silicone oil-PFC exchange was also performed. The outcome of this technique was evaluated in this technical report.

Keywords: macular hole, retinal detachment, autologous retinal graft

[Abstract:0281]**Impact of Three-Dimensional Heads-Up Display on Ergonomics, Surgical Performance and Teaching in VitreoRetinal Surgery in a Tertiary Eye Care Center**

Yassine Malek, Shamil Louaya

Ophthalmology Department Agadir Military Hospital, Souss Massa University Hospital, Ibn Zhor University, Agadir, Morocco

Purpose: To assess the impact of three dimensional head's up display on surgical performance, ergonomics and teaching in Vitreoretinal Surgery

Settings: Ophthalmology Department, Oued Eddahab Agadir Military Hospital, Agadir, Morocco.

Methods: A combination of a retrospective comparative study between cases operated with three dimensional head's up display system (3D HUD) (N=24) (NGENUITY; Alcon Inc., Fort Worth, Texas, USA) and Standard operating Microscope (SOM) (N=35) (Lumera 700, Zeiss Meditech, Germany), and a questionnaire was done. Rates of anatomical success, duration of surgery, peroperative complications and Postoperative

best corrected visual acuity were compared in both groups. Questionnaire consisted in evaluating subjective satisfaction of Surgeons, Assistants and trainees, regarding ergonomics, quality of image, depth of field, simplicity, teaching, and overall satisfaction on a scale of 1 to 10.

Results: In the comparative study, both groups were comparable in terms of Demographic Data. Final Anatomical success, in terms of Retinal Reattachment, Macular Hole closure, rebleeding were comparable in both groups. Surgery Duration was significantly longer in 3D HUD group for Rhegmatogenous retinal detachment ($p=0,04$), Tractional Retinal Detachment ($p=0,01$). Rates of complications were significantly higher in 3D HUD group with 3 retinal touches ($p=0,001$). In the questionnaire, All the surgeons, assistants and trainees satisfaction scores were higher in the 3D HUD Group.

Discussion: This study demonstrates the comparable efficacy of 3D HUD and SOM for various VitreoRetinal Surgeries in term of anatomical success. However, many surgeries remain longer in 3D HUD, and rate of peroperative complications Higher, probably due to a learning curve. Overall satisfaction regarding ergonomics, quality of viewing, teaching and learning are in favor of 3D HUD.

Conclusion: 3D HUD remains a remarkable tool for teaching, and improving Ergonomics in VitreoRetinal Surgery. However a certain learning curve is necessary.

Keywords: 3D HUD, Ngenuity, Ergonomics

[Abstract:0287]**Prognostic impact of the vitreomacular interface in the treatment of neovascular age-related macular degeneration**

Puren Isik¹, Selcuk Sizmaz¹, Ebru Esen¹, Nihal Demircan¹, Hülya Binokay²

¹Çukurova University, Department of Ophthalmology, Adana, Türkiye

²Çukurova University, Department of Biostatistics, Adana, Türkiye

Purpose: To evaluate the effect of the vitreomacular interface (VMI) on outcomes of anti-vascular endothelial growth factor therapy (anti-VEGF) in patients with neovascular age-related macular degeneration (n-AMD).

Methods: A total of 633 patients who were diagnosed with n-AMD between 2014 and 2021 were retrospectively reviewed. A total of 171 eyes of 141 patients with treatment-naïve n-AMD were included. All patients received three monthly loading doses of intravitreal anti-VEGF injections followed by a pro-re-nata treatment regimen. VMI features were identified as follows: the presence of posterior vitreous detachment (PVD), vitreomacular adhesion/vitreomacular traction (VMA/VMT), and epiretinal membrane (ERM). Treatment efficacy was evaluated as the change in best corrected visual acuity (BCVA, logMAR), central foveal thickness (CFT) and the presence of subretinal or intraretinal fluid, scar formation,

and atrophy. The impact of the VMI features on outcome parameters was evaluated.

Results: The mean follow-up period was 45.4±22.5 months (12-96). The mean number of intravitreal injections was 10.8±6.7 (4-33). Ninety-two (53.8%) eyes had complete PVD, 22 (12.2%) eyes had incomplete PVD, 23 (13.4%) eyes had persistent VMA/VMT, 34 (19.8%) eyes had ERM at the last visit. The mean follow-up time was similar between groups ($p=0.105$). BCVA gain was found to be lower in eyes with ERM compared to other groups ($p=0.002$). There was no significant difference between the groups in the mean CFT change ($p=0.794$). According to OCT findings, the rate of scarring or atrophy was highest ($p=0.04$), while the rate of exudation was lowest in eyes with ERM ($p=0.042$). The mean number of injections in eyes with PVD was significantly higher than in eyes with VMA/VMT and ERM (12 vs 8.9, 9.1, respectively, $p=0.023$).

Conclusion: The presence of ERM in eyes with n-AMD can be predicted to be associated with poor anatomical and visual prognosis, regardless of anti-VEGF treatment intensity.

Keywords: Vitreomacular interface, neovascular age-related macular degeneration, anti-vascular endothelial growth factor

[Abstract:0288]

Reattachment Rate with Pneumatic Retinopexy for Rhegmatogenous Retinal Detachment with a Single Break in Detached Retina

Aurora Pecaku¹, Isabela Martins Melo¹, Reut Shor¹, Roxane J. Hillier², Rajeev H. Muni³

¹Department of Ophthalmology and Vision Sciences, University of Toronto, Toronto, Canada; ²St Michael's Hospital, Toronto, Canada

³Newcastle Eye Centre, Royal Victoria Infirmary, Newcastle upon Tyne, United Kingdom

³Department of Ophthalmology and Vision Sciences, University of Toronto, Toronto, Canada; ²St. Michael's Hospital, Toronto, Canada; ¹Kensington Eye Institute, Toronto, Canada

Purpose: To assess reattachment rate with pneumatic retinopexy (PnR) for primary rhegmatogenous retinal detachment (RRD) in patients meeting PIVOT criteria with a single break in detached retina.

Methods: A post hoc analysis of two prospective clinical trials that included primary RRDs referred to St. Michael's Hospital, Toronto, Canada between August 2012-April 2021. Inclusion criteria included patients with a single break in detached retina and any number of breaks or lattice degeneration elsewhere, who also met PIVOT trial criteria (Hillier et al. 2018).

Results: 108 patients were included. All had a minimum of 3 months of follow-up and 99%(107/108) had a one-year follow-up. 32.4% (35/108) were females with a mean age of 62(±10.0) years and 51.8%(56/108) were phakic. 75.9%(82/108) of RRDs were fovea-off at presentation. Primary anatomic reattachment rates (PARRs) at postoperative months 3 and 12 were 86.1%(93/108) and 85%(91/107) respectively. Mean logMar BCVA was 0.34(±0.4) at 3-months and 0.2(±0.3) at the 12-months post-operatively.

The mean extent of RRD was 2.3±1 and 2±1 quadrants in patients who had primary reattachment with PnR versus those who required a subsequent intervention. 40%(6/15) of patients who failed PnR had additional breaks visualized at the time of pars plana vitrectomy. PARR was 89.5%(77/86) in patients with no additional pathology in the attached retina.

Conclusions: PARR in patients meeting PIVOT criteria was 80.8% in the randomized trial. In this prospective cohort study, PARR was 86.1% at 3 months and 85% at 12 months when only patients with a single break in the detached retina and any number of breaks or lattice degeneration in the attached retina were included. PARR increased to 89.5% in patients with no additional pathology in the attached retina. Pneumatic retinopexy provides long-term reattachment in a large proportion of patients with a single break in the detached retina who meet PIVOT trial criteria.

Keywords: Rhegmatogenous Retinal Detachment(RRD), Pneumatic Retinopexy(PnR), Primary Anatomic Reattachment Rate(PARR)

[Abstract:0291]

The place of a new Wide-Field Swept Source Optical Coherence Tomography Angiography Canon Xephilio in retinal diseases

Ali Erginay, Aude Couturier, Ramin Tadayoni

Ophthalmology Department, Lariboisiere Hospital, APHP, Paris University

Purpose: To investigate the ability and the benefit of a recently developed, Canon Xephilio WF-SSOCT-S1 for detecting peripheral lesions in retinal diseases.

Methods: A total of 120 patients (215 eyes) with different pathologies (diabetic retinopathy, branch vein occlusion, Coat's disease, occlusive vasculitis, high myopia, retinal detachment, tumors ...) were included in the study. All patients were examined by Canon Xephilio with 23mm radial or cross line B-scans and mosaic of five 23x20mm OCTA scans. Patients were also imaged at the same visit using UWF Optos California or Zeiss PlexElite 2.0 (mosaic of five 12x12mm OCTA scans and 16mm B-scan cross-line). We compared two imaging systems with Xephilio.

Results: With Xephilio 23x20 mm image corresponds to 80° viewing angle. And the mosaic of 5 images which is approximately up to 31x27mm is larger than the mosaic obtained with five 12x12mm PlexElite and covers a large part of 200° California. So Xephilio allows us to explore more peripheral retina..

Conclusions: WF Xephilio OCTA is clinically useful in detecting peripheral retinal pathologies. With future improvements and upgrades in both hardware and software, it will be a mainstream device in our daily practice.

Keywords: Imaging, Ultra wide-field OCTA, retina

[Abstract:0296]**Foveal sparing ILM peeling in the treatment of the tractional diabetic macular edema**

Bernardete Bela Pessoa, João Melo Beirão, Angelina Meireles
 Centro Hospitalar Universitário do Porto - CHUPorto, Instituto de
 Ciências Biomédicas Abel Salazar - Universidade do Porto (ICBAS-UP)

Background: The rationale for vitrectomy with ILM peeling in tractional or non-tractional DME is to eliminate all potential tractional, inflammatory factors and the scaffold for epiretinal membrane recurrence. Nevertheless, macular atrophy or ganglion cell layer thinning with worse functional results can be a secondary effect of this approach, and both of these conditions are also made worse by diabetic macular neurodegeneration, which is linked to ganglion cell layer loss as well.

Purpose: To explore the effect of vitrectomy with foveal sparing ILM peeling in the treatment of tractional diabetic macular edema (tDME).

Methods: A pilot prospective, consecutive, observational study of 3 tDME cases. Best Corrected Visual Acuity (BCVA) in ETDRS letters and central macular thickness (CMT) and other OCT anatomical parameters were evaluated at baseline, 1st, 3rd and 6th month of follow-up. Baseline characteristics and safety outcomes were also analysed.

Results: The 3 cases were from type 2 diabetics with a mean age of 75 (± 6.6) years, a mean DME duration of 20.3 months and severe non-proliferative diabetic retinopathy. All the eyes were phakic. In two cases combined surgery was performed. Through the predefined timepoints, the mean CMT and BCVA were 498.0, 602.7, 559.7, 591.7 (± 117.2 , 184.5, 127.9, 123.5 μ m) and 55, 48.3, 56.7, 58.3 (± 4.6 , 10.4, 5.8, 7.6), respectively. During the follow-up period, a marked distortion of inner retina correlated with the ILM foveal shrinkage was observed. Two eyes were treatment naïve and one had previous macular LASER, pan-retinal photocoagulation and intravitreal injections. No other safety occurrences were observed.

Conclusion: Although macular atrophy and GCL thinning may be aggravated with vitrectomy and ILM peeling procedures in tractional diabetic macular edema, the foveal sparing ILM peeling technique seems to potentiate retinal distortion induced by the shrinkage of the residual ILM, preventing edema regression.

Keywords: Foveal sparing internal limiting membrane peeling, vitrectomy, diabetic macular edema

[Abstract:0298]**Modified Yamane intrascleral haptic fixation results from a tertiary referral clinic**

Halit Eren Erdem, Aslan Aykut, Mehmet Orkun Sevik, Özlem Şahin
 Department of Ophthalmology, School of Medicine, Marmara University, Istanbul, Turkey

Purpose: To assess the safety and success of sutureless intrascleral haptic fixation, Modified Yamane Intrascleral Haptic Fixation (MYIHF) technic in our clinic.

Method: Eighteen eyes of 18 patients who had MYIHF between January 2019 and June 2022 for aphakia and IOL dislocation were analyzed retrospectively. The main incision was made with a 2.8 mm blade, and an Eyecryl Plus Three Piece IOL was inserted in the posterior chamber. Two reciprocal scleral tunnels of 1.5 mm in length were created 1.5 mm away from the limbus with a 27 gauge needle. Then, IOL haptics were retrieved and externalized. The tip of the haptics was cauterized and buried in the scleral tunnels.

Results: The median (IQR) age was 65.5 (56.7-74.2). The mean follow-up time was 9.3 \pm 4.6 (range, 6-20) months. The mean preoperative, postoperative 1st, 3rd and 6th BCVA was 1.1 \pm 0.87, 0.83 \pm 0.89, 0.80 \pm 0.89, and 0.90 \pm 0.99 logMAR, respectively (p=0.04). None of the patients had haptic exposure, tilted IOL, or unexpected astigmatism. Postoperative 6th month SE assessment showed 11 (61.1%) patients with less than ± 0.50 dioptre, 2 (11.1%) patients between ± 0.50 and ± 1.00 dioptre, and 4 (22.2%) patients higher than ± 1.00 dioptre. In the postoperative 1st month, none of the patients had ocular discomfort. In the postoperative six-month follow-up, 2 (11.1%) patients had pseudophakic macular edema, and 1 (5.6%) had branch retinal vein occlusion.

Conclusion: MYIHF has started taking a significant part in secondary IOL implantation due to its simplified technic, the less requirement of equipment, and time-saving advantages. Positioning the IOL is still challenging, but none of our patients had malpositioned IOL. MYIHF technic proves safety, adequate postoperative BCVA, and a well centralized IOL but requires long-term studies to replace sutured scleral fixation technics fully.

Keywords: Modified Yamane technic, intrascleral fixation

[Abstract:0299]**Long-term retinal pigment epithelium detachment and drusen changes in eyes with non-neovascular aged related macular degeneration**Aylin Karalezli¹, Sema Tamer Kaderli²¹Mugla Sitki Kocman University²Mugla Training and Research Hospital

Purpose: To evaluate the changes in size of drusens and pigment epithelium detachment (PED) in patients with non-neovascular age-related macular degeneration (AMD).

Methods: Twenty-two cases with of non-neovascular AMD tracked using SD-OCT through periods of growth and collapse were evaluated. Demographic and clinical data included age, sex, laterality, best-corrected visual acuity (BCVA)(logMAR), height and weight of drusens and PED (µm) and subfoveal choroidal thickness (µm) measured at baseline and at the last available follow-up. The presence of geographic atrophy (GA) and macular neovascularization (MNV) was also assessed.

Results: Twenty-two eyes of 22 patients were included in the analysis. Mean age at baseline was 70 ± 7.3 years. In 16 eyes drusenoid PED and in 6 eyes serous PED were obtained. During follow-up period (mean follow-up period was 3.9 ± 1.1 years) PED collapse was observed in 4 eyes with drusenoid PED and in 2 eyes with serous PED. Mean BCVA, mean maximum PED height, and mean subfoveal choroidal thickness significantly decreased from baseline to the last visit ($p < 0.001$) in patients showing PED collapse. There was no significant change in terms of drusens' size. 10 eyes (45.4%) developed GA and 4 eyes (18.1%).

Conclusions: Choroidal thickness significantly decreased in eyes showing drusenoid PED collapse. Observation of PED and choroidal thickness may be useful for monitoring non neovascular AMD.

Keywords: retinal pigment epithelium detachment, drusen, aged related macular degeneration

[Abstract:0300]**The implementation of pneumatic retinopexy in the Japanese population**Kunihiko Akiyama¹, Ken Watanabe¹, Takaaki Matsuki¹,Toru Noda¹, Rajeev H Muni²

¹1) Department of Ophthalmology, National Hospital Organization Tokyo Medical Center, Tokyo, Japan; 2) Division of Vision Research, Institute of Sensory Organs, National Hospital Organization Tokyo Medical Center, Tokyo, Japan

³3) Department of Ophthalmology, St. Michael's Hospital/Unity Health Toronto, Toronto, Ontario, Canada; 4) Department of Ophthalmology & Vision Sciences, University of Toronto

Purpose: Pneumatic retinopexy (PnR) is currently used infrequently in the Japanese population. The purpose of this study is to assess the implementation of PnR in eyes with

rhegmatogenous retinal detachment (RRD) in comparison with scleral buckling (SB) and pars plana vitrectomy (PPV) approaches in the Japanese population.

Methods: We retrospectively reviewed 73 consecutive eyes treated for RRD between December, 2020 and October, 2022. All cases were treated by a single surgeon in a tertiary care hospital in Tokyo. The method of treatment was selected at the surgeon's discretion; generally, PnR was adopted primarily when it met clinical trial criteria (PIVOT). Baseline characteristics and treatment outcomes (primary reattachment rate and visual acuity at 3 months and at the last visit) were compared among PnR, SB and PPV groups.

Results: Of 73 eyes included, 33 eyes (45.2%) were treated by PnR, while SB and PPV were selected for 13 (17.8%) and 27 eyes (37.0%), respectively. The proportion of eyes meeting PIVOT criteria was significantly higher in PnR group (27 eyes; 81.8%) compared to SB (2 eyes; 15.4%) and PPV (6 eyes; 22.2%) groups ($p < 0.001$), with preponderance of superior breaks detected in 28 eyes (84.8%) of the PnR group. The post-treatment visual acuity was similar between the 3 groups at 3 months ($p = 0.069$) and at the last visit ($p = 0.310$). Primary reattachment was achieved in 29 eyes (87.9%), 12 eyes (92.3%) and 27 eyes (100.0%) after PnR, SB and PPV, respectively ($p = 0.152$).

Conclusions: PnR was applied to 45.2% of the cases and contributed to primary reattachment without an operating room setting or hospitalization in 39.7% (27/73) of the total cases, which is a substantial advantage in the Japanese health care system. PnR should be considered as a first-line treatment in appropriate cases of RRD, particularly in eyes meeting clinical trial criteria.

Keywords: pneumatic retinopexy, implementation, rhegmatogenous retinal detachment

[Abstract:0301]**Effect of phacovitrectomy and prior lens status on the surgical outcomes of 23 gauge pars plana vitrectomy for primary rhegmatogenous retinal detachment**Sefik Can Ipek¹, Cem Yıldırım²¹Private Bodrum Gozakademi Hospital, Mugla, Turkey²Private Denizli Gozakademi Hospital, Denizli, Turkey

Objective: To report the effects of the prior lens status on the surgical outcomes of 23-gauge pars plana vitrectomy/phacovitrectomy for primary rhegmatogenous retinal detachment.

Methods: 69 eyes of consecutive patients were recruited between January 2020 and January 2022. All surgeries were performed by the same surgeon and same settings. All phakic patients underwent phacovitrectomy and all 23 gauge sclerotomies were sutured. Tamponade at the end of PPV was with 1000cs silicone oil (n=18), 5000cs silicone oil (n=12),

SF6 (n=8), C3F8 (n=28) and Densiron (n=3). Preoperative ocular factors, intraoperative surgical procedures, tamponade agents, and postoperative best-corrected visual acuities were evaluated and compared between groups.

Results: 69 eyes (33 phakic, 36 pseudophakic) of 69 patients (56 males, 13 females) with a mean age of $55,7 \pm 13,2$ years (17-82) were treated with 23 gauge vitrectomy for primary rhegmatogenous retinal detachment. 33 eyes (47,8%) underwent phacovitrectomy. There were no significant differences between the two groups by age, sex, mean axial length, PVR status, preoperative visual acuity, preoperative intraocular pressure, and the number of tears. Anatomical success was achieved in 87,9% of cases (29 out of 33) in the prior phakic group, 97,2% of cases (35 out of 36) in the prior pseudophakic group with single surgery; however, no statistically significant difference was observed ($P=0.135$). Postoperative complications included transient intraocular pressure rise (15,9%) fibrinous uveitis (18,8%) and posterior synechia (5,3%) were statistically similar between the two groups.

Conclusions: The success rates of primary PPV in prior pseudophakic patients with RRD were similar to the phacovitrectomy group. Simultaneously combined cataract surgery with retinal detachment seems safe and effective option but the retrospective and limited data presented in this study requires further prospective studies to confirm these findings.

Keywords: pars plana vitrectomy, phacovitrectomy, rhegmatogenous retinal detachment

[Abstract:0302]

Posterior vitreous attachment as a risk factor for endophthalmitis following intravitreal antivasular endothelial growth factor injection

Durgul Acan, Eyyup Karahan

Department of Ophthalmology, School of Medicine, Balikesir University, Balikesir, Türkiye

Purpose: To evaluate the importance of incompleting posterior vitreous detachment (PVD) in terms of the risk of endophthalmitis following intravitreal anti-vascular endothelial growth factor (anti-VEGF) injection.

Methods: In this retrospective interventional study, 23 eyes (study group) of 23 patients who developed endophthalmitis following intravitreal anti-VEGF administration were evaluated during pars plana vitrectomy after urgent vitreous tap and intravitreal antibiotics. The incidence of PVD in these patients was compared with 24 eyes (control group) of 24 patients who received intravitreal anti-VEGF without any complication. Study patients underwent a complete vitrectomy with PVD intraoperatively. Intraoperative and postoperative complications were evaluated.

Results: There was no difference between the control

and study group in terms of age, gender and indication for intravitreal injection. PVD was completed in 13 (54.1%) eyes of 24 patients in the control group, whereas only 2 (8.7%) eyes of 23 patients in the endophthalmitis group ($p<0.001$). At the time of surgery, posterior vitreous was detached carefully without complications in 21 eyes of 21 patients without PVD. No iatrogenic tear occurred in any eye during surgery. Silicone oil tamponade was not used in any of the patients. Visual acuity before intravitreal injection was achieved in 22 (95.6%) out of 23 patients. Retinal detachment developed in 3 (13.0%) eyes of 23 patients in the postoperative follow-up. In multiple regression analysis, absence of PVD was found to be an independent risk factor for endophthalmitis following intravitreal anti-VEGF injection.

Conclusion: The absence of PVD is an important risk factor for the development of endophthalmitis. Creating an uncomplicated PVD is of great importance for the success of vitrectomy for endophthalmitis.

Keywords: Endophthalmitis, pars plana vitrectomy, posterior vitreous detachment

[Abstract:0303]

Early results of autologous retinal pigment epithelium-choroid transplantation for the treatment of eyes with subretinal disciform scar formation

Eyyup Karahan, Durgul Acan

Department of Ophthalmology, School of Medicine, Balikesir University, Balikesir, Türkiye

Purpose: To present early outcomes of subfoveal scar excision and autologous retinal pigment epithelium(RPE)-choroid transplantation with a peripheral retinotomy.

Methods: Seven patients who underwent vitreoretinal surgery with subfoveal scar excision and autologous RPE-choroid transplantation with a peripheral retinotomy between November 2022 and January 2023 were analyzed retrospectively. Subfoveal scar formation has been developed as a result of choroidal neovascular membrane secondary to exudative age-related macular degeneration in 5 patients, angioid streaks in 1 patient and choroidal rupture with subretinal hemorrhage in 1 patient. The duration of scar formation in all patients was between 3 months and 1 year. All eyes were evaluated with pre- and postoperative first-month best-corrected visual acuity (BCVA), optical coherence tomography, optical coherence tomography angiography and fluorescein angiography.

Results: Mean age was $64.57(24-83)$ years. Five patients were female. Four phakic patients underwent phacoemulsification and intraocular lens implantation at the beginning of the surgery. Silicone was used as tamponade in all patients. Mean pre- and postoperative first-month BCVA was 1.54 ± 0.70 logMAR and 1.41 ± 0.65 logMAR, respectively ($p=0.068$). At the 1st month examination, visual acuity in 4 of 6 patients reached the level

of finger counting at least 1 meter from hand movement level. Submacular hemorrhage in 1 patient developed at the first week of follow-up. Inferior quadrant retinal detachment under silicone oil was developed in 1 patient.

Conclusion: Considering our short-term evaluation with a small number of patients, although it did not reach statistical significance, we achieved a slight increase in BCVA in these patients. Autologous RPE-choroid graft is promising even in patients with subfoveal scar formation and impaired inner-segment/outer-segment junction band, and complication rates will decrease as the surgical method improves. Nonetheless, it is appropriate to evaluate with long-term results of more patients.

Keywords: Age-related macular degeneration, subfoveal scar, retina pigment epithelium-choroid graft

[Abstract:0306]

Refractive evaluation of prophylactic laser treatment for persistent avascular retina in eyes treated with primary intravitreal bevacizumab

Sadık Etki Bayramoğlu, Nihat Sayın

University of Health Sciences, Kanuni Sultan Suleyman Training and Research Hospital, İstanbul, Türkiye

Purpose: With the widespread use of anti-vascular endothelial growth factor (anti-VEGF) treatment for retinopathy of prematurity in recent years, the treatment choice for persistent avascular retina (PAR) is challenging, and the refractive effect of laser treatment is not well known. Primary aim was to investigate the refractive outcomes of laser treatment on the peripheral avascular retina after the 60th week of postmenstrual age (PMA) in eyes with premature retinopathy treated with intravitreal bevacizumab (IVB).

Methods: Inclusion criteria in the study consisted of several parameters: 1) Being treated primarily with IVB, 2) Laser applied to peripheral avascular retina after 60th PMA between February 2018 and December 2019, and 3) Pre- and post-laser refraction measurements after cycloplegia were recorded in the patient chart. Forty-six eyes of 26 infants fulfilled the inclusion criteria.

Results: Forty-five eyes underwent fundus fluorescein angiography before the laser. Persistent avascular retina was accompanied by Hyperfluorescein leakage in 14 eyes. Pre-laser retinal vascularization was in zone 2 posterior in 44 eyes. The mean number of laser spots was 641.54 ± 377.28 . The mean pre-laser refraction age, laser age and post-laser refraction age were 23.50 ± 13.80 , 27.39 ± 14.42 , and 44.58 ± 17.03 , months, respectively. The spherical equivalent before and after laser was 1.21 ± 2.64 (D) and 0.58 ± 2.41 Diopter (D), respectively ($p = 0.006$).

Conclusion: In eyes treated with IVB as primary treatment, 0.63 ± 1.01 D myopic change was detected at a mean follow-up of 17.19 months. Although the myopic shift in refraction

after laser is statistically significant, the physiological emmetropization of childhood may have contributed to this difference. Further studies are needed to understand whether the myopic change was due to laser or to physiological emmetropization in childhood.

Keywords: Bevacizumab, Laser, Retinopathy of prematurity

[Abstract:0307]

Intravitreal needle technique for intrascleral haptic fixation of posteriorly dislocated three-piece intraocular lenses

Tansu Erakgun

Kaşkaloğlu Göz Hastanesi, İzmir

Purpose: Double-needle intrascleral haptic fixation (Yamane) technique is a minimally invasive method for posterior chamber intraocular lens (IOL) fixation in the setting of absent or inadequate capsule support. A modified intravitreal needle technique is herein described for the management of three piece IOLs which are dislocated into the vitreous cavity.

Methods: In this technique, after completing pars plana vitrectomy, under the noncontact ophthalmomicroscope, the haptic of the dislocated IOL is docked directly in the vitreous cavity into a 27-G needle which is inserted through a transconjunctival tunneled scleral incision 2 mm. from the corneal limbus, and externalized from the conjunctiva and fixated sclerally.

Results: The technique is described with a case series of 12 patients. No preoperative or postoperative complication was seen.

Conclusion: In this technique, the dislocated IOL is not taken in the anterior segment before the scleral fixation. The haptics are threaded into the 27-G needle directly in the vitreous cavity during the vitrectomy. This is a short cut Yamane technique for posteriorly dislocated three-piece IOLs. This technique may shorten the surgical time and minimize surgical trauma in cases with posteriorly dislocated three-piece IOL.

Keywords: posterior IOL dislocation; pars plana vitrectomy; double needle intrascleral haptic fixation

[Abstract:0309]

Mystery of the mass- Choroidal granuloma as the presenting sign of disseminated tuberculosis

Monisha Apte, Manjula Shankar, Hemanth Murthy,
Muralidhar Naveenam
Retina institute of Karnataka

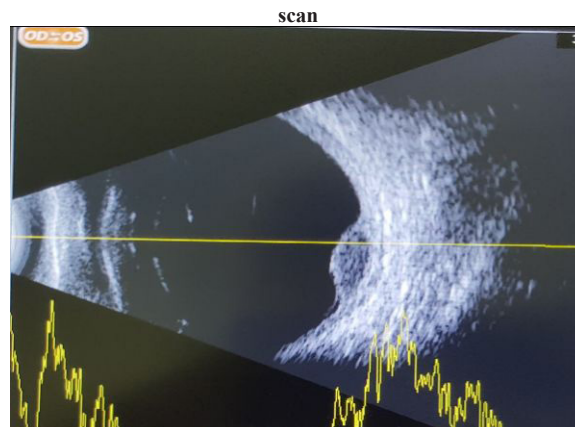
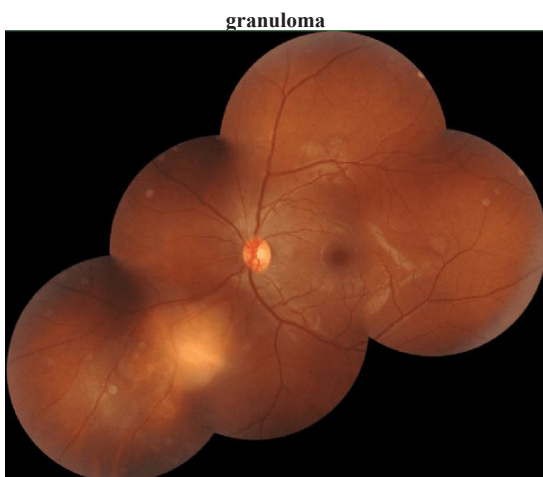
Aim: To report an interesting case of choroidal granuloma presenting as the first sign of disseminated tuberculosis

Methods: Interventional case report.

Results: A 26 year old young lady presented with complaints of distortion in superotemporal field of vision in her left eye. She had a 6/6 central vision, quiet anterior chamber and clear vitreous with fundus showing a creamy choroidal mass with subretinal fluid in the inferonasal quadrant. Optical coherence tomography showed a smooth elevated choroidal mass with SRF&contact sign. Lesion on B scan ultrasonography showed medium internal reflectivity with no excavation. Lesion was progressively hyperfluorescent on fundus fluorescein angiography, with margin showing pin point leakage. Examination of right eye was normal. Both lung fields showed multiple small non calcified non cavitating nodules. MRI brain showed enhancing lesions in left cerebellum and right frontal lobe and left globe suggestive of multiple brain and choroidal metastasis. PET CT showed hypermetabolic cavitary nodule in upper lobe of left lung with hypermetabolic hilar lymph node and multiple scattered bilateral pulmonary nodules with few brain lesions and thickened choroid in left eye leading to a dilemma between inflammatory granuloma and choroidal metastasis. CT guided biopsy showed organising pneumonia favouring tuberculosis with negative Acid fast bacilli. Patient was started on antitubercular therapy & oral steroids helping in resolution of lesions improving vision with no recurrence

Conclusion: This case is unique as choroidal granuloma here presented as first sign of disseminated tuberculosis. Going an extra mile is essential for correct diagnosis

Keywords: granuloma, tuberculosis, metastasis



[Abstract:0313]

Bacillary Layer Detachment in the Pathophysiology of Secondary Macular Hole in Fovea-off Rhegmatogenous Retinal Detachment

Isabela Martins Melo¹, Aaditeya Jhaveri², Aditya Bansal¹,
Wei Wei Lee², Paola L Oquendo¹, Rajeev H Muni³

¹University of Toronto; St Michael's Hospital, Toronto, ON, Canada

²University of Toronto, Toronto, ON, Canada

³University of Toronto; St Michael's Hospital; Kensington Eye Institute Toronto, ON, Canada

Purpose: To describe the pathophysiology of secondary macular hole (MH) in rhegmatogenous retinal detachment (RRD) by assessing bacillary layer detachment (BALAD) and associated abnormalities using optical coherence tomography (OCT).

Methods: Retrospective cohort including 360 consecutive primary fovea-off RRDs referred between January 2012-September 2022. Pre-operative OCTs were assessed for BALAD-related abnormalities, including lamellar and full-thickness MH (FTMH).

Results: 22.5% (81/360) of patients had evidence of BALAD-related abnormalities at presentation. 8% (29/360) had MH associated with RRD, of which 79.3% (23/29) were lamellar holes with the posterior border of BALAD intact (BALAD-lamellar hole), and 20.6% (6/29) were FTMH. Immediately following reattachment, 62% (18/29) of MHs persisted, while 38% (11/29) closed with RRD repair. Of those that persisted, 83% (15/18) had BALAD-lamellar holes, all of which progressed to FTMH in a mean of 8.1 (±3.2SD) days. OCT imaging demonstrated the spectrum of changes from BALAD to FTMH, which included 1) cleavage planes from Henle fiber layer (HFL)-outer plexiform (OPL) at the foveal walls into the BALAD cavity; 2) significant thinning of central outer nuclear layer (ONL); 3) loss of the Müller cell cone (MCC) with tissue remnants at the foveal wall inner edges; 4) retinal operculum attached to vitreous strands in proximity to BALAD-lamellar hole; and 5) progressive thinning/degradation of the posterior border of BALAD-lamellar hole leading to FTMH. Histological sections from normal eyes were assessed to assist with OCT interpretations and to determine possible areas of

low mechanical stability.

Conclusion: This study provides novel insights into the progression from BALAD to BALAD-lamellar hole and subsequent FTMH in RRD. Hydration, tractional forces, and cystic/cellular degeneration are key processes. OCT interpretations guided by histological sections of normal eyes demonstrating probable areas of low mechanical stability suggest that the pathophysiological process occurs with sequential changes in critical areas: RPE-photoreceptor interface, myoid zone, HFL-OPL at the foveal walls and MCC with surrounding tissue. This process culminates in photoreceptor-MCC disjunction leading to BALAD-lamellar hole, which subsequently degenerates leading to FTMH.

Keywords: rhegmatogenous retinal detachment, full-thickness macular hole; bacillary layer detachment

[Abstract:0316]

Effect of Adjuvant Mitomycin-C in Severe Traumatic Retinal Detachments Surgery with Retinotomy-Retnectomy

Burak Acar, Gökhan Gürelik, Hüseyin Baran Özdemir
Gazi Üniversitesi, Göz Hastalıkları Ana Bilim Dalı, Ankara

Purpose: It was aimed to investigate the effect of adjuvant Mitomycin-C (MMC) use on the anatomical and functional success of patients who underwent retinotomy-retinectomy (RR) during vitreoretinal surgery (VRC) in cases of traumatic retinal detachment (RD) with proliferative vitreoretinopathy (PVR).

Methods: The files of patients who underwent VRC and RR due to severe traumatic RD between 2016-2022 were reviewed retrospectively. Demographic and clinical data were analyzed in 2 groups as intraoperative "MMC sandwich technique" with intravitreal adjuvant MMC used (Group A) and not used (Group B).

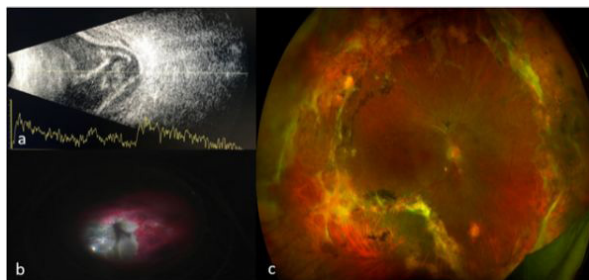
Results: Thirty eyes of 30 patients, 15 of whom were in Group A, were included in the study. The two groups were statistically similar in terms of age, gender, trauma type, trauma zone, visual acuity (VA) and intraocular pressure (IOP) ($p>0.05$). Proliferative vitreoretinopathy (PVR) rate was similar in both groups with PVR B and above ($p=0.296$). Patients who underwent at least 1 quadrant RR were added and the RR width was similar in both groups ($p=0.639$). After RR and VRC, postoperative recurrence and recurrent surgery rates were lower in Group A compared to Group B (6.7% and 60%, respectively), and this difference was statistically significant ($p=0.005$). Final anatomical success (retinal attachment) rate was 95% in Group A and 68% in Group B, and this difference was statistically significant ($p=0.022$). Silicone removal rate was similar in both groups (Group A: 47.1%; Group B: 66.7%; $p=0.456$). At the final examination, VA ($p=0.628$) and IOP ($p=0.813$) were statistically similar between the two groups.

Conclusion: In traumatic RD cases requiring retinotomy-retinectomy, lower recurrence rates and better anatomical

results can be achieved by using the MMC sandwich technique and adjuvant Mitomycin-C. Prospective studies with more patients are needed on this subject.

Keywords: traumatic retinal detachment, PVR, mitomisin-c

Figure 1



59 years old male, Total Retinal Detachment after falling from high. Treated with peripheral 360 degree retinotomy (a) Retinal detachment with vitreous hemorrhage and PVR on B-Usg. (b) Intraoperative image of retinal detachment and vitreous hemorrhage. (c) Fundus image of attached posterior segment without PVR (postoperative 3 year)

[Abstract:0317]

Developing an artificial intelligence model to detect epiretinal membranes in OCT by using a machine learning platform without typing code

Hakan Baybora, Sadık Altan Özal, Murat Karapapak, Ece Özal, Şerife Çiloğlu Hayat, Serhat Ermiş, Yusuf Cem Yılmaz
Sağlık Bilimleri Üniversitesi, Çam veSakura Şehir Hastanesi, Göz Hastalıkları Anabilim Dalı, İstanbul

Purpose: To develop a method by using an auto machine learning platform without coding to detect epiretinal membrane in OCT

Methods: Anonymized 60 OCT (Xephilio OCTA-1, Canon, Netherlands) images of patients who have an epiretinal membrane and, 60 OCT images of patients who don't have the disease, were used for the training set. For testing a total of 40 images were used and half of them were having and the other half don't have the disease. The segmentation process is applied to the training images with Weka trainable image segmentation in the ImageJ program. The images used for testing were selected from different OCT devices. Then all images are uploaded to the Vertex AI AutoML application of the Google Cloud platform. The images were labelled and after that, training and testing processes of the platform were performed. The models were evaluated by the same platform.


Results: Precision recall curves and confusion matrix were calculated. The precision value which shows the percentage of correct predictions and the recall value, which shows the ground truth items that were successfully predicted by the model were calculated by the same platform. The results that were given by the platform were 100% for precision recall values and true positives, and true negatives.

Conclusion: Models for recognition of the retinal images by using artificial intelligence, the popular technology of

our century, can be built by ophthalmologists. As we are the primary occupational group for these images, the preparation of the models by us is more valuable and can be accomplished without using codes. Our training group was containing images of primary and secondary epiretinal membranes. The test group was prepared from images of different devices of our clinic. For the power of our model, it may need testing with different images from different clinics.

Keywords: epiretinal membrane, artificial intelligence

Figure 1



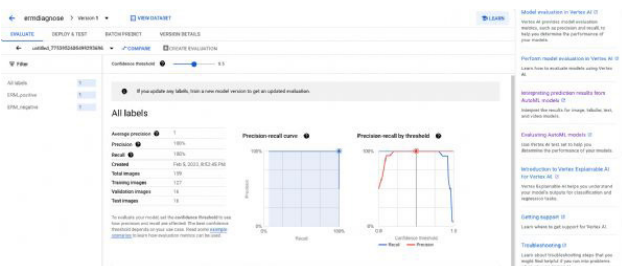Segmented Epiretinal membrane OCT image

Figure2



Segmented OCT image without epiretinal membrane

Figure3



Precision, recall results calculated by the AI platform

[Abstract:0319]

Tissue Plasminogen Activator for the Treatment of Preretinal Blood Under Silicone Oil

Fevzi Şentürk, Cengiz Aras, Mehmet Selim Kocabora, Munise Altınbaş

Department of Ophthalmology, Medipol University, Istanbul, Türkiye

Purpose: To report the results of use of tissue plasminogen activator(t-PA) for the treatment of preretinal blood under silicone oil after vitrectomy for proliferative diabetic retinopathy.

Methods: Four eyes of 4 patients who developed preretinal blood under silicone oil within one week after vitrectomy for proliferative diabetic retinopathy were treated with intravitreal injection of 25 microgram of t-PA. Patients were kept at supine position for 1 hour after injection of t-PA and followed up at day 1, and first, second and third weeks after injection.

Results: Preretinal blood under silicone oil was completely regressed within 3 weeks after injection in 3 of 4 eyes. One eye developed recurring hyphema and ghost cell glaucoma and needed repeated anterior chamber lavage procedures. No eyes developed preretinal fibrosis and any sign of toxicity.

Conclusion: Intravitreal injection t-PA for the treatment of preretinal hemorrhage under silicone oil after vitrectomy for proliferative diabetic retinopathy is effective for fibrinolysis of preretinal blood under silicone oil and fastening the resorption time.

Keywords: tissue plasminogen activator, silicon oil, preretinal hemorrhage

[Abstract:0320]

In vivo generated autologous plasmin(IVAP) assisted vitrectomy, oral retinotomy, silicone oil injection for the treatment of chronic retinal detachment

Cengiz Aras, Fevzi Şentürk, Mehmet Selim Kocabora, Sevil Karaman Erdur, Yunus Emre Budak

Istanbul Medipol University Medical School

Purpose: To report the results of IVAP assisted vitrectomy, inferior-oral retinotomy and silicone oil injection for surgical treatment of patients with chronic retinal detachment.

Methods: A total of 14 consecutive eyes with chronic retinal detachment who had intravitreal injection of 25 µg of t-PA and 0.1 ml of autologous whole blood, 3 days before surgery, underwent lens extraction with phacoemulsification, vitrectomy, oral retinotomy, and silicone oil injection were compared to a similar group of 16 consecutive eyes with chronic retinal detachment who undergone vitrectomy, with or without lens extraction and silicone oil injection. Primary outcome measure was single operation success.

Results: Mean age of 12 patients of whom 6 (Group 1) were female, was 38.66 ± 18.75 years and 15 patients of whom 4 were female (Group 2), was 35.40 ± 11.92 years ($p=0.58$). Mean follow-up time was 11.69 ± 7.61 months in group 1 and 29.13 ± 18.83 months in group 2 ($p=0.04$). While the preoperative LogMAR visual acuity was 1.35 ± 0.65 , it was 0.61 ± 0.42 at postoperative final exam. While the preoperative LogMAR visual acuity was 1.22 ± 0.33 , it was 1.20 ± 0.89 at postoperative final exam ($p=0.038$). Retinal reattachment was achieved 12 of 13 eyes (92.30%) in group 1 and 7 of 15 eyes (46.66%) in group 2 with one surgical intervention ($p=0.010$).

Conclusion: IVAP assisted vitrectomy, oral retinotomy and silicone oil injection is effective and safe for the surgical treatment of chronic retinal detachment.

Keywords: Autologous Plasmin Enzyme, Chronic Retinal Detachment

[Abstract:0322]

Buckle Phaco Vitrectomy for retinal detachment with PVR: Technique and outcome

Wael Ahmed Ewais

Department of Ophthalmology, Faculty of medicine Kasr alaini, Cairo University, Cairo, Egypt

Introduction: Adjuvant Buckle with vitrectomy, for retinal detachment with PVR, may be a useful tool for a better anatomical outcome with less number of reoperations, and may enable the surgeon to keep retinectomy for a later intervention if needed.

However, there is a challenging situation for the surgeon if the patient is phakic. As the surgeon may need to perform a combined phacovitrectomy.

Methods: The encircling band is first inserted with slight tightening, then a routine phacovitrectomy is performed, then final tightening of the band is performed

Outcome measures:

Incidence of:

- Iris prolapse through limbal wound
- Loss of anterior chamber
- IOL dislocation
- Posterior capsular rupture

IOL centration

Postoperative iritis

SSAS (single surgery anatomical success)

Keywords: Proliferative vitreoretinopathy, Retinal Detachment, Buckle

[Abstract:0326]

Risk factors and management of cystoid macular edema following pars plana vitrectomy for rhegmatogenous retinal detachment

Oumayma Elmansouri, Amine Mounsif, Houda Bezza, Zineb Algouti, Youssef Bennouk, Mohamed Kriet, Fouad Elasri
Ophthalmology department, Avicenne military hospital, Marrakesh, Morocco

Purpose: To discuss the main risk factors of the development of cystoid macular edema (CME) complicating pars plana vitrectomy (PPV) for rhegmatogenous retinal detachment (RRD) and how to manage it.

Methods: This is a retrospective study from January 2019 to January 2023, including 325 patients admitted for primary RRD in our ophthalmology department. All patients included underwent 23G vitrectomy, cryo or laser retinopexy of the tear(s) followed by gas tamponade. A complete ophthalmic examination and Spectral Domain optical coherence tomography (SD-OCT) were performed at regular postoperative intervals, i.e., at 1 month, 3 months and 6 months.

Results: Twenty nine patients presented macular edema after surgery. The mean duration of macular edema onset (tomographic diagnosis) was 45 ± 15 days. BCVA was 1/10 after the onset of macular edema. Patients over 50 years old, with preoperative macula off RRD, duration of RRD >1 week and proliferative vitreoretinopathy were more prone to develop macular edema. A statistically significant improvement in BCVA and central retinal thickness 6 months after intravitreal dexamethasone implant compared to baseline and patients treated with bevacizumab injections.

Conclusion: This study confirmed that postoperative CME is a frequent complication after RRD surgery; we identified. As CME potentially delays visual recovery, postoperative follow-ups should include SD-OCT. Intravitreal dexamethasone implant seem to be effective in the treatment of this complication.

Keywords: Cystoid macular edema, retinal detachment, pars plana vitrectomy

[Abstract:0329]**Comparing the Effects of Silicone-Oil and Perfluoropropane Gas Tamponade on Macular Microcirculation in Rhegmatogenous Retinal Detachment Treated with Vitrectomy: An Optical Coherence Tomography Angiography Study**

Ece Özal, Muzaffer Said Güler, Murat Karapapak, Hakan Baybora, Serhat Ermiş, Yusuf Cem Yılmaz, Şerife Çiloğlu Hayat, Sadık Altan Özal
Basaksehir Cam and Sakura City Hospital Department of Ophthalmology, Istanbul, Türkiye

Purpose: This study aimed to compare changes in optical coherence tomography angiography (OCTA) among patients with rhegmatogenous retinal detachments (RRD) who underwent pars plana vitrectomy (PPV) with either silicone-oil or perfluoropropane (C3F8) gas tamponade.

Methods: A retrospective study was conducted to evaluate the outcomes of patients with macula-off retinal detachment (RRD) who underwent a single pars plana vitrectomy (PPV) surgery. The study population consisted of patients who received either silicone oil or 14% C3F8 gas as the endotamponade during surgery. Detailed ophthalmological examinations and OCTA measurements were performed using the DRI-OCT Triton device (Topcon, Inc, Tokyo, Japan), a swept-source OCT device, after the removal of silicone-oil in eyes with silicone-oil and three months post-operatively in eyes with gas. The measurements assessed various parameters, including vessel density (VD) and foveal avascular zone (FAZ) area, were compared between the two groups.

Results: The study enrolled 39 patients, with 16 (41%) females and 23 (59%) males, who had a mean age of 56.61 ± 9.00 , ranging from 28-74. Of the total eyes treated, 21 (53.8%) received silicone-oil tamponade, and 18 (46.2%) received C3F8 tamponade. The silicone-oil tamponade group had significantly lower VD in the superficial capillary plexus (SCP), outer retina, and choriocapillaris than the gas tamponade group ($p=0.02$, $p=0.001$, $p=0.000$ respectively). However, no significant differences were observed between the two groups regarding FAZ area and deep capillary plexus (DCP) VD.

Conclusion: These findings suggest that the choice of endotamponade agents in patients with macula-off retinal detachment may have an impact on retinal vascular changes. Further studies are needed to confirm these results and determine the long-term effects of different endotamponade agents.

Keywords: OCTA, silicone-oil, retinal vascular density

[Abstract:0331]**Retropupillary Iris-Claw lens Implantation in Aphakic eyes: Technique and Tips**

Wael Ahmed Ewais
Department of Ophthalmology, Faculty of Medicine, Kasr Alaini, Cairo University, Cairo, Egypt

I will describe – step by step- the surgical technique for retropupillary iris claw lens implantation in Aphakic eyes:

- Insertion of infusion tube
- Main clear corneal keratome incision
- Side ports
- Intraocular lens (IOL) check and insertion
- Enclavation of the IOL
- Closure of main incision

I will demonstrate indications for Iris-Claw lens Implantation in Aphakic eyes

I will demonstrate possibilities of further surgeries (if needed) with an implanted IOL

Keywords: Aphakia, Intraocular lens, Iris-claw

[Abstract:0339]**Bone marrow-derived mesenchymal stem cell therapy in patients with retinitis pigmentosa**

Nil İrem Uçgun, Cenk Zeki Fikret, Mualla Sahin Hamurcu
Ankara City Hospital, Ankara, Türkiye

Purpose: To determine the effectiveness of bone marrow-derived mesenchymal stem cell therapy on visual acuity and visual field in patients with retinitis pigmentosa.

Method: 47 eyes of 27 patients diagnosed with retinitis pigmentosa were included in our study. Allogeneic bone marrow-derived mesenchymal stem cells were administered by deep subtenon injection. Complete routine ophthalmological examinations, optical coherence tomography (Zeiss, Cirrus HD-OCT) measurements, visual field (Humphrey perimetry, 30-2) tests were performed on all patients before and at the 1st, 3rd, and 6th months after treatment. The best corrected visual acuities of the patients were determined by Snellen chart and converted to logMAR. Visual evoked potential (VEP) and electroretinogram (ERG) examinations of the patients before the treatment and at the 6th month after the treatment were performed (Metrovision) data were compared.

Results: Visual acuities were 0.74 ± 0.49 logMAR before treatment and 0.61 ± 0.46 logMAR after treatment. This increase in visual acuity was statistically significant ($p < 0.001$). The visual field deviation was found -27.16 ± 5.77 dB before treatment and -26.59 ± 5.96 dB after treatment ($p = 0.005$). Ganglion cell layer was 46.26 ± 12.87 μ m before treatment and 52.47 ± 12.26 μ m after treatment ($p = 0.003$). There was a significant improvement in Pattern VEP 120°

P100 amplitude compared to before treatment ($4.43 \pm 2.42 \mu V$) and after treatment ($5.09 \pm 2.86 \mu V$) ($p=0.013$). ERG latency measurements were $18.33 \pm 15.39 \mu V$ before treatment and $20.87 \pm 18.64 \mu V$ after treatment for scotopic 0.01 ($p=0.02$). ERG latency measurements for scotopic 3.0 were $20.75 \pm 26.31 \mu V$ before treatment and $23.10 \pm 28.60 \mu V$ after treatment ($p=0.014$).

Conclusion: Retinitis pigmentosa is a progressive, inherited disease that can result in severe vision loss. In retinitis pigmentosa, application of bone marrow-derived mesenchymal stem cells by deep subtenon injection has positive effects on visual function. No systemic or ophthalmic side effects were detected in the patients during the 6-month follow-up period.

Keywords: Retinitis pigmentosa, Retinal dystrophy, Stem cell

[Abstract:0343]

Five year follow-up results of retinopathy of prematurity cases treated by laser or injection

Semra Acer, Gülşah Yılmaz, Özlem Tök, Levent Tök
Suleyman Demirel University, Department of Ophthalmology

Purpose: To report the long term results of retinopathy of prematurity cases treated by laser or anti-VEGF injection
Setting: Suleyman Demirel University, Department of Ophthalmology

Methods: 74 eyes of 37 premature cases were enrolled. The treatment method was laser in 23 cases and anti-VEGF injection (0,05 mg ranibizumab) in 12 cases and combined laser and anti-VEGF injection in 2 cases. The success of treatment method, best corrected visual acuity (BCVA) by Snellen Chart, cycloplegic refraction as spheric equivalents (SE) and strabismus was evaluated.

Results: The mean gestational age was $27,27 \pm 2,2$ weeks (min 24-max 33 weeks). The mean birth weight was $1018,71 \pm 308$ grams (min 570-max 1849 grams). The mean follow up time was $5,0 \pm 2,17$ years (min 1- max 9 years). One eye of one of the cases treated by laser deteriorated and deemed inoperable retinal detachment. Except for one case all cases improved either by laser or injection or both (98%). The mean BCVA was $0,65 \pm 0,31$ in verbal children. The SE was between 0 to +3,00 D in 45,9% of cases and was greater than -5,00 in 23% of cases. The SE was more myopic in children treated by laser. There was no strabismus in 70 % of cases, 19% esotropia and 11% exotropia and both esotropia and exotropia was higher in laser group.

Conclusions: Both Laser and Anti-VEGF was successful in treatment of ROP. Laser seems to have higher myopic refraction and strabismus rates compared with anti-VEGF treatment.

Keywords: Retinopathy of prematurity, Laser, Anti-VEGF

[Abstract:0344]

Endoscope-assisted vitrectomy in the treatment of 133 severely traumatized eyes without light-perception

Yang Xun, Du Shu, Zha You You
Suzhou Lixiang Eye Hospital

Purpose: To evaluate the effect of endoscope-assisted vitrectomy (EAV) in eyes with no light perception (NLP) or doubtful light perception (dNLP) after severe trauma and analyze characteristics and functional outcomes.

Methods: The medical records, and surgical video when necessary, of all involved cases with visual acuity (VA) of NLP or dNLP after suffering severe ocular trauma from 2003 to 2022, were retrospectively analyzed to determine the effect of EAV and ocular outcomes.

Results: Of the 118 NLP and 15 doubtful NLP eyes that underwent EAV were included in the study, the mean follow-up was 9.34 ± 13.77 months, final VA was better than 0.01 in 5 eyes (3.76%), counting fingers in 19 eyes (14.29%), hand motion in 43 eyes (32.33%), light perception in 24 eyes (18.05%), NLP in 36 eyes (27.07%) and 3 eyes lost information. Three eyes underwent secondary enucleation. Among the 133 patients, there were a total of 4 injury types, namely rupture, intraocular foreign body (IOFB), penetrating and contusion, accounting for 74.44%, 15.79%, 7.52% and 2.26% respectively, and the incidence of endophthalmitis was 3.0%, 38.1%, 30.0% and 0.0%, respectively ($P=0.000$), and the retinal detachment rates were 97.0%, 90.5%, 80.0% and 66.7%, respectively ($P=0.020$). The choroidal detachment rates of patients with rupture, IOFB, penetrating and contusion were 82.8%, 38.1%, 40.0% and 33.3%, respectively, ($P=0.000$). One hundred and five eyes (78.9%) underwent EAV via cornea instead of pars plana. In 76 eyes, the preoperative IOP was below 10mmHg (5.69 ± 2.50 in average, below 6 in 48 eyes), the postoperative IOP was 11.87 ± 4.07 in average (still below 10mmHg in 20 eyes, below 6 in 3 eyes) ($P=0.000$).

Conclusion: Treated with EAV, most severely traumatized eyes without light-perception can avoid enucleation and having a long-term improvement in VA with normal IOP. The trans-corneal EAV is practical, especially in eyes with choroidal detachment and hypotony.

Keywords: Ocular trauma, endoscope-assisted vitrectomy, no light perception

[Abstract:0346]**Comparison of three different techniques in the management of submacular hemorrhage**

Anıl Korkmaz, Murat Arıcı, Metehan Şimşek,
Halil Özgür Artunay
Department of Ophthalmology, Beyoglu Eye Training and Research
Hospital, Istanbul, Turkey

Purpose: Comparison of intravitreal tissue plasminogen activator (tPA) injection and pars plana vitrectomy (PPV) with subretinal tPA injection to treat submacular hemorrhage (SMH)

Methods: Retrospective analysis of 94 eyes surgically treated for SMH caused by age-related macular degeneration, idiopathic, trauma and retinal macroaneurysms. 94 eyes with SMH were retrospectively divided in 3 groups. Group 1 received intravitreal tPA and gas (n=21), group 2 underwent PPV, subretinal tPA and gas (n=53), group 3 underwent PPV, subretinal tPA and gravitational displacement (n=20). Main outcome measures are pre-operative visual acuity (VA), final VA, SMH duration until surgery, final central macular thickness (CMT) and surgical complications.

Results: Ninety-four patients with a mean age of 71.01 ± 16.45 years were followed 45.94 ± 24.56 months. Mean duration of SMH prior intervention was $10.2 (\pm 8.3)$ days. Mean VA improved from logMAR 1.90 ± 0.54 at baseline to logMAR 1.13 ± 0.72 at final. Mean final CMT was $312.1 \pm 108.5 \mu\text{m}$. All surgical approach achieved statistically significant gain in vision compared to baseline. ($p < 0.05$). A significant negative correlation was found between SMH duration and final VA. ($p: 0.005$) Complications consisted of 4 cases of recurrent subretinal hemorrhage, 3 vitreous hemorrhages, 2 retinal detachment, and 3 macular hole during the follow-up period.

Conclusion: This study suggests that three different surgical techniques may be an effective procedure for SMH. The duration of the SMH appear to be related to the success of the surgery.

Keywords: Recombinant tissue plasminogen activator; Submacular hemorrhage; Pars plana Vitrectomy

[Abstract:0347]**Calviale Scleral Fixated IOL. The Ultimate Solution**

Stratos Gotzaridis
My Retina Athens Eye Center, Athens, Greece

Since the introduction of PC IOLs there were papers presenting scleral fixation of IOLs in the absence of capsular support. During the years the technique was improving to more efficient and sophisticated ones.

Since the introduction of the Calviale IOL in 2015. The Calviale IOL is the one and only labelled for the use of capsular absence. Also has great advantages in preventing of tilting and losing its stability

Keywords: scleral fixation IOL

[Abstract:0349]**A case of rhegmatogenous retinal detachment with an unpredictable macular tear treated with autologous retinal graft**

Sibel Demirel, Özge Yanık Odabaş, Figen Şermet, Emin Özmert
Department of Ophthalmology, Ankara University School of Medicine,
Ankara, Turkey

Purpose: To report a case of rhegmatogenous retinal detachment with macular tear treated with autologous retinal graft.

Methods: A 40-year-old male presented with decreased vision following trauma with a piece of stone. The view of posterior segment was precluded due to cortex material. Ocular ultrasonography detected total retinal detachment.

Results: During 25-G pars-plana vitrectomy, an unexpected large macular tear more than 1 disc diameter in size was observed. Autologous retinal graft was the only possible surgical option to close this macular tear. A retinal graft was taken from nasal upper periphery under perfluorocarbon and spread over macula. Five months after PPV surgery, the retinal graft was in place and integrated with the edge of the tear and visual acuity was increased to 20/400.

Conclusion: An autologous retinal graft may be an effective surgical option in the presence of macular tear.

Keywords: macular graft, macular tear, retinal detachment

[Abstract:0351]**Determination of postoperative positioning time after macular hole surgery by Optical Coherence Tomography Angiography (OCTA)**

Irem Kirci Dogan¹, Sezin Akca Bayar¹, Zeynep Eylul Ercan²,
Rengin Aslıhan Kurt³, Imren Akkoyun¹, Gursel Yılmaz¹
¹Baskent University Ankara Hospital, ANKARA, TURKEY
²Yenimahalle Training and Research Hospital, ANKARA, TURKEY
³Baskent University Istanbul Hospital, ISTANBUL, TURKEY

Introduction: Pars plana vitrectomy with or without internal limiting membrane (ILM) peeling followed by gas tamponade with face-down positioning (FDP) is the main treatment for macular hole (MH). In this study, we report the anatomical and visual outcomes after MH repair with OCTA guided FDP.

Methods: The study included 44 patients who underwent surgery for idiopathic MH. Firstly, it is very difficult to get an image on the 1st postoperative day under gas tamponade; shots under gas were taken by experienced skilled hands with Optovue Angiovue System (OCTA) in the postoperative first day control, the prone position requirement was removed for patients who had their macular holes closed. Patients whose MHs were not closed were invited for follow-up on day 3 and were recommended to remain prone during this time. Preoperatively, first and third month postoperatively best corrected visual acuity (BCVA), MH closure time, FDP

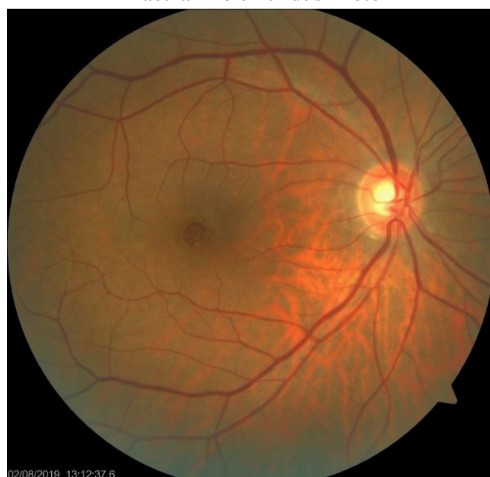duration, and surgical success rate were all recorded.

Results: Thirty patients had phacovitrectomy + ILM peeling + SF6 tamponade, while 14 had vitrectomy + ILM peeling + SF6 tamponade. The mean minimum diameter of MHs was 376.72 ± 69.18 micron (258-526). Postoperatively, 38/44 MHs closed on the first day, four on the third day, and two on the first week. There were 25 MHs in stage two (56.8%), 17 in stage three (38.63%), and two in stage four (4.54%). Furthermore, it was noted that all patients whose MH did not close on the first postoperative day had non-combined vitrectomy surgery.

Conclusion: OCTA guided FDP gives good outcomes in MH surgery, and with the help of OCTA, postoperative prone position time can be shortened, which does not cause macular hole recurrence and is more suitable for patient comfort.

Keywords: Optical Coherence Tomography Angiography, Macular Hole, Vitrectomy

Macular Hole Fundus Photo



Macular hole appearance

Postoperative 1st day OCTA findings

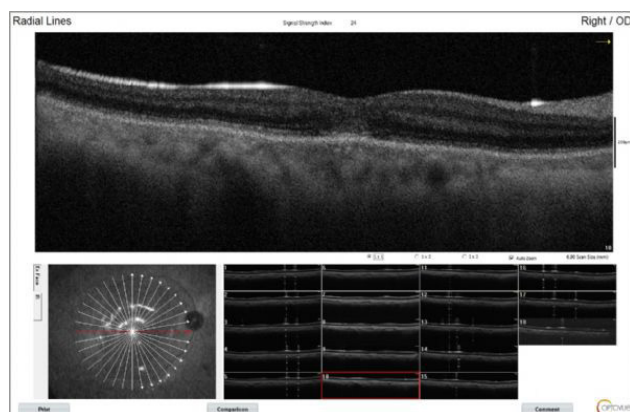


Image on the 1st postoperative day under gas tamponade

[Abstract:0353]

Direct Laser Photocoagulation of the Retinal Pigment Epithelium: A Novel Method to Seal Retinal Breaks during Pars Plana Vitrectomy for Retinal Detachment

Du Shu, Yang Xun
Suzhou Lixiang Eye Hospital

Purpose: To examine the clinical effectiveness of employing direct retinal pigment epithelium (RPE) laser photocoagulation to create chorioretinal adhesion around the retinal breaks.

Methods: Twenty eyes of 20 patients were included in the study; all eyes had rhegmatogenous or combined rhegmatogenous-tractional retinal detachment. Direct RPE laser photocoagulation during vitrectomy, using spots of 100-150 mJ for of 120-200 ms duration, was performed in the area where the edges of each retinal break would settle following retinal reattachment. The thickness of the neuroretina over the treated area was compared to that measured after traditional transretinal laser photocoagulation.

Results: The mean follow-up time was 24 (11-46) months. Postoperatively, an ophthalmoscopically visible pigmentary reaction developed over the treated area, except for a single eye where the retinal break was located in an area of myelinated nerve fibres. There were no serious complications, and the retinas in all 20 eyes remained reattached. The mean best-corrected visual acuity (BCVA) at the final follow-up was significantly higher than that before surgery ($p=0.001$). The thickness of the neuroretina at 1 month after surgery greatly differed between areas of direct versus transretinal laser photocoagulation: 217 μ m in the former and 104 μ m in the latter group.

Conclusion: The efficacy of direct RPE photocoagulation in retinal break sealing equals the effect of traditional transretinal photocoagulation, but without risking damaging the neurosensory retina, and the laser application is not hindered by retinal opacities.

Keywords: Retinal detachment; vitrectomy; direct RPE laser photocoagulation

[Abstract:0354]**Use of Subretinal BBG Dye to localise a missing retinal hole in Rhegmatogenous Detachment**

Nishikant Jaywant Borse

Insight Eye Clinic, Mumbai

Locating and treating a retinal hole or tear is a key step in a Retinal Detachment surgery.

Unfortunately the retinal break cannot be localised in about 5-7% of cases of Rhegmatogenous Retinal Detachment. This incidence is much more in pseudophakics and in eyes with hazy media.

This presentation demonstrates a technique whereby the BBG dye is injected after vitrectomy, in the subretinal space in cases of Retinal Detachment with non localisation of the retinal break. PFCL is then injected into the vitreous cavity. The PFCL increases the hydrostatic pressure of the sub retinal space there by leading to egress of the BBG stained dye from the retinal breaks. This helps in locating the retinal break and subsequently towards a successful surgery

Keywords: Rhegmatogenous Retinal Detachment, Missing Retinal Break, Subretinal BBG dye

[Abstract:0360]**ROP behind the scene imaging !**

Sara Ahmed Tawfik

Al-Ferdaws Eye Hospital, Egypt

Oral presentation demonstrating different modalities in neonatal imaging in retinopathy of prematurity with available affordable devices and techniques including smart phone, VR headset and indirect ophthalmoscope recording

Keywords: ROP imaging

[Abstract:0364]**Photoreceptor Integrity Following Pars Plana Vitrectomy for Primary Rhegmatogenous Retinal Detachment**

Mehmet Onen, Muzaffer Sahin, Zeliha Yazar

Ankara Bilkent City Hospital, Department of Ophthalmology

Purpose: To investigate the factors affecting the macular photoreceptor integrity following pars plana vitrectomy for macula-off rhegmatogenous retinal detachment.

Methods: Two hundred consecutive patients (200 eyes) with primary macula-off rhegmatogenous retinal detachment underwent 25-gauge pars plana vitrectomy with subretinal fluid drainage through peripheral retinal break(s) (PRB) (n=60), posterior retinotomy (PR) (n=40), or perfluorocarbon liquid (PFCL) (n=100) were retrospectively included in the

study. Standard silicone oil (n=100), heavy silicone oil (n=20), and C3F8 gas (n=80) were used as intraocular tamponade. Best corrected visual acuity (BCVA) and spectral-domain optical coherence tomography were performed preoperatively and at 3 and 6 months postoperatively. Disruption of macular photoreceptor integrity (DMPI) was defined as discontinuity of the external limiting membrane, ellipsoid zone and interdigitation zone at 6 months.

Results: Disruption of macular photoreceptor integrity was detected in 56 (28%) eyes. A statistically significant correlation was found between worse visual acuity and DMPI (p=0.0001). Sixty eyes (30,5%) had vision-limiting maculopathies. These were epiretinal membrane (20%), cystoid macular edema (9%), macular holes (1%), and macular neovascularization (0,5%). BCVA significantly better in patients without DMPI and maculopathy (p=0.0001). There was an association between drainage technique and macular PID. PFCL-assisted drainage is associated with DMPI (p=0.03). There was an association epiretinal membrane and DMPI (p= 0.01). There was no an association between type of intraocular taponade and DMPI.

Conclusion: PFCL-assisted drainage is associated with worse visual acuity and greater risk of DMPI compared with PRB or PR. The reason for worse visual acuity in eyes with epiretinal membrane after vitrectomy is outer retinal band discontinuity.

Keywords: Rhegmatogenous retinal detachment, photoreceptor integrity, subretinal fluid drainage

[Abstract:0365]**Primary pars plana vitrectomy with silicone oil tamponade for rhegmatogenous retinal detachment**

Halit Eren Erdem, Mehmet Orkun Sevik, Aslan Aykut, Özlem Şahin

Department of Ophthalmology, School of Medicine, Marmara University, Istanbul, Turkey

Purpose: To assess the anatomical and functional outcomes of primary pars plana vitrectomy (PPV) with silicone oil (SiO) tamponade for the management of rhegmatogenous retinal detachment (RRD) in our tertiary referral center.

Method: Fifty-nine eyes of 59 patients treated with PPV and SiO tamponade for RRD between January 2020 and September 2022 were included in this retrospective study. Patients' demographic and clinical (follow-up time, the time interval between symptom to surgery, macular status [on or off], proliferative vitreoretinopathy [PVR] grade, the extent of retinal detachment, SiO duration, and pre- and postoperative best-corrected visual acuity [BCVA, logMAR]) characteristics were evaluated. An attached retina six months after SiO removal is considered an anatomical success.

Results: The mean age of the patients was 58.1 ± 11.7 (range, 19-77) years (22 [37.3%] females) with a mean follow-up time of 14.1 ± 7.6 (range, 6-34) months. The mean symptom-to-surgery

interval was 20.9±19.3 (range, 3-86) days. Preoperatively, 18 eyes (30.5%) were macula-on, and PVR grades were A, B and C in 15 (25.4%), 29 (49.1%) and 15 (25.4%) eyes, respectively. The primary and overall anatomical success rates were 91% and 100%, respectively, with 5 eyes (9%) requiring secondary surgeries. Preoperative BCVA was significantly increased from 2.03±1.14 to 0.74±0.68 logMAR postoperatively ($p<0.001$). Macula status, PVR grade, intraoperative 360-degree laser, retinal detachment extent, number of retinal tears and duration of intraocular SiO did not have any significant importance for anatomic and functional success.

Conclusion: Primary PPV with SiO tamponade is successful in obtaining functional and anatomical success for RRD. The parameters for anatomic success are investigated widely and it is known that PVR grade is highly important but our study did not find this relation. This may be due to the low number of patients, or the advanced PPV techniques. However, RRD is still a challenging disease for vitreoretinal surgeons.

Keywords: pars plana vitrectomy, rhegmatogenous retinal detachment, silicone oil

[Abstract:0366]

Long-Term Surgical Outcomes of Pediatric Retinal Detachment Associated with Congenital Glaucoma

Merve Ozbek, Ozgur Artunay

Prof. Dr. N. Reşat Belger Beyoğlu Göz Eğitim ve Araştırma Hastanesi, İstanbul

Purpose: Congenital glaucoma is an extremely rare disease with an incidence of one in 10,000 live births. Increasing axial length due to congenital glaucoma predisposes to retinal thinning and retinal detachment (RD). The aim of the present study is to determine the long-term surgical outcomes of pediatric RD associated with congenital glaucoma.

Methods: This study was a retrospective, nonrandomized study including pediatric patients who underwent vitrectomy with silicone oil injection for RD associated with congenital glaucoma. Ocular examination reports and surgical findings of all patients were analyzed to assess for the anatomical and functional outcomes of the surgical intervention.

Results: The study included 20 eyes of 20 children. Mean age was 10.33 ± 3.94 years, range 5–16 years. Mean axial length of these eyes was 25.91 ± 2.15 mm (range, 20.31–28.91 mm). In 11 eyes, the IOP was <6 mmHg at the time of RD diagnosis. The mean LogMAR visual acuity improved from 2.13±0.45 to 2.02±0.61 ($P=0.477$) after surgery. Mean follow-up period was 24.05 ± 11.05 months, range 12–48 months. During the follow-up period, 6 patients (30%) had revision of surgery due to recurrent RD. Globe survival has been achieved in 19 out of 20 eyes (95%).

Conclusion: Ocular comorbidities like corneal scarring, amblyopia, or glaucomatous optic atrophy play a significant role in limiting final visual outcomes. Despite the poor visual

prognosis of RD repair in eyes with congenital glaucoma, globe survival can achieve in such cases. Globe preservation has an important impact on patients' quality of life, psychological and social functionality. Moreover, ambulatory vision can be preserved in most eyes.

Keywords: Congenital glaucoma, Pars plana vitrectomy, Retinal detachment

[Abstract:0371]

Comparison of two sutureless techniques of scleral fixation of intraocular lens in surgical aphakia

Gamze Dereli Can, Busra Yorulmaz, Eda Nur Gonultas Ozkan, Mehmet Erol Can

Department of Ophthalmology, Bursa City Hospital, Bursa, Türkiye

Purpose: To compare the anatomical and clinical outcomes, and complications of two different sutureless scleral fixation of intraocular lens implantation (SFIOL) techniques, that is, Yamane's flanged SFIOL technique and Canabrava's four-flanged SFIOL technique.

Materials-Methods: Thirty-two eyes of 32 patients who presented with aphakia due to the complicated cataract surgery and/or mechanical complications of IOL and underwent SFIOL with more than 6 months of follow-up were examined retrospectively. Group 1 ($n=19$) consisted of patients underwent flanged SFIOL using the Yamane technique; group 2 ($n=13$) consisted of patients underwent four-flanged SFIOL using the Canabrava technique. Improvement in logMAR visual acuity (VA), postoperative spherical equivalent (SE) and cylindrical refraction, IOL centration on slit-lamp biomicroscopy, complications, presence of dysphotopsia, and topographical aberrations were compared at 6 months follow-up.

Results: The indications for surgery were aphakia ($n=14$), dislocated/subluxated IOL ($n=16$) and aphakia accompanying with retinal detachment ($n=2$). The mean postoperative logMAR VA were 0.6±0.7 and 0.6±0.5 in group 1 and group 2, respectively ($p=0.8$). In both groups, VA was above 0.3 logMAR only in one third of the cases. The mean postoperative SE was 0.0±2.7 D in group 1, 0.2±1.3 D in group 2 ($p=0.8$). The mean postoperative cylindrical refraction was -3.0±1.8 D in group 1, -2.6±2.4 D in group 2 ($p=0.6$). Postoperative transient corneal edema was seen in 4 (21%) eyes of group 1, mild IOL decentration was seen in 2 (15.3%) eyes of group 2. Positive dysphotopsia was seen in 3 (15.7%) eyes of group 1 and 4 (30.7%) eyes of group 2. No cases of hypotony, conjunctival erosion, haptic exposure or endophthalmitis were encountered throughout the follow-up.

Discussion: In our small study cohort, both sutureless flanged IOL fixation techniques considered to be resulted in good visual rehabilitation and IOL centration in patients with previous complicated surgery.

Keywords: Sutureless scleral fixation, double-needle four-flanged technique, intraocular lens dislocations

[Abstract:0375]**Psychophysical assessment of low visual function in patients with retinitis pigmentosa with the full-field stimulus threshold (FST) test**

Ayşe Oner, Neslihan Sinim Kahraman
Acibadem Health Group

Purpose: The full-field stimulus threshold (FST) test was developed to evaluate the efficiency and safety of treatments of hereditary retinal diseases. In this study we used FST test in patients with retinitis pigmentosa (RP) and compare the results with perimetry and electrophysiological tests.

Methods: 17 RP patients and 7 normal subjects were tested during the study. Routine examination and ophthalmological tests including perimetry, optical coherence tomography, flash and multifocal electroretinography and FST tests were performed to the RP patients. Controls received FST test after routine ophthalmological examination. The FST test was performed to measure the perception threshold of white or chromatic ganzfeld flash stimulations. The rods are more sensitive to blue than to red stimuli and cones have the same sensibility for red and blue stimuli. The FST test was done monocularly on the MonCvONE-CR systems manufactured by Metrovision with dilated pupil after 30 min dark adaptation. Full field flashes were presented every 3 seconds. The patient press the button every time he/she perceives light.

Results: We were able to obtain reliable thresholds of FST from all study eyes which has flat flash electroretinography. The mean values of white, blue and red FST were significantly lower in patients compared with the controls (Table 1) ($P<0,05$). There was a correlation between FST test values, visual acuity and Ring 4-Ring 5 amplitudes of mfERG. There was not a correlation between FST values and perimetry and central ring amplitudes.

Conclusion: The FST test is a fast and a reliable exam which can be done in subjects with poor visual acuity and / or reduced visual field. The results of this study confirm that the FST can measure retinal sensitivity in severely affected RP subjects with flat flash ERG and can be used for evaluation of treatment results in hereditary retinal diseases.

Keywords: Full field stimulus threshold test, low vision, Retinitis Pigmentosa

[Abstract:0376]**Comparison of Macular Slippage Rates in Patients with Primary Rhegmatogenous Retinal Detachment Undergoing Pars Plana Vitrectomy with Silicone-Oil or Perfluoropropane Gas Tamponade**

Sadık Altan Ozal, Hakan Baybora, Muzaffer Said Guler, Ece Ozal, Murat Karapapak, Serhat Ermis, Yusuf Cem Yilmaz, Serife Ciloglu Hayat
Basaksehir Cam and Sakura City Hospital, Department of Ophthalmology, Istanbul, Türkiye

Purpose: This retrospective study aimed to compare the rates of macular slippage (MS) in patients with primary rhegmatogenous retinal detachments (RRD) who underwent pars plana vitrectomy (PPV) with either silicone-oil or perfluoropropane (C3F8) gas tamponade, and to investigate whether there is a correlation between MS and metamorphopsia.

Methods: Thirty-two patients with macula-off RRD who underwent a single 25-gauge PPV surgery were included in the study. The patients were divided into two groups based on the endotamponade used during surgery: silicone-oil (n=17) or 14% C3F8 gas (n=15). Demographic information, preoperative, intraoperative, and postoperative characteristics were collected from medical records. Ophthalmological examinations were conducted, and data on various parameters, including liquid perfluorocarbon (PFCL) use, drainage retinotomy, MS rates, and presence of metamorphopsia, were assessed.

Results: Liquid PFCL was used in all cases, and no patient underwent drainage retinotomy. MS was detected in 8 eyes (53.3%) in the gas tamponade group and 3 eyes (17.6%) in the silicone-oil group, and the difference between the two groups was statistically significant ($p=0.001$). In both groups, 2 patients with MS suffered from metamorphopsia, but no significant correlation was found between MS and metamorphopsia in the gas group ($p=0.59$).

Conclusion: The study suggests that MS rates differ significantly between patients who underwent PPV with silicone-oil or C3F8 gas tamponade. Furthermore, while MS was observed in both groups, it may not always result in metamorphopsia in most patients after detachment surgery.

Keywords: macular slippage, macula-off retinal detachment, silicone-oil

[Abstract:0378]
Henle’s Fiber Layer volumetric analysis in patients with cone dystrophy

Cem Kesim¹, Selahattin Cansiz², Umit Yasar Guleser¹,
Cigdem Gunduz Demir², Murat Hasanreisoglu¹
¹Department of Ophthalmology, Koç University School of Medicine
²Department of Computer Engineering, Koç University Faculty of Engineering

Purpose: To evaluate Henle’s Fiber Layer (HFL) thickness and volume parameters in patients with cone dystrophy with directional optical coherence tomography (D-OCT).

Methods: Macular 20x20° standard and D-OCT images were acquired from patients diagnosed with hereditary cone dystrophy with evident foveal ellipsoid zone defect in OCT, and age-matched healthy controls. HFL thickness and volume parameters were calculated from manual segmentation through D-OCT images and comparative analysis is performed.

Results: Twelve eyes of 6 patients were compared to 12 eyes of 6 age-matched healthy controls (mean age: 33.7±13.7 and 29.7±16.5 years respectively; P=0.064). Patients had lower total HFL volume (0.48±0.07 against 0.72±0.05 mm³; P<0.001) and mean HFL thickness (17.0±2.5 against 25.4±1.7 µm; P<0.001) than healthy controls. HFL parameters in patients for both central subfield (volume: 0.01±0.00 mm³; thickness: 7.0±4.7 µm) and inner 1-3 mm ETDRS zone (volume: 0.09±0.02 mm³; thickness: 15.0±3.6 µm) were significantly lower than those in healthy controls for subfield (volume: 0.03±0.00 mm³; thickness: 48.8±5.6 µm) and inner 1-3 mm ETDRS zone parameters (volume: 0.26±0.01 mm³; thickness: 41.1±2.1 µm) (all P<0.001), while no difference was found in outer 3-6 mm ETDRS zone between patients (volume: 0.38±0.05 mm³; thickness: 18.1±2.6 µm) and healthy controls (volume: 0.42±0.03 mm³; thickness: 19.8±1.7 µm) (P=0.094 and 0.083, respectively).

Conclusion: HFL assessment might be a useful OCT biomarker in patients with cone dystrophy. HFL thinning is observed in foveal and parafoveal areas of patients with cone dystrophy, while perifoveal HFL parameters are found comparable to healthy controls.

Keywords: cone dystrophy, Henle’s Fiber Layer, directional optical coherence tomography

[Abstract:0382]
Surgical outcomes for the treatment of tractional and degenerative lamellar macular holes

Caitlin Howey¹, Dong Young Park²
¹Warwick Medical School, University of Warwick
²University Hospitals Coventry & Warwickshire NHS Trust

Purpose: To compare the functional and anatomical results of internal limiting membrane (ILM) peeling during vitrectomy for tractional lamellar macular hole (LMH) with degenerative LMH associated with epiretinal proliferation.

Methods: A prospective comparative study of standard ILM peeling in a consecutive cohort of patients with lamellar macular holes over a 24-month period. Spectral-domain optical coherence tomography and Early Treatment Diabetic Retinopathy Study letters best-corrected visual acuity were assessed preoperatively and 6 months postoperatively. Fourteen eyes with tractional LMH (Group T) were compared with thirteen eyes with degenerative LMH (Group D) who received gas tamponade with prone posture postoperatively.

Results: Groups showed no significant preoperative differences. After 6 months, best-corrected visual acuity improved in both Group T and Group D (respectively, -0.20 lower (-0.38 to 0) and -0.17 lower (-0.42 to -0.02) logMAR; P < 0.001) There were no significant differences in mean change in BCVA from baseline to 6 months follow-up between two groups.

Conclusion: ILM peeling with a gas tamponade and prone posture is a feasible treatment option for degenerative LMH, yielding improvements in best-corrected visual acuity. Further studies are needed to optimize this new surgical approach. An appropriately powered randomized controlled study is warranted.

Keywords: lamellar macular hole

Descriptive statistics for tractional LMH vs degenerative LMH vs ERM

Descriptive Statistics for Tractional LMH vs Degenerative LMH vs ERM

	Tractional LMH	Degenerative LMH	ERM
N	14	13	97
Mean age	70.9 yrs, (Range: 54-82)	72.1 yrs, (Range: 57-84)	71.6 yrs, (Range: 24-92)
	SD: 8.7	SD: 7.5	SD: 10.2
Male : Female	5 : 9	5 : 8	62 : 35
Phaco / Cataract Sx combined	10 out of 14 (71.4%)	9 out of 13 (69.2%)	55 out of 97 (56.7%)
Mean baseline BCVA	logMAR 0.45 (SD 0.21)	logMAR 0.35 (SD 0.24)	logMAR 0.51 (SD 0.35)
Mean final BCVA	logMAR 0.23 (SD 0.22)	logMAR 0.18 (SD 0.20)	logMAR 0.28 (SD 0.20)
Mean change in BCVA from baseline to 6 month follow-up	-0.20 lower (better) (-0.38 to 0)	-0.17 lower (better) (-0.42 to -0.02)	-0.22 lower (better) (-1.9 to 0.3)

Mean change in best corrected vision

Figure 1

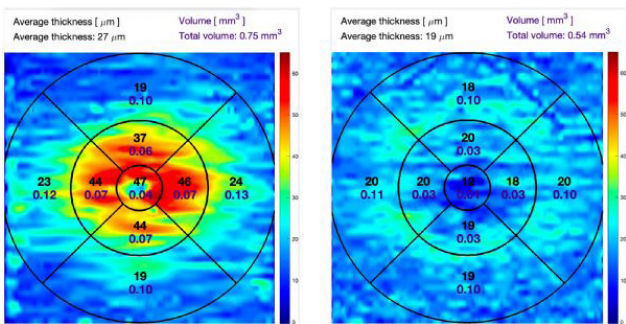


Figure 1: Henle’s Fiber Layer heat maps for right eyes of a healthy control (left) and a patient with cone dystrophy (right).

[Abstract:0383]

Posterior Segment Parameters after Uveitic Cataract Surgery: A Prospective Study with 1-Year Results

Nur Doğanay Kumcu¹, Melike Balıkoğlu Yılmaz²,

Semiha Özgül³, Seher Sarıtepe Imre⁴

¹Ophthalmology, Manisa State Hospital, Manisa, Turkey

²Ophthalmology, İzmir Katip Celebi University, Atatürk Training and Research Hospital, İzmir, Turkey

³Biostatistics and Medical Informatics, Ege University, Turkey

⁴Ophthalmology, Atatürk Training and Research Hospital, İzmir, Turkey

Purpose: To evaluate the changes in posterior segment after uncomplicated cataract surgery in uveitic patients.

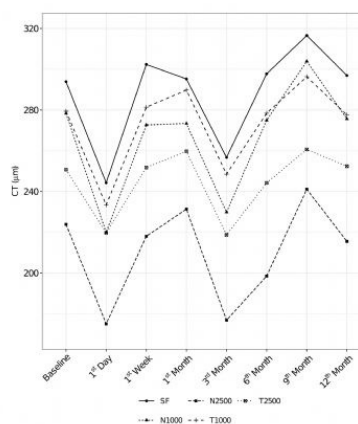
Methods: Retinal nerve fiber layer thickness (RNFLT), ganglion cell layer thickness (GCLT), central macular thickness (CMT), and choroidal thickness (CT) of 38 eyes of 28 patients were measured pre- and postoperatively on day 1, week 1, and month 1, 3, 6, 9, and 12.

Results: The mean preoperative RNFLT in operated eyes was $91.50 \pm 13.28 \mu\text{m}$. Mean RNFLT increased after surgery. But in the pairwise comparisons, the increase in the mean RSLTK value between the 1st day and the 1st month was only significant (93.78 ± 13.30 vs. $96.40 \pm 15.15 \mu\text{m}$, $p=0.0059$). Mean CMT baseline value was $250.71 \pm 55.19 \mu\text{m}$ in operated eyes. Although the measurements taken at all postoperative times were higher than the baseline value of mean CMT, no difference was detected between the paired comparisons performed at 7 different times. GCLT in all quadrants at 12th month were found to be higher than baseline value. In paired comparisons, the significant difference was found the average GCLT between the 1st day-1st month, 1st day-3rd month and 1st day-6th month ($p=0.0139$, $p=0.0096$, and $p=0.0099$, respectively). When 5 measurement points are examined in CT; in the operated uveitic eyes, a decrease was observed in all points on the 1st day compared to baseline. Subsequently, the CT increased and approached the baseline value in the 1st month.

Conclusion: During the 1-year follow-up, the effect of cataract surgery on the retina and choroid in uveitic eyes was most evident at the postoperative month 1.

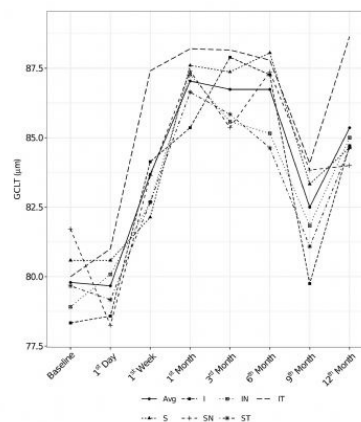
Keywords: Central macular thickness; choroidal thickness; uveitic cataract surgery

figure 1



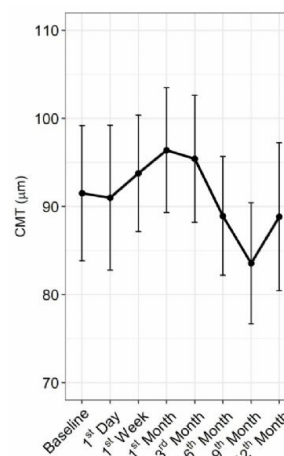
Mean choroidal thickness (CT) at 5 different measurement points at follow up times

figure 2



Mean ganglion cell layer thickness (GCLT) at 6 different points at follow up times

figure 3



Mean retinal nerve fiber layer thickness (RNFLT) at follow up times (error bars show the 95% confidence intervals of the means in the figure)

[Abstract:0385]**CME: Traditional approaches still work**Ivan Fišer*Lexum Eye Clinic Prague*

In diabetic CME or in CME after branch or central retinal vein occlusion, intraocular anti-VEGF or steroid injections are now often used as primary treatment. However, multiple, often never-ending injections with the risk of tachyphylaxis can be avoided using focal laser or vitrectomy with ILM peeling. Case-reports of DME and CME in BRVO and CRVO will be presented with questions to the audience about the preferred treatment, and our solutions, i.e. treatment using focal laser or ILM peeling, will be demonstrated. Take home message: the treatment of CME should always be individualised. In DME, precise focal laser can bring a permanent benefit without the use of intraocular injections. ILM peeling can bring a similar benefit in both DME and post-RVO CME.

Keywords: Macular edema, focal laser, ILM peeling

[Abstract:0386]**Pulmonary function in school-age children following intravitreal injection of bevacizumab for retinopathy of prematurity**

Wei Chi Wu¹, Ching Yen Huang², Shen Hao Lai³,
Hsiao Jung Tseng⁴, Tsung Chieh Yao⁵

¹*Department of Ophthalmology, Chang Gung Memorial Hospital, Taoyuan, Taiwan; College of Medicine, Chang Gung University, Taoyuan, Taiwan*

²*Department of Ophthalmology, Chang Gung Memorial Hospital, Taoyuan, Taiwan*

³*Division of Pulmonology, Department of Pediatrics, Chang Gung Memorial Hospital, Taoyuan, Taiwan; College of Medicine, Chang Gung University, Taoyuan, Taiwan*

⁴*Biostatistics Unit, Clinical Trial Center, Chang Gung Memorial Hospital, Taoyuan, Taiwan*

⁵*Division of Allergy, Asthma, and Rheumatology, Department of Pediatrics, Chang Gung Memorial Hospital, Taoyuan, Taiwan; College of Medicine, Chang Gung University, Taoyuan, Taiwan*

The effect of anti-vascular endothelial growth factor on neonatal lung development was inconclusive. To evaluate pulmonary function in school-age children who have received intravitreal bevacizumab (IVB) for retinopathy of prematurity (ROP), our study separated 118 school-aged children into three groups: full-term control children (group 1), preterm children who had not received IVB treatment (group 2) and preterm children with ROP who had received IVB treatment (group 3). Pulmonary function was measured by spirometry and impulse oscillometry. Pulmonary function was significantly better in group 1 than in groups 2 and 3 (all $p < 0.05$ in forced vital capacity (FVC), forced expiratory volume in 1 second (FEV1), forced expiratory flow between 25% and 75% of FVC (FEF25-75), resistance of the respiratory system at 5 Hz and difference between R5 and R20 (R5-R20)). There were no statistically significant differences between group 2 and group 3 in FVC, FEV1, ratio of FEV1 to FVC, FEF25-75, resistance of the respiratory system at 20

Hz, reactance of the respiratory system at 5 Hz or R5-R20. Our study revealed that preterm infants receiving IVB for ROP had comparable pulmonary function to their preterm peers who had not received IVB treatment by school age.

Keywords: Impulse oscillometry; intravitreal bevacizumab; Pulmonary function; Retinopathy of prematurity; Spirometry; Vascular endothelial growth factor

[Abstract:0388]**Decoding the enigma of Serpiginous Choroiditis**Kshitij Raizada*Dr. Raizaday Eye Centre, Bareilly, India*

Serpiginous Choroiditis is a disease characterised by inflammation of the choroid, which is often bilateral and asymmetric in presentation. The disease leads to loss of choriocapillaries and atrophy of the overlying Retinal Pigment Epithelium.

There has been a significant evolution in the understanding of Serpiginous Choroiditis over the past few decades. The disease was initially considered to be largely Autoimmune in nature. But, with time, Serpiginous Choroiditis was found to be associated with infectious etiologies like Tuberculosis and Syphilis. Such variants of Serpiginous Choroiditis which are associated with infectious etiologies are addressed as Serpiginous like Choroiditis. It is of utmost importance to differentiate between autoimmune Serpiginous Choroiditis from the infectious Serpiginous like Choroiditis before aggressive immunosuppression can be initiated.

Although patients having Serpiginous like Choroiditis due to tuberculosis are usually younger, with unilateral affliction and significant vitritis and multifocal lesions, there is a considerable overlap with the autoimmune Serpiginous Choroiditis and its quite difficult to make the correct diagnosis based on morphological features alone.

Therefore ancillary investigations like Mantoux, QuantiFERON gold become relevant especially in tuberculosis endemic regions like India.

The role of routine ocular investigations like OCT, FFA, ICG and FAF can't be emphasised more to arrive at the correct diagnosis and to differentiate between Active and Healed variants of Serpiginous Choroiditis.

With this presentation, through discussion of a number of cases, we aim to demystify all the conundrums pertaining to Serpiginous Choroiditis and elucidate its pathogenesis, clinical features, diagnosis and treatment

Keywords: Serpiginous Choroiditis, Serpiginous like Choroiditis, Tuberculosis

[Abstract:0393]**Comparative study of commonly used intraocular forceps**Mahmut Dogramaci*Princess Alexandra hospital NHS trust, Harlow, Essex, UK*

Purpose: To establish the subtle differences in performance, accuracy, precision, and safety of three commonly used intraocular forceps tip designs and compare their effectivity and safety margins.

Method: Internal limiting membrane pinch peeling procedure was modelled using a purpose-built robotic system with a biomimetic membrane resembling retinal layers. Perforation pressure through excessive denting, dent versus lift curve, maximum lift and safety ranges for 27-gauge Eckardt End-Gripping, 27-gauge Katalyst stiff Dex and a 27 gauge Ultrapeel forceps were compared.

Result: Perforation pressure through excessive denting was 15.85, 15.48 and 16.01 mg for Eckart, Katalyst and Ultra-peel forceps. Dent versus lift curve showed an initial positive then a plateau and finally a negative correlation. Maximum lift was 15.29, 8.43 and 11.13 mg for Eckart, Katalyst and Ultra-peel. The minimum dent to achieve the maximum lift was 1.10, 10.42 and 0.97mg for Eckart, Katalyst and ultra-peel. The safety range was 14.75, 5.06 and 15.04 mg for Eckart, Katalyst and ultra peel.

Conclusion: Forceps tip design has significant influence on its overall performance and safety. Manufacturers should be encouraged to provide detailed and objective data in relation to the performance of their designs to enhance safety and ensure appropriate usage. Currently no objective data is being provided by any forceps manufacturers.

Keywords: Forceps, vitrectomy, macula

[Abstract:0394]**Long-term outcomes of intravitreal dexamethasone implant for the treatment of macular edema following surgical removal of epiretinal membranes**

Ali Altan Ertan Boz, Erkan Çelik, Mahmut Atum, Burçin Çakır, Nilgün Özkan Aksoy, Sedat Özmen, Emine Doğan
Sakarya University Training and Research Hospital, Ophthalmology, Sakarya, Turkey

Purpose: The aim of this study was to investigate the efficacy and safety of intravitreal dexamethasone implant (DEX) for the treatment of macular edema after pars plana vitrectomy (PPV) for epiretinal membrane (ERM) removal. Setting/Venue: Sakarya University Medical Education and Research Hospital, Department of Ophthalmology

Methods: This retrospective study included 42 patients who were diagnosed with macular edema after PPV for

ERM removal and who were treated with either intravitreal DEX (n=22) or were observed without intervention (n=20). Changes in best-corrected visual acuity (BCVA) and central macular thickness (CMT) were assessed 1, 6, and 12 months after treatment.

Results: Patients treated with intravitreal DEX showed significant improvement in BCVA and reduction in CMT at months 1, 6, and 12 after treatment, while patients in the control group did not show statistically significant improvement. The two groups differed significantly in terms of BCVA and CRT at all time points of the follow-up period, in favor of the DEX group. Twelve of the 22 patients treated with intravitreal DEX needed only one implant until month 12; ten of the patients needed 1 repeat injection of DEX. No serious adverse events were observed in any group.

Conclusions: Intravitreal DEX was found to be effective and safe for the treatment of macular edema after PPV for ERM removal. However, some eyes may require repeated injections to maintain the visual and anatomical outcome.

Keywords: Epiretinal membrane, intravitreal dexamethasone, macular edema

[Abstract:0395]**Comparison of the efficacy and ocular surface effects of sutureless, suturation and external diathermy techniques used in the closure of sclerotomies after 25-Gauge Transconjunctival Vitrectomy**İrfan Akalın¹, Fatma Bağcı², Mehmet Yasin Teke²¹*Health Sciences University, Trabzon Kanuni Training and Research Hospital*²*Health Sciences University, Ankara Ulucanlar Eye Training and Research Hospital*

Purpose: To evaluate the efficacy of sutureless (rubbing), suturing and external diathermy techniques used in the closure of leaky sclerotomies after 25-gauge (25G) Transconjunctival Vitrectomy (TV) and to compare their effects on the ocular surface.

Metod: 60 eyes of 60 patients who underwent 25G TV in a tertiary eye hospital were studied prospectively. Three different techniques used for closure of sclerotomies were compared. Intraocular pressure (IOP), hypotonia, complications related to hypotonia and ocular surface dynamics (Tear break uptime (TBUT), Oxford scoring and OSDI questionnaire) were evaluated on postoperative (postop) 1st day, 1st week and 1st month.

Results: 17 (28.3%) sclerotomies were closed with sutureless, 23 (38.3%) with diathermy, and 20 (33.3%) with suturing. The mean IOP values on the postop 1st day were found to be significantly lower in the sutureless group (13.8 ± 5.8 mmHg) compared to the diathermy (19.7 ± 8.3) and suture (21.3 ± 9.6) groups ($p=0.014$). There was no significant difference between

the 1st week and 1st month IOP values ($p>0.05$). Hypotony (IOP < 6.5 mmHg) was observed in 3 (5 %) patients in the sutureless group and in 1 (1.6%) patient in the diathermy group on the postop 1st day. It was not observed in any group at 1 week and 1 month. No hypotony-related complications were recorded. Compared the mean Oxford scores, postop 1st day sutureless group (0.61 ± 0.96) was found to be significantly lower than the diathermy (1.32 ± 0.7) and sutured (1.78 ± 1.03) groups ($p=0.002$), but no significant difference 1st week and 1st month. There was no significant difference between the groups in FBUT and OSDI scores in all postop periods.

Conclusion: The risk of early postoperative hypotony should be kept in mind when closing sclerotomies with the sutureless technique. Postop efficacy and ocular surface parameters are evaluated, external diathermy is a useful alternative to suturing.

Keywords: Vitrectomy, Diathermy, Sclerotomy

[Abstract:0399]

Internal limiting membrane (ILM) surgery for myopic traction maculopathy (MTM): Should macular buckle be abandoned ?

Hassan Ali Mortada

Faculty of medicine, department of ophthalmology, Cairo university

Between 2019 and 2022, ILM surgery was used to treat 70 eyes with MTM, including 25 eyes with myopic macular hole retinal detachment (MMHRD), 20 eyes with myopic foveoschisis (MF) and 25 eyes with myopic macular holes (MH) without RD. Fovea sparing ILM peeling was used to treat eyes with MF and multilayer ILM flaps were used to treat the MHs. in MMHRD & MH without RD. In all cases the peeling was extended to the edge of the posterior staphyloma.

The tamponade was air in eyes with MF & MH without RD and eyes with MMHRD limited to the posterior staphyloma. Silicone oil (SiO) 2000 Cs. was used to tamponade eyes with MMHRD extending to the periphery. The latter was removed after 30 days. MH closure, retinal reattachment and flattening of the MF could be achieved in all cases (100%). Anatomical success was associated with functional improvement by at least 2 lines. Additional macular buckle was not needed to achieve retinal reattachment or closure of the MH in any eye.

The ILM is the most rigid structure at the posterior pole of eyes with pathological myopia complicated with MTM. Extended peeling of the ILM to the edge of posterior staphyloma helps to increase the mobility of the posterior retina and can adapt to the concavity of the staphyloma. Multilayer ILM flaps help closure of MHs. Techniques of LM surgery (Fovea sparing ILM peeling, multilayer flaps and extended ILM peeling to the edge of staphyloma) are effective for treating MTM (100%). Additional macular buckle was not needed in any case.

Keywords: ILM surgery in MTM

[Abstract:0409]

Posterior Segment Intraocular Foreign Bodies: a 10-Year review

André Ferreira¹, Bruno Barbosa Ribeiro², João Miguel Coelho², Angelina Meireles³

¹Department of Ophthalmology, Centro Hospitalar Universitário de Santo António; Unit of Anatomy, Department of Biomedicine, Faculty of Medicine of University of Porto

²Department of Ophthalmology, Centro Hospitalar Universitário de Santo António

³Department of Ophthalmology, Centro Hospitalar Universitário de Santo António; Department of Ophthalmology, Instituto de Ciências Biomédicas Abel Salazar, University of Porto

Introduction: An intraocular foreign body (IOFB) requires urgent treatment to prevent blindness or globe loss. It is estimated that IOFBs account for 16-41% of all open-globe injuries. Most IOFBs are metallic (75-85%) and the most common location is the posterior sacuiegment. Young men are most affected, accounting for more than 90% of cases in some series.

Purpose: To assess the clinical presentation of patients with posterior segment IOFBs (PS-IOFB) and establish prognostic factors for visual acuity compatible with driving ($\geq 20/40$).

Methods: Retrospective cohort study enrolling all PS-IOFB submitted to surgery at Centro Hospitalar Universitário do Porto (CHUPorto), Portugal in the last decade. A multivariable analysis was performed using a logistic regression model through a stepwise approach to fit the model and find independent clinical predictors for final visual acuity.

Results: This study included 71 eyes of 71 patients. Most patients were adult males (87.3%) of working age (mean \pm SD age 41.48 \pm 13.49). Home (33.8%) and industrial places (32.4%) were the most common locations and 30 traumas occurred during working-related activities. Six (8%) patients presented with endophthalmitis, 48% had lens injury and 24% presented with retinal detachment. The majority (85.9%) of IOFB were metallic. The median (interquartile range) time to first procedure was 1 (0-2) days, with most IOFB (60.6%), retrieved at that moment. In this study, good presenting visual acuity (VA), lens sparing, and absence of retinal detachment were associated with good final VA.

Conclusion: Open-globe injuries with IOFB are a public health issue that impose preventable social and economic burden as it affects mostly working-age subjects. Hence, early intervention and preventive measure are of uttermost importance to prevent social and visual disability.

Keywords: Ocular trauma; Intraocular foreign body; Retinal detachment

[Abstract:0410]**Human Amniotic Membrane Graft for Chronic Macular Hole**

Cumali Degirmenci, Filiz Afrashi, Melis Palamar, Deniz Bağcı, Cezmi Akkin

Ege University, Faculty of Medicine, Department of Ophthalmology, Izmir, Turkey

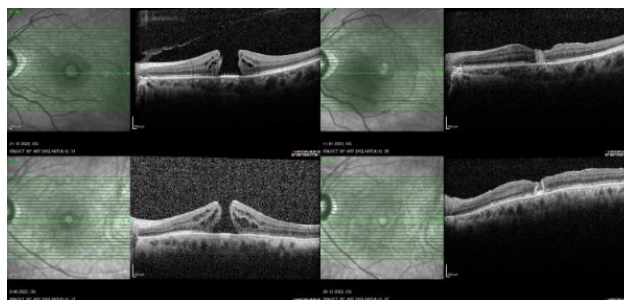
Purpose: Full thickness macular holes are age related neurosensory defects in foveal region. The patients suffer from metamorphopsia and low visual acuity. Macular hole closure rate is low in chronic and large macular holes. Many surgical techniques were defined to overcome this problem. In the current study we aimed to present anatomical and functional results of human amniotic membrane graft in chronic macular hole closure.

Methods: Nine eyes of 9 patients were included in the study. All patients underwent a detailed ophthalmic examination. Macular holes were detected upon fundus examination and were graded with spectral domain optic coherence tomography. Basal hole diameter and minimum hole diameter were measured with a caliper. Six patients underwent a 25-gauge pars plana vitrectomy and internal limiting membrane (ILM) peeling as first line treatment. The remaining 3 patients had previous pars plana vitrectomy and ILM peeling for macular hole which was not sufficient for macular hole closure. In all surgeries after ILM peeling an amniotic membrane graft was placed into the macular hole and underneath the borders of the macular hole neighboring neurosensory retina. Air tamponade was used for all patients.

Results: The median age of the patients was 66 ± 6.54 (54-76) years, male/female ratio was 3/6. The median best corrected visual acuity was 0.01 ± 0.11 (0.001-0.3) preoperatively and increased to 0.075 ± 0.14 (0.04-0.4) postoperatively ($p < 0.01$). The median basal hole diameter was 1142 ± 123.52 (1064-1390) micrometer and the minimum hole diameter was 704 ± 95.77 (517-813) micrometer. Anatomic closure rate was 100% with single surgery. (Figure 1)

Conclusion: Macular hole closure rate is very high with the current surgical techniques. Human amniotic membrane is also an efficient technique for macular hole closure. The anatomical success in the current study was %100. Further studies are needed to evaluate structural changes after human amniotic membrane use.

Keywords: amniotic membrane, macular hole, pars plana vitrectomy

Figure 1

Preoperative and postoperative OCT images of 2 patients

[Abstract:0419]**Diabetic vitrectomy: mind set & different attack strategies**

Ahmed Mansour

Ophthalmology department, Ain Shams University, Cairo, Egypt

A presentation to show Mind set in vitrectomy for diabetics setting a fixed plan for every case together with different attack strategies that should be tailored to each membrane

Keywords: Diabetic, Vitrectomy, Strategies

[Abstract:0423]**Macular hole RD: our novel flower petal technique**

Ahmed Mansour, Ahmed Habib, Youssef Fouad

Ophthalmology department, Ain Shams University, Cairo, Egypt

We demonstrate a modified internal limiting membrane (ILM) inverted flap technique for closure of macular holes (MHs) concurrent with rhegmatogenous retinal detachment in myopic eyes. Multiple ILM flaps were created in a flower-petal configuration around the MH over the detached retina after shallowing the retina as much as possible. Traction was always in a direction that allowed the optic disc to act as an anchor to limit iatrogenic breaks and to bridge the hole with multiple, more secure flaps should one of the flaps revert or break away. The technique proved safe and efficient in MH closure in our series of eight cases. The modification described provides an effective approach for challenging myopic cases in which ILM flap creation is needed over a detached retina.

Keywords: Hole, RD, flower

[Abstract:0427]**ROP surgery in older children: Can you help ??**Ihab Saad Othman¹, Ihab Saad Othman²¹Faculty of Medicine, Cairo University, Cairo, Egypt²EyeWorld Hospital, Giza, Egypt

Purpose: Stage 5 ROP is a real challenge to pediatric retina surgeons. Challenges in dissection of epiretinal membranes render the success dismal.

Methods: In 10 patients with 5b and 5c ROP and a mean age of 3 years (range 1-6 years), careful examination of the ciliary body region using the Retcam is carried out to identify a gap between the retrolenticular membrane and the CB. Identification of a clear zone warranted careful membrane dissection from the periphery to the center. using deep scleral indentation. Otherwise, the membrane was dealt with centripetally.

Results: in presence of a clear peripheral zone at CB, dissection could successfully remove the membrane in 6 out of 6 cases. In one case a CB detachment occurred with minimal traction on CB. In 4 out of 4 cases, the centripetal dissection was successful in removing the membranes, however a peripheral skirt could not be totally removed in 2 cases due to opacities present in the corneal periphery (stage 5c), and a peripheral break occurred in one case as well. Retina was found to be retracted away from the peripheral tractional membrane in 6 cases, allowing successful membrane dissection. Complete retinal flattening could be achieved in 4 cases, and partial retinal repositioning in one more case. Ambulatory vision could be appreciated in these 5 cases.

Conclusion: Careful observation of the nature of the retrolenticular membrane is important to identify and optimally manage such complicated cases. The retcam has a definite role in examining the very periphery of the retina. We can help.

Keywords: ROP elderly children

[Abstract:0428]**The war on retinopathy of prematurity: where are we now?**Lalit Agarwal¹, Nisha Agrawal²¹Birat Eye Hospital, Biratnagar²Taparia Eye care, Biratnagar

Purpose: To estimate the burden of retinopathy of prematurity (ROP) in Nepal using the data (demographic, incidence and treatment data) from a ROP program in India and to calculate the yearly burden of preventable blindness due to ROP. Also to assess the facilities of ROP screening and treatment in Nepal via an online survey.

Methods: An impact assessment in Nepal was constructed using ROP screening model of tele-ROP service in India. The number of potential blind babies were listed, the burden

of blindness prevented in blind-per-years (BPYs), and the increase in load due to increase in survival and institutional deliveries calculated. An online survey was done amongst the Ophthalmologists of Nepal to assess the ROP screening and treatment facilities in Nepal

Results: Population of Nepal is 29.6 million. Number of babies eligible for ROP screening annually is 82,880. Number of babies admitted to NICU is 53,872 out of which 39,261 babies are likely to survive and need ROP screening. Extrapolating data from KIDROP study, 8990 babies would develop some stage of ROP and 1401 babies would require treatment in Nepal yearly. The burden of preventable blindness in BPY that can be saved is 130.83 million USD/ year. As per the responses from the online survey, only around 3500 babies were screened for ROP per year leading to a gap of 35761 babies missing the screening and 1276 babies likely to miss treatment.

Conclusion: The burden of ROP is high in Nepal. A tele-ROP service can be used as a cost effective model in Nepal to decrease the burden of preventable blindness and the financial burden caused by it.

Keywords: Retinopathy of prematurity, preventable blindness, Nepal

[Abstract:0429]**Double rectangular scleral mesh (DRSM) for severely subluxated/Dislocated IOLs: A closed vitrectomy approach**Ihab Saad Othman¹, Ihab Saad Othman²¹Faculty of Medicine, Cairo University, Cairo, Egypt²EyeWorld Hospital, Giza, Egypt

Purpose: severely subluxated and dislocated IOLs months to years following IOL implantation represent a challenging entity. We present a new technique of ab interno approach to replace the IOLs in the sulcus following PPV.

Methods: 6 cases of severely subluxated/dislocated IOLs are presented. Age range from 8-60 years. All cases were myope with no capsular support. Fashioning of a double rectangular scleral mesh was done on an intact eyeball before placing the sclerectomies. PPV was performed and the IOL was replaced and tethered onto the scleral mesh in 5 cases. One IOL was exchanged as it was damaged.

Results: Mean follow up was 104 months. Visual acuity improved in all cases. IOLs were all centered in the sulcus onto the DRSM. Complications included transient ciliary body bleeding in 2 cases and IOL haptic rupture necessitating IOL replacement on the scleral mesh.

Conclusion: DRSM offered an adequate support for IOL replacement and placement under a closed system. This offers IOL stability

Keywords: Scleral mesh, IOL

[Abstract:0437]**Complex syndromic pediatric rhegmatogenous retinal detachment: Surgical technique & outcome**

Hassan Ali Mortada

Faculty of medicine, department of ophthalmology, Cairo university

110 eyes with syndromic pediatric complex rhegmatogenous retinal detachment (RRD), operated during the period from 2018 - 2022 were included in this study. It include eyes with stickler, Marfan, Konblock, congenital coloboma, Dawn and congenital retinoschisis. The RRD was associated with giant retinal tears, multiple retinal breaks, posterior retinal breaks, extensive lattice and/or proliferative vitreoretinopathy (PVR). The surgical technique included lensectomy with or without IOL implantation, 23 or 25 G. vitrectomy, unimanual or bimanual detachment & peeling of the posterior hyaloid (PH), extended internal limiting membrane (ILM) peeling, excision of the basal vitreous gel, retinal reattachment with PFCL, endolaser and direct PFCL/silicone oil 2000 Cs. exchange. Scleral buckle (SB) was used in the first 15 eyes. Retinotomy/retinectomy was only performed when mandatory SiO was removed after achieving complete stable retinal attachment.

The number of operations needed to achieve retina reattachment, including SiO removal was 2 in almost 60%, 3 in 24%, 4 in 5%, 5 in 6.3%, and 6 operations in 5%. SiO could not be removed because of hypotony, persistent RD or PVR in 3%. The challenges involved in such cases include: PH detachment & peeling, ILM peeling, recurrent proliferation. Extended ILM peeling is a safeguard against epimacular recurrent proliferation. No difference was noted between eyes with or without SB.

Keywords: Syndromic pediatric RRD, extended ILM peeling

[Abstract:0438]**Outcomes of pars plana vitrectomy for retinal detachment with chorioretinal coloboma**

Murat Arıcı, Anıl Korkmaz, Onur Altaş, Halil Özgür Artunay

Department of Ophthalmology, Beyoglu Eye Training and Research Hospital, Istanbul, Turkey

Purpose: To evaluate the outcomes of retinal detachment (RD) in eyes with chorioretinal coloboma managed by pars plana vitrectomy (PPV) and silicone oil tamponade.

Methods: This retrospective study included 14 eyes of 12 patients who underwent PPV for RD with chorioretinal coloboma. All of the patients underwent PPV with silicone oil tamponade. Only in 2 patients additional scleral buckle procedure was needed.

Results: The mean age of 12 patients was 35.5±19.9 years. The average follow-up period was 42.5±38.7 months. Preoperatively, the mean visual acuity (VA) was logMAR 2.00 and final VA was logMAR 1.10. The single operation

anatomic success rate was in twelve eyes (85%). There were two eyes with anatomical success after the second PPV. The average silicone oil tamponade duration was 16.1±3.3 weeks. Cataract extraction was performed in 4 eyes as an additional surgical intervention.

Conclusion: PPV and silicon oil tamponade can be considered as an effective surgical intervention in retinal detachment with chorioretinal coloboma.

Keywords: Chorioretinal coloboma; Retinal detachment; Pars plana Vitrectomy

[Abstract:0443]**Surgical results of Vitrectomy for Central Retinal Artery Occlusion**

Nishikant Jaywant Borse

Insight Eye Clinic, Mumbai, India

Central Retinal Artery Occlusion (CRAO) is a potentially blinding condition with very limited treatment modalities. This paper describes the results of using Vitrectomy with Arterial Sheathotomy as an effective method for restoring perfusion in cases of CRAO in 55 cases.

Results

Overall results - Perfusion could be restored partially/ completely in 47% eyes with the retinal circulation improving immediately within 48 hours.

Presence of abnormal glial tissue – In some patients with abnormal glial tissue on the optic disc Removal of glial tissue in helped restore the retinal perfusion immediately.

Visualization of the embolus – On massaging the central retinal artery the embolus could be visualized migrating to the periphery in 40% of the eyes with CRAO. In some cases the embolus had to be manually broken into pieces to relieve the arterial occlusion

Visual acuity - In the where the treatment was successful, visual acuity gradually improved over a period of 4-6 weeks. A total of n=8 eyes where the duration of presenting symptoms less than 24 hours, had a visual acuity improvement up to 20/80 – 20/120. n=14 eyes had a visual acuity improvement up to 20/200 by 6 weeks postoperatively. n=4 eyes had a minimal visual improvement up to 20 /400. The latter groups were eyes with duration of symptoms more than 24 hours, with a mean duration of 38 hours.

Safety evaluation [at 3 months follow up] - None of these eyes had any retinal complications, endophthalmitis or any vitrectomy related complications.

Keywords: CRAO, Vitrectomy, Restoration of Perfusion

[Abstract:0444]**Modified Inverted Internal Limiting Membrane Flap Technique in Macular Hole Surgery: Perfluorocarbon Iron**

Muhammed Nurullah Bulut, Kezban Bulut, Dilber Çelik Yaprak
Kartal Dr Lutfi Kırdar City Hospital

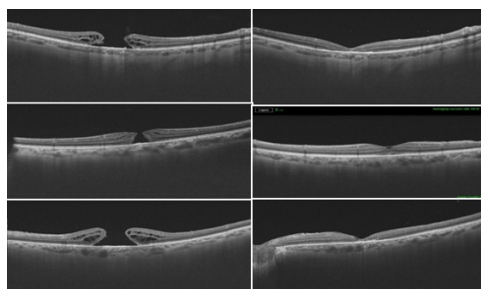
Purpose: The inverted internal limiting membrane (ILM) flap technique in macular hole (MH) surgery was first introduced in 2010. In the inverted ILM flap technique, the flap can be dislodged during air-fluid exchange. Various techniques have been described to prevent this situation. In this study, we aim to describe the modified reverse ILM flap technique with the help of perfluorocarbon (PFC) weight for flap stabilization in macular hole surgery.

Methods: Five patients with idiopathic macular hole were included. Preoperative macular hole diameters of the patients were measured with spectral domain optical coherence tomography (SD-OCT). Preoperative and postoperative 2nd month best corrected visual acuity (BCVA) and macular hole status were evaluated. After the PFC is placed on the flap during the surgery, it is aimed to move the globe right-left, up and down, and ironing it with the weight of the PFC, to rub the folded part of the flap and make it more stable.

Results: Five eyes of 5 patients were included in the study. The mean MH diameters were 581 microns. While the mean BCVA was 1.44 in pre-op according to LogMAR, it was increased as 0.84. After the operation, it was observed that the MH was closed in all of them. All eyes had a near-normal foveal contour in relation to the postoperative restoration of the foveal contour observed with OCT.

Conclusion: Approximately 14% of reverse ILM flaps are dislodged during fluid-air exchange. To solve this problem, retinal adhesive such as OVD was used to stabilize the ILM flap. We have seen that the modified technique we developed is advantageous in preventing the flap from detaching during fluid-air exchange. In this technique, it becomes easier to stabilize the ILM flap with PFC movement and weight. Therefore, folding the ILM flap with the perfluorocarbon ironing technique may be an easy, safe and effective method for the treatment of MH.

Keywords: ILM inverted, flap, perfluorocarbon

SD-OCT

Preoperative and postoperative OCT images of patients

[Abstract:0455]**A Novel Mobile Application for Communication between Parents, Pediatricians and Ophthalmologists for Retinopathy of Prematurity Screening Providing Artificial Intelligence Assisted Retinopathy of Prematurity Diagnosis**

Ayşe İpek Akyuz Unsal¹, Zehra Aysun Altıkardeş², Emine Çifci Cırık², Sezer Kartal², Şengül Özdek³, Hüseyin Baran Özdemir³, Buket Doğan⁴, Duygu Güler¹, Tuğçe Küçükbalcı³, Sema Dündar¹

¹Department of Ophthalmology, School of Medicine, Aydın Adnan Menderes University, Aydın, Türkiye

²Department of Computer Technologies, School of Technical Sciences, Marmara University, Istanbul, Türkiye

³Department of Ophthalmology, School of Medicine, Gazi University, Ankara, Türkiye

⁴Department of Computer Engineering, Faculty of Technology, Marmara University, Istanbul, Türkiye

Purpose: to raise awareness of ROP among parents, pediatricians and ophthalmologists, keep them in communication for early diagnosis and treatment.

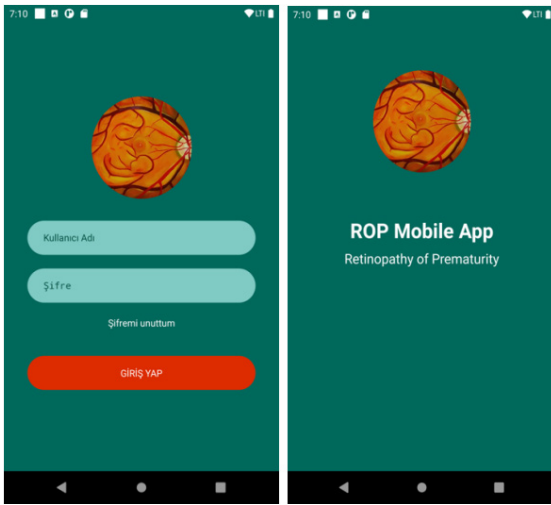
Methods: A mobile application and web platform running on devices with Android and iOS operating systems were developed. Parents, pediatricians and ophthalmologist are users. These users are presented with different screens where they can perform different functions. Appointment module infrastructure was designed according to the patient data. Ophthalmologist can view the appointments on the agenda, reach patients through their appointments, view past visits of patients, and define notifications for patients. In addition, ophthalmologist can upload the fundus photo of the patient to the web platform, and save the artificial intelligence assisted analysis result of the photo, see the patient's past visit by entering the appointment date (Fig 1,2). Parents could enter the application after logging in and view the upcoming, past and current appointments, notifications, announcements on the main screen and the notes written by the doctor over the appointments.

Results: We performed a demo registration with one of our patient who was at a NICU clinic of an other hospital in our city by the help of a neonatologist. She upload the application and helped the parents register to the web platform. System gave an appointment and it was approved by the ophthalmologist. After the ROP examination, the fundus photo of the infant was uploaded to the web platform and it was analysed with the help of AI and gave the risk percent for being ROP (Fig 3).

Conclusion: This pilot study and live demo encouraged us to use this mobile application and web platform in routine ROP screening. So, we look forward to using this mobile application in routine ROP screening programs after obtaining necessary permissions and authorizations from government agencies due to personal data protection law.

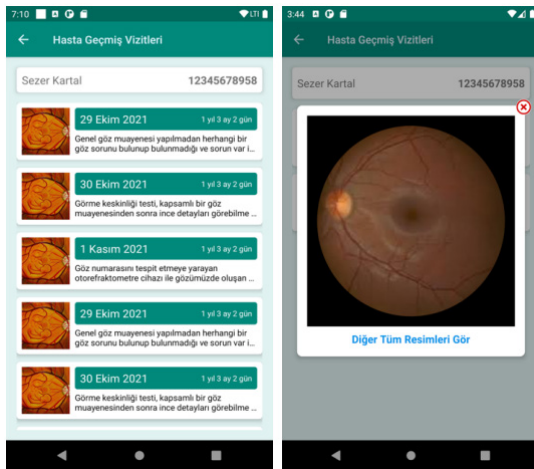
Keywords: Mobile application, Retinopathy of prematurity, screening

Figure 1



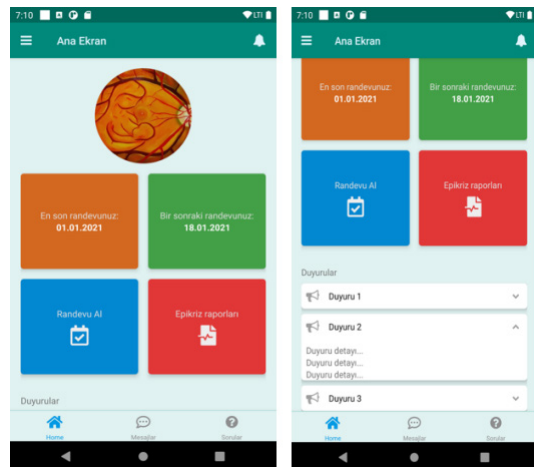
Login and Splash Screen

Figure 2



Patient Past Visits Screen

Figure 3



Main Screen of Patients

[Abstract:0456]

Congenital X-Linked Retinoschisis: Surgical Needs And Outcomes In Long Term A Retrospective Multicenter International Study

Huseyin Baran Ozdemir¹, Sengul Ozdek¹, Muna Bhende², Pramod Bhende², Parveen Sen², Dhanashree Ratra², Debarati Dasgupta², Mary Elizabeth Hartnett³, Joseph Simonett³, Abhishek Das⁴, Shunji Kusaka⁵, Philip Ferone⁶

¹Department of Ophthalmology, Gazi University Faculty of Medicine, Ankara, Türkiye

²Sankara Nethralaya Main Hospital, Chennai, India

³Moran Eye Center, University of Utah Health, Utah, USA

⁴Aravind Eye Hospital, Coimbatore, India

⁵Kindai University, Japan

⁶Long Island Vitreoretinal Consultants, New York, USA

Purpose: To evaluate the need for vitreoretinal surgery (VRS), surgical success and factors affecting success in patients with congenital X-linked retinoschisis (CXLR).

Methods: This retrospective, multicenter study included the data of invited vitreoretinal centers after approval of the local ethics committee. A data set including demographic characteristics, phenotype, frequency of follow-up/surgery, surgical techniques and details, pre- and post-operative visual acuity and complications of CXLR patients followed-up were obtained and analyzed.

Results: The data of 635 eyes of 318 patients were analyzed. Mean follow-up time was 115±93 months. VRS was performed to 112 of 589 eyes (17.6%). VRS was needed most frequently in patients with complex phenotype ($p<0.0001$). The mean age at initial presentation was 9 (1-32) years and statistically significantly lower in patients requiring VRS ($p=0.004$). The median baseline visual acuity (VA) of the patients underwent VRS was 1.6 LogMAR. The most common cause for VRS was rhegmatogenous retinal detachment (RRD) (61.6%) and retinal tears were most common in the lower quadrant (44.9%). The most frequent surgical procedure was vitrectomy alone in the whole group (42.9%), however, combined vitrectomy with scleral buckle was the most common procedure in eyes with RRD (53.8%) ($p<0.0001$). Inner-wall retinectomy was performed in 59.5% of eyes. Silicone oil tamponade was used in 53.8% of the eyes. Anatomical success was achieved in 68.5% with single surgery which was statistically higher in eyes with RRD and vitreous hemorrhage. There was no statistically significant difference between the surgical method and maneuvers, and tamponade used in achieving success with a single surgery ($p>0.05$). Final anatomical success rate was 92.8%. The median final VA improved to 1.3 LogMAR ($p=0.006$).

Conclusions: VRS for CXLR related problems results in relatively lower single surgery anatomical success rates which increase to satisfactory levels with multiple surgeries. Functional results are also guarded in these eyes.

Keywords: congenital x-linked retinoschisis, retinal detachment, vitreoretinal surgery

[Abstract:0457]**Outcomes of "minimal drainage" vitrectomy for retinal detachment repair**Ahmed Sallam, Riley Sanders*University of Arkansas for Medical Sciences, Little Rock, USA*

Standard drainage (SD) pars plana vitrectomy for primary retinal detachment involves draining as much subretinal fluid (SRF) to near complete dryness, either with a retinotomy or perfluorocarbon liquid and full exchange of vitreous fluid for gas. We propose a compromise between SD and pneumatic retinopexy, "minimal drainage" PPV (MD). With MD, SRF is drained from the break during fluid air exchange then retinopexy is done followed by gas exchange. No drainage of vitreous cavity fluid is performed.

We retrospectively analyzed sequential primary RRD surgery undergoing either SD or MD for RRD. Slightly expansile gas concentration was used in the MD, 30% SF6 gas (vs 20% in the SD group or 20% C3F8 gas vs. 14% to account for the under drainage of subretinal fluid. Postoperative positioning instructions were the same for all cases - supine on their back for 2 hours then positioning to support the retinal break at night.

There were 20 eyes in the MD group and 20 in the SD. 6/20 (30%) had mac on RD in the MD and 7/20 (35%) had mac on RD in the SD. In the SD, 14/20 (70%) had drainage retinotomy, and in 10/20 (50%) PFCL was used. C3F8 (vs. SF6 gas) gas was used in 20% of the MD and 50% of the SD group. 17/20 (85%) of MD. 14/20 (70%) of SD had primary anatomic success at 3 months ($p=.68$). Retinal displacement on AF was seen in 20% of MD and 40% SD ($p=.19$). ELM/Ellipsoid zone continuity for macula off detachments was 79% for MD and 50% for SD ($p=0.15$).

Minimal drainage of subretinal fluid was at least not inferior to SD in primary re-attachment and retinal displacement rates. This technique provides a simple and efficient option avoiding the need, cost and risks of drainage retinotomy and PFCL use.

Keywords: retinal detachment, pars plana vitrectomy

[Abstract:0461]**Dislocated intraocular lenses - Tips and tricks of removal, repositioning and exchange**Neeraj Sanduja, Charu Malik, Arnoev Sanduja*Vaan Eye and Retina Centre Gurgaon India*

Management options for posteriorly dislocated posterior chamber intraocular lenses include observation, removal, exchange, and repositioning. Many microsurgical techniques have been developed for repositioning posterior chamber implants. These include repositioning into the ciliary sulcus if adequate posterior capsule support present, iris fixation techniques, scleral fixation suturing techniques and suture less glued fixation techniques. The indications, timing, and

techniques for intervention are reviewed in a series of 20 cases with posteriorly dislocated posterior chamber implants. Sutureless glued IOL technique was used in 16 cases with excellent IOL stability and minimal astigmatism. A final visual acuity of 20/40 or better was achieved in 17(85 %) cases.

Keywords: Glued IOL, scleral fixation IOLs

[Abstract:0463]**Long Term OCT Changes After Treatment in Chronic CSCR**Figen Bezci Aygün, Cansev Şekerler, Sibel Kadayıfçılar*Department of Ophthalmology, Hacettepe University, Ankara, Turkey*

Purpose: To analyse long-term OCT changes in patients with chronic central serous chorioretinopathy (CSCR).
Setting/Venue: Hacettepe University School of Medicine

Methods: Twenty-nine eyes of 20 patients with chronic CSCR were included in the study. All subjects underwent ophthalmological examination including enhanced-depth imaging optical coherence tomography (EDI-OCT) (Heidelberg engineering Inc. USA). Central macular thickness (CMT) and sub-foveal choroidal thickness (SCT) recorded at the time of initial diagnosis and at the last visit were evaluated. Presence of pigment epithelial detachment (PED) accompanying serous elevation, neovascularization and choroidal rift at the initial visit were noted. The treatment modalities employed were also recorded.

Results: The study included 9 females and 11 males with a mean age of 55.5 ± 8.8 years. The mean follow-up time was 4.1 ± 2.3 years. For treatment six eyes received topical nepafenac drops, 9 eyes anti-VEGF injections only (8.0 ± 2.3), 7 eyes only photodynamic therapy (PDT) (1.4 ± 0.5), and 7 eyes received PDT and injection. At the initial diagnosis PED, neovascularization, and choroidal rift were detected in 11, 5, 3 eyes respectively. There was a significant reduction in CMT at the last follow-up ($p < 0.001$), but not in SCT. No correlation was found between change in OCT parameters and the treatment modalities.

Conclusion: Though CMT decreased with treatment in chronic CSCR in this study, there was no significant change in SCT.

Keywords: chronic central serous chorioretinopathy, central macular thickness, sub-foveal choroidal thickness

[Abstract:0467]**The emergence of AROP in Bangladesh: A report on the prevalence, treatment and visual outcome of ROP from January 2021-September 2022 in a tertiary hospital in Bangladesh**

Mahjabeen Choudhury, Mostafizur Rahman, Mohammad Malek
Ispahani Islamia Eye Institute and Hospital

The report was prepared by collecting data on babies attending the ROP clinic between January 2021 and September 2022 in the busiest tertiary hospital in Dhaka, Bangladesh's capital. ROP is considered globally one of the leading causes of irreversible blindness. To report the high incidence of Aggressive Retinopathy of Prematurity (AROP) in Bangladesh in premature (less than 37 GA) infants born with low birth weight (less than 2,500 grams) which possibly can be avoided. AROP is the severe form of ROP with rapid progression to an advanced stage along with signs of neovascularization and 'plus' disease. In middle-income countries like Bangladesh, high-quality neonatal services are expanding with better equipment leading to an increase in neonatal survival. Ispahani Islamia Eye Institute and Hospital (IIEI&H) is considered the most preferred referral centre by the NICUs/SCANUs to screen ROP. The study was conducted between January 2021 and September 2022 to report an overview of rapidly increasing numbers of AROP in Bangladesh. In IIEI&H the total number of babies screened was 2,330. The total number of ROP was 1072 (46%). Among the ROP babies, the total number of AROP was 214 (20%). GA was in between 26-35 weeks. Birth weight was between 900-2400 grams. The diagnosis was made between 20-54 days of the age of the babies. All the babies were treated with Injection AntiVEGF and +/- LASER IO followed by visual stimulation therapy with an illumination box. The babies have a good 'fix and follow' vision and can see non-illuminating/ illuminating toys at a 2-meter distance. The study showed timely detection of ROP and its proper management can save the baby from going blind and thus mitigate the socio-economic burden of the community. At the same time, the country needs to develop manpower and more centers to screen and treat ROP.

Keywords: AROP, AntiVEGF, LASER IO

[Abstract:0470]**Retrospective Analysis of Characteristics and Visual Outcomes of Patients with Endogenous Endophthalmitis**

Furkan Cam, Rabia Eroğlu Ayaz, Hande Celiker
Marmara University School of Medicine

Purpose: To investigate the patient characteristics and visual outcomes of patients with endogenous endophthalmitis (EE).

Methods: The medical records of 24 eyes of 16 patients with EE between 2016 and 2022 were reviewed. Collected data included demographic features, systemic conditions, causative

organisms, treatment modalities, and initial and final visual acuities (VA). The effects of evaluated parameters on final VA were analyzed.

Results: The mean age of patients was 63.81 ± 16.24 years (29-84), and 62.5% of patients were female. The most common systemic co-morbidity was diabetes mellitus (31.4%). All eyes underwent empirical intravitreal antimicrobial injections and vitreous tap, the majority of eyes (79.2%) received intravitreal amphotericin B injections. PPV was also performed in 15 eyes (62.5%). Two eyes needed a repeat vitrectomy for proliferative vitreoretinopathy and recurrent intraocular infection. Culture-positive organism was obtained from vitreous sampling in 12 eyes (50.0%) and the majority of these organism were fungi (66.7%). Among fungal isolates, 5 eyes were *Candida* species and 3 were *Aspergillus*. VA could be evaluated in 20 eyes. Fifteen eyes (75.0%) had poor VA (worse than hand motion) at presentation. Improvement in the final VA was observed in 60.0% of these eyes. Eyes with poor initial VA had worse visual outcomes ($p=0.007$).

Conclusions: In this study, 50% of cases were ocular culture-proven, and fungal organisms were the most common causative pathogens of EE. Although EE is a serious sight-threatening condition, appropriate medical and surgical treatment may result in visual improvement. Initial VA was the significant factor related to visual outcomes.

Keywords: Endogenous endophthalmitis, Visual acuity, Fungal endophthalmitis

[Abstract:0471]**Surgical outcome of cabbage leaf technique of ILM peeling in large macular holes**

Neeraj Sanduja, Anisha Seth, Arnoev Sanduja, Charu Malik
Viaan Eye and Retina Centre Gurgaon India

Purpose: Large macular holes have an increased risk of surgical failure with conventional macular hole surgery. Inverted ILM flap technique has been described for large holes with good surgical outcome. However, the technique involves risk of RPE damage and has a learning curve. The authors describe a new technique of inverted ILM flap in large, full-thickness macular holes, in which multiple ILM flaps were inverted over each other and the hole-like cabbage leaves and these flaps were gently placed over the hole.

Method: In this prospective, interventional case series 24 eyes with macular holes larger than 400 μ m were included. All patients underwent 23 gauge pars plana vitrectomy with posterior vitreous detachment and ILM peeling with SF6 gas injection and post-operative prone positioning of one week. During ILM peeling, after trypan blue staining, remnants of ILM attached to the margins of the macular hole were left in place like cabbage leaf with gentle placement of these flaps over macular hole. Fluid-air exchange was then performed. The patients were followed up with respect to visual acuity (BCVA) and SDOCT pictures for 3 months.

Result: The mean age of patients was 62.6 ± 9.9 years. 60%

patients were males while 40% were females. Mean duration of history of decrease in vision was 6.8 ± 4.4 months (Range 3-15 months). Mean baseline BCVA was 0.084 ± 0.04 that improved to 0.28 ± 0.19 at 3 month ($p=0.002$). The mean minimum linear diameter (MLD) was $623.9 \pm 139 \mu\text{m}$ (Range 418-855 μ). The mean macular hole index (MHI) was 0.39 (Range 0.25-0.55). Macular hole closure was observed in 91% of patients in (21 of 23 eyes) at 3 months. None of the eyes showed a decrease in vision.

Conclusion: This technique of leaving a rim of ILM at the edges of macular hole is effective, prevents inadvertent damage to the parafoveal neurosensory retina and subfoveal RPE, and preserves xanthophyll pigment as well.

Keywords: Macular hole, ILM peeling, Cabbage flower technique

[Abstract:0472]

Visual and Clinical Outcomes of Pars Plana Vitrectomy in Patients with Uveitis

Yargı Özkoçak¹, Furkan Çam², Hande Celiker²

¹Beyoglu Eye Training and Research Hospital

²Marmara University School of Medicine

Purpose: To investigate the visual and clinical outcomes of pars plana vitrectomy (PPV) in the management of patients with uveitis.

Methods: This retrospective study included 36 eyes (33 patients) who underwent 23-gauge PPV. All eyes had a minimum of 6 months follow-up. Baseline demographic and clinical features were recorded. Outcome measures were visual improvement (≤ -0.3 logMAR), change in cystoid macular edema (CME), adjunctive systemic medical therapy, early and late postoperative complications, and repeat vitrectomies.

Results: The mean age of patients was 48.52 ± 17.26 years and the mean follow-up duration was 30.94 ± 24.27 months after surgery. The mean logMAR best corrected visual acuity (BCVA) improved from preoperatively 1.36 ± 0.75 to postoperatively 1.08 ± 0.97 ($p=0.06$). Visual improvement was observed in 61.1% of the eyes. CME was detected in 12 eyes (33.3%) preoperatively and in 6 eyes (16.7%) postoperatively. After surgery, 44.1% of patients needed fewer immunosuppressive drugs to control inflammation. The most common early complications were ocular hypertension ($n=7$, 19.4%) and transient hypotonia ($n=4$, 11.1%). Cataract developed in 2 of 6 phakic eyes (33.3%) and retinal detachment with proliferative vitreoretinopathy in 5 eyes (13.9%) following PPV. Seven eyes (19.4%) underwent repeat PPV.

Conclusion: PPV seems to be an effective and safe method for improvement in visual acuity, decrease in presence of CME, and reduction in the need for systemic immunosuppressive drugs. PVR is the most serious complication with poor prognosis that requires repeat surgery in cases of uveitis.

Keywords: Pars plana vitrectomy, uveitis

[Abstract:0479]

The use of artificial intelligence in the retina; Where and how?

Özlem Candan

Ankara Education and Training Hospital

Purpose: The aim of this study was to determine the application of artificial intelligence (AI) in retina and retinal diseases, based on a systematic assessment of the literature

Methods: PUBMED/MEDLINE database was searched from inception to January 2023 using a computer-based search. The key search terms included (((Deep Learning[Title/Abstract]) OR (Machine Learning[Title/Abstract])) AND (retina[Title/Abstract])) OR (((Deep Learning[Text Word]) OR (Machine Learning[Text Word])) AND (retina[Text Word])).

Results: A total of 708 publications, between 2004-2023 years, were identified. 507 studies were in ophthalmology, 452 of which were focused on retina and retinal disease. The studies between 2004 and 2015 were mostly about scaling up retinal images to higher resolutions, artifact removal and making definitive diagnosis, but, the studies conducted after 2016 were also addressed on treatment planning, differential diagnosis and forecasting disease progression and visual outcomes. The most popular topics were the detection and grading of diabetic retinopathy from fundus photographs or OCT images, diagnosis and classification of dry and neovascular age-related macular degeneration, layer segmentation of retina in OCT and OCTA images and the detection of retinal abnormalities in color fundus photographs and OCT images, respectively.

Conclusion: AI, machine learning and deep learning have demonstrated high performance in screening, classification and diagnosis of retinal diseases and will likely play an important role in future clinical ophthalmology practice. However, there is a requirement to create artificial intelligence-specific guidelines for standardization of design, terminology and the measurements of outcomes for upcoming studies.

Keywords: retina, artificial intelligence, ophthalmology

[Abstract:0484]**Hungry Eyes! Management of Live Intravitreal Cysticercus Cyst with Retinal Detachment**

Saurabh Luthra¹, Shrutanjoy M Das¹, Shweta Parakh¹, Vaibhav Bhatt¹, Abhiyaat Chaturvedi¹, Gaurav Luthra², Neeraj Sanduja³, Nishikant Jaywant Borse⁴, Sangeet Mittal⁵

¹Department of Vitreoretina and Uvea, Drishti Eye Institute, Dehradun, India

²Department of Cataract and Refractive Surgery, Drishti Eye Institute, Dehradun, India

³Department of Retina, Vaaan Eye Centre, Gurgaon, India

⁴Department of Retina, Insight Eye Clinic, Mumbai, India

⁵Department of Retina, Thind Eye Hospital, Jalandhar, India

A 13 year old boy presented with live intravitreal cysticercus cyst with RD. After complete IVTA assisted vitrectomy, the live cyst was eaten inside the vitreous cavity. Encirclage, extensive Membrane Peeling, Endolaser to extensive sieve like retinal holes created by the parasite, and silicone oil tamponade was performed. Postoperatively retina remained attached. 3 months later patient underwent cataract surgery. Another 5 months later patient underwent silicone oil removal with Brilliant Blue G and Loop assisted epiretinal membrane and internal limiting membrane peeling, air fluid exchange and C3F8 gas tamponade. At final follow-up at 1 year, best-corrected vision in affected eye was 6/24p, intraocular pressure was normal, PCIOL was in situ with central posterior capsule opening and quiet anterior chamber. Fundus showed attached retina with extensive peripheral scarring in the area of laser. Optical coherence tomography showed flat retina with resolving minimal macular edema.

To report an extremely rare case of bilateral live intravitreal cysticercus cyst. A 26 year old male presented with BCVA OD HMCF & OS 2/60. Fundus showed OU intense vitritis, B/L live intravitreal cysticercus cyst with RD OD>OS. Patient underwent 25G MIVS surgery OS followed by OD. The cyst was eaten with the cutter followed by AFX, EL & silicone oil tamponade. Additional steps in OD included encirclage band, extensive MP, & EL to extensive sieve like retinal holes. Postop. retina remained attached. 3 months later, patient underwent cataract surgery. Another 2 weeks later, patient underwent silicone oil removal with BBG & 25G loop assisted ERM & ILM peeling, AFX & C3F8 gas tamponade. At last followup at 1 year, BCVA was 6/24 OU, fundus showed attached retina with extensive peripheral laser CRA. OCT showed flat macula. Despite the devastation caused inside the vitreous cavity by the parasite, favorable results were achieved after multiple patient interventions.

Keywords: intravitreal cysticercus cyst, 25 G vitrectomy, cysticercosis

[Abstract:0486]**Prominent Henle fiber layer in optical coherence tomography**

Pınar Kaya, Kübra Özdemir Yalçınsoy, Yasemin Özdamar Erol
Etlik Şehir Hastanesi, Göz Kliniği, Ankara

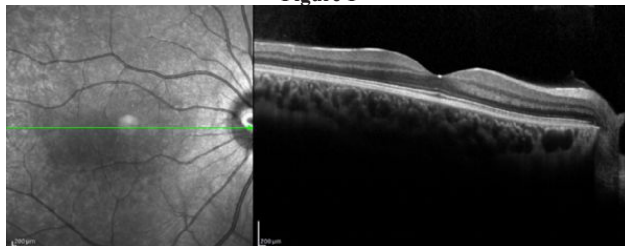Purpose: To evaluate the presence of prominent Henle fiber layer (HFL) using optical coherence tomography (OCT).

Methods: This study included 45 patients who were randomly selected among patients presenting for routine eye control. The inclusion criteria for the participants were a best corrected visual acuity of 1.0 or better refractive error of +4 to -4 diopters (D), <3 D of a cylinder, and normal clinical ocular findings. All patients underwent Spectral-domain OCT imaging after dilation, and only the right eye of each patient was used for evaluation.

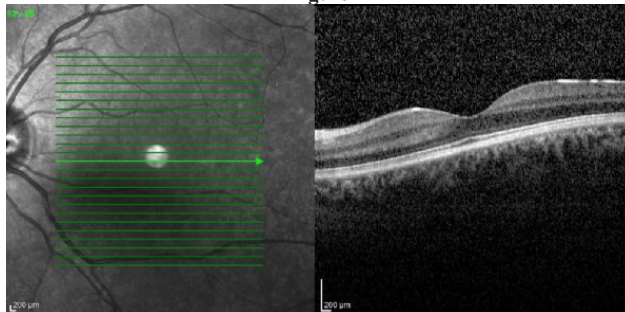
Results: Of the patients included in the study, 29 were female (64.4%), and 16 were male (35.6%). The mean age was 22.0 ± 7.15 (12-44) years. We detected the prominent HFL layer in 17 eyes (18.9%)

Conclusion: Correct detection of the Henle fiber layer is essential in the differential diagnosis of various retinal pathologies. The pupil should be correctly centralized during the OCT imaging so that HFL can be measured accurately.

Keywords: henle fiber layer, optical coherence tomography

Figure 1

Prominent Henle fiber layer in optical coherence tomography image.

Figure

Prominent Henle fiber layer in optical coherence tomography image

[Abstract:0489]**Correlation of the clinical findings with the extend of deep vascular plexus changes in patients with macular telangiectasia type 2: An OCTA study**

Özge Yanık Odaş, Pınar Güran Beğar, Pınar Aydın Ellialtıoğlu, Figen Şermet, Sibel Demirel, Emin Özmert
Department of Ophthalmology, Ankara University School of Medicine, Ankara, Turkey

Purpose: To evaluate optical coherence tomography angiography (OCTA) characteristics of macular telangiectasia (MacTel) type 2 patients at different stages according to the latest MacTel classification.

Methods: This study included 55 eyes of 31 MacTel type 2 cases. Two masked readers graded patients' eyes according to recent multimodal classification of MacTel Research Group. The extend of the deep vascular plexus (DVP) changes on OCTA was classified based on the location. The vessel densities of the retinal capillary plexi were measured.

Results: The mean age was 65.8±9.5 years. According to the recent MacTel classification, there were seven eyes (12.7%) with grade 1 (noncentral ellipsoid-zone break), 24 eyes (43.6%) with grade 2 (central ellipsoid-zone break), two eyes (3.6%) with grade 3 (noncentral pigment), two eyes (3.6%) with grade 4 (OCT hyper-reflectivity), ten eyes (18.2%) with grade 5 (central pigment), and ten eyes (18.2%) with grade 6 (macular neovascularization). On OCTA, DVP alteration was limited to temporal to fovea in 18 eyes (32.7%), spread nasally in 9 eyes (16.4%), spread circumferentially in 18 eyes (32.7%). In the remaining 10 eyes (18.2%), outer retinal neovascularization was observed. There was a statistically significant strong correlation between the severity of the MacTel type 2 and the extend of the DVP changes ($\rho=0.644$, $p<0.001$). The severity grade was also correlated with the superficial and deep parafoveal temporal vessel densities ($\rho=-0.570$, $p<0.001$, $\rho=-0.363$, $p=0.006$, respectively). As the severity of involvement increased, significant rarefactions were observed in both superficial and deep mean parafoveal temporal vessel densities ($p<0.001$, $p=0.019$, respectively).

Conclusion: Vascular and neurodegenerative mechanisms play a role in the pathogenesis of MacTel type 2. According to the results of this study, the structural severity of the disease substantially linked with the extend of the DVP changes. These findings imply that these changes exhibit a parallel course in the natural history of MacTel Type 2.

Keywords: deep vascular plexus, macular telangiectasia type 2, optical coherence tomography angiography

[Abstract:0494]**Yamane Technique Highlights and Our Conclusions**

Alperen Bahar¹, Fahrettin Akay², Yusuf Ziya Güven³

¹Dışkapı Yıldırım Beyazıt Training and Research Hospital, Ophthalmology, Ankara, Türkiye

²Health Sciences University Gulhane Training and Research Hospital, Ankara, Türkiye

³Izmir Katip Çelebi University Atatürk Training and Research Hospital, Izmir, Türkiye

Purpose: To describe our results of the Yamane technique and point out highlights in this technique.

Methods: Yamane sutureless scleral fixation technique was applied to 21 patients with aphakic and intraocular lens dislocation or subluxation. Preoperative BCVA and postoperative 3rd month BCVAs of the patients were noted. In addition, the ages, axial lengths, and post-operative spheric equivalent values of all patients were evaluated retrospectively in the study.

Results: The indication distribution for surgery was aphakia in 14 patients, IOL dislocation in 5 patients, IOL subluxation in 2 patients. The mean age of the patients was 64.1±18.3 years. The mean axial length of the patients was 23.1±1.6 mm. The preoperative BCVA was 0.1±0.05 (Snellen). Postoperative BCVA was 0.7±0.2 (Snellen). The difference between preoperative and postoperative BCVAs was statistically significant ($p<0.05$). Postoperative mean spherical equivalent was -2.75± 1.07 D. A correlation was found between postoperative myopic spherical equivalents in patients with an axial length greater than 23 mm.

Conclusion: Yamane sutureless scleral fixation technique is a new secondary IOL surgery that is effective, fast, and has good short-term results. In this study, a tendency to postoperative myopic spherical equivalents was observed as the axial length increased. To apply scleral fixation 2.25 or 2.5 mm behind the limbus instead of 2 mm behind may prevent tendency to postoperative myopic spherical equivalent in patients with an axial length greater than 23 mm.

Keywords: Aphakia, scleral fixation, yamane technique

[Abstract:0495]**Immediate sequential vitrectomy for diabetic retinopathy**Katarzyna Chwiejczak

Sheffield Teaching Hospitals NHS FT, the University of Sydney

Currently data on immediate bilateral sequential surgery IBSS in diabetic retinopathy is very limited. We present a case scenario when IBSS in severe proliferative diabetic retinopathy (PDR)/ tractional retinal detachment (TRD) can be the approach of choice.

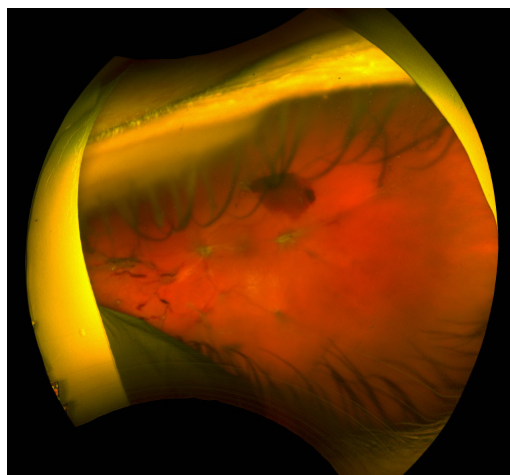
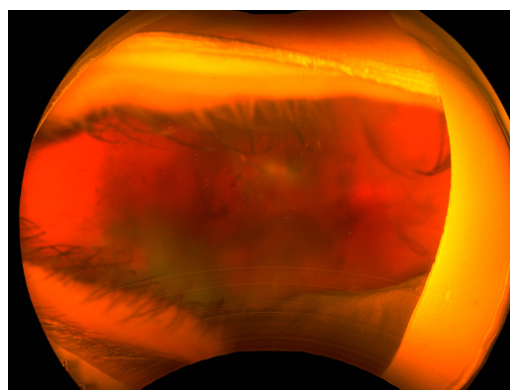
Forty-two year-old poorly controlled type1 diabetic female with asthma, obesity, fibromyalgia and complex social background who presented to Royal Hallamshire Hospital in Sheffield, UK in November 2022 with very poor vision (VA): Hand movements in the right eye (RE) and 1.5logMAR in the left (LE). Intraocular pressures were normal. She had no previous treatments to her eyes. Fundal view was limited due to bilateral vitreous haemorrhage. Ultrasound revealed attached retina in the RE and TRD in the left. She required general anaesthesia (GA) and decision was made to perform IBSS to minimize risks of repeated GA and allow for optimal timing of surgery.

One week later the surgery was carried out using 27G pars plana vitrectomy (ppV) approach. Both eyes required delamination and segmentation and full panretinal photocoagulation. In the RE air was used as a tamponade, while in the LE SF6 gas was used. Both eyes received intravitreal anti-VEGF at the end of surgery as well as subconjunctival cefuroxime and betamethasone. LE was operated as first. Povidone iodine preparation and sterile draping was done separately for each eye. The surgical team re-scrubbed and all the equipment was changed.

At postoperative visit at day 6. BCVA: 0.3 LogMAR in the RE and HM due to gas in the LE.

She could not attend a few subsequent appointments due to ill health and transportation issues, but she reported good vision and ability to watch television and read books two months after the surgery during a telephone consultation. Apart from odd black floater she does not have other issues.

Keywords: diabetic retinopathy, delamination, bilateral sequential surgery

Left Eye preoperatively*Dense vitreous haemorrhage and areas of tractions***Right Eye preoperatively***Dense vitreous haemorrhage obstructing the fundal view***[Abstract:0496]****Surgical Outcomes of Mitomycin C in Severe Proliferative Diabetic Retinopathy Cases**

Gökhan Gürelik, Hüseyin Baran Özdemir, Burak Acar
Gazi Üniversitesi, Göz Hastalıkları Ana Bilim Dalı, Ankara

Purpose: To investigate the effect of adjuvant Mitomycin-C (MMC) use on the anatomical and functional success of vitreoretinal surgery (VRS) in severe proliferative diabetic retinopathy (PDR) cases with tractional or combined retinal detachment (RD).

Methods: The medical records of patients who underwent VRS due to large fibrovascular membranes covering the posterior pole, and secondary RD due to severe proliferative diabetic retinopathy between 2016-2022 were reviewed retrospectively. Demographic and clinical data were analyzed in 2 groups as intraoperative “MMC sandwich technique” with intravitreal adjuvant MMC used (Group A) and not used (Group B).

Results: 23 eyes of 18 patients, 13 of whom were in Group A,

were included in the study and followed for 12 months (9-24 months). The two groups were statistically similar in terms of age, gender, visual acuity (VA) and intraocular pressure (IOP), duration of diabetes, and retinal tear ($p>0.05$). Tractional membrane extent was three quadrants and above at similar rates in both groups ($p=0.356$). Tractional membranes were peeled in all patients during VRS with silicone tamponade. Single surgery success rates were higher in Group A compared to Group B (92% and 70%, respectively), which was statistically significant ($p=0.005$). Although the final anatomic success (retinal attachment) rates were higher in Group A (100%), no statistically significant difference was observed in Group B (90%) ($p=0.091$). Silicone oil removal rates between groups were similar (Group A: 92%; Group B: 80%; $p=0.126$). At the final examination, VA ($p=0.504$) and IOP ($p=0.743$) were statistically similar between the two groups. None of the patients developed complications secondary to MMC use.

Conclusion: In RD cases with severe proliferative diabetic retinopathy with a high risk of developing proliferative vitreoretinopathy, high anatomical success can be achieved with VRS using the MMC sandwich technique and adjuvant MMC without the risk of hypotonia, macular and optic nerve toxicity.

Keywords: severe diabetic retinopathy, mitomycin-c, retinal detachment

[Abstract:0499]

Myopic Macular Hole-Related Retinal Detachment in Children

Huseyin Baran Ozdemir¹, Ebru Barcin¹, Ece Ozdemir Zeydanli², Sengul Ozdek¹

¹Department of Ophthalmology, Gazi University Faculty of Medicine, Ankara, Türkiye

²Freelance Physician

Purpose: To investigate the anatomical-functional results and the factors affecting these results in pediatric patients who underwent surgery for retinal detachment (RD) caused by myopic macular hole (MMH).

Methods: The records of patients with pediatric myopic macular hole secondary RD between 2019 and 2022 were reviewed retrospectively.

Results: Nine eyes of seven patients were included in the study. Five cases were male, and the median age was one year (1-10). The mean refraction (SE) was $-9.2\pm4D$. Preoperative mean VA was 1.84 ± 0.39 logMAR. Total RD was observed in six eyes. Circumferential scleral buckle with vitrectomy was performed in 7 eyes and vitrectomy alone in 2 eyes. The internal limiting membrane (ILM) was peeled off after vitrectomy in 8 eyes. The macular hole was closed with the amniotic membrane in 3 patients. Except for one eye with C3F8, silicone oil was used as tamponade. The total number of surgeries was 2.7 ± 1.3 . The anatomical success rate after primary surgery was 44%, in which the retina was attached, and the macular hole was closed. Repeat surgeries were required in 5 eyes.

At the end of a mean follow-up period of 24 ± 9 months, anatomical success was achieved in 5 eyes (56%). At the last follow-up, three eyes were aphakic, one was pseudophakic, and the other five were phakic. Postoperative VA was 1.3 ± 0.9 logMAR compared to preoperatively. Although there was an increase, it was not statistically significant ($p=0.09$).

Conclusion: In treating RD secondary to pediatric MMD, a lower anatomical and functional success can be achieved with surgery than in adults; more than one surgery and silicone tamponade are often required.

Keywords: myopic macular hole, retinal detachment, pediatric

[Abstract:0501]

Outcomes and complications of combined vs. sequential cataract and pars plana vitrectomy

Ahmed Sallam

University of Arkansas for Medical Sciences

Purpose: To compare the visual outcomes and rates of intraoperative complications in eyes that underwent combined cataract extraction (CE) and pars plana vitrectomy (combined group) with those that underwent sequential surgery (sequential group). Retrospective Multicenter Database study

Design: Retrospective Multicenter Database study

Methods: CE data set pooled from 8 ey centers. The main outcome measures were the mean postoperative visual acuity (VA) and the rate of intraoperative complications in both groups.

Results: 2236 eyes in the combined group and 2270 eyes in the sequential group were included in this study. Mean preoperative VA was 1.0 logMAR in both groups. The mean logMAR postoperative VA was worse in the combined group than in the sequential group ($P<0.0001$) at all timepoints, however, the differences in visual improvement between both groups decreased with longer follow-up time: 1.0 ± 0.7 vs 0.6 ± 0.6 , 0.7 ± 0.6 vs 0.4 ± 0.5 , and 0.7 ± 0.6 vs 0.5 ± 0.5 at 0 to 4 weeks, 4 to 12 weeks, and 12 to 24 weeks, respectively. Proportions of eyes that gained >3 logMAR units were 49% in the combined group and 66.2% in the sequential group ($P<0.0001$). Logistic regression analysis showed that sequential surgery (odds ratio, 2.1) was a predictor for reaching 20/40 vision by 6 months. In the combined group, there was a statistically significantly higher rate of posterior capsular rupture. Surgery for IOL adjustment/ exchange was 2x higher in the combined group ($P<0.0001$).

Conclusions: Postoperative visual gain was less in the combined group with a higher rate of posterior capsular rupture and need for IOL re-adjustments as compared with sequential phacovitrectomy. However, small differences in visual improvements between both groups by 6 months were observed.

Keywords: combined surgery; pars plana vitrectomy

[Abstract:0502] Update on DRCR Clinical Trials, 2023

Ron A Adelman
Yale University School of Medicine

Diabetic Retinopathy Clinical Research Network (DRCR) has conducted several pivotal clinical trials in the recent years. This talk will discuss highlights of these trials.

Keywords: Diabetic Retinopathy, Clinical Trials, DRCR
[Abstract:0503]

[Abstract:0503] Update on Geographic Atrophy

Ron A Adelman
EVRS

There has been extensive research on etiology and management of geographic atrophy. This presentation will discuss recent advances including the first FDA approved medication for geographic atrophy.

Keywords: Geographic Atrophy, AMD

[Abstract:0506] Surgical technique for closed funnel retinal detachment repair

Ahmed Mohamed Habib
Department of Ophthalmology, School of Medicine, Ain Shams University, Cairo, Egypt.

Purpose: To describe a surgical technique and tips for management of Retinal detachment with extensive PVR (closed funnel configuration) in children and young adults

Patients and Methods: Twelve eyes of 12 children and young adults with closed funnel RD were included in this retrospective case series. A similar surgical technique was followed in all cases. The technique consisted of lensectomy, core vitrectomy, epiretinal membrane removal, 360 degrees retinectomy, subretinal membrane removal, perfluoro-carbon liquid injection, internal limiting membrane removal, 360 degrees laser barrage and silicon oil injection.

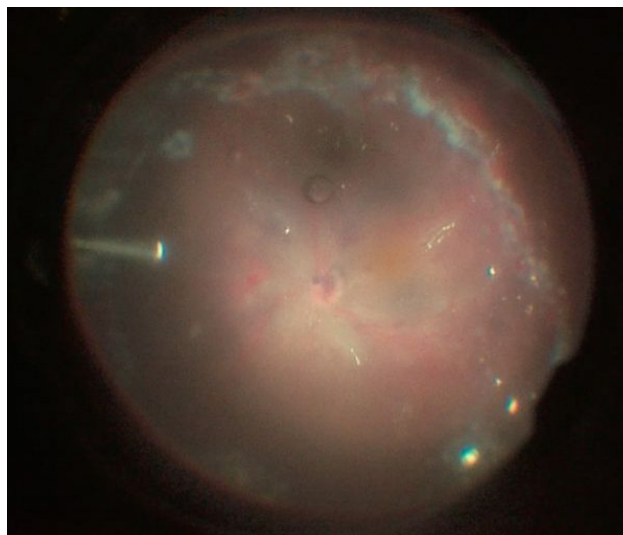
Results: Analyzing the data showed, 11 of the patients were males, 1 was female. Mean age was 11 years (range 3-23). Causes of RD were traumatic (n:4) and high myopia (n:3). Preoperative best corrected visual acuity (BCVA) ranged from light perception (LP) to hand motion (HM) vision. Postoperative BCVA ranged from counting fingers at 50 cm to 0.2. Four patients experienced 1 re-detachment which was repaired. All patients ended up with flat retinæ after at least 6 months of follow up.

Conclusion: The proposed surgical technique for closed funnel RD is reproducible and effective. We recommend this attempt

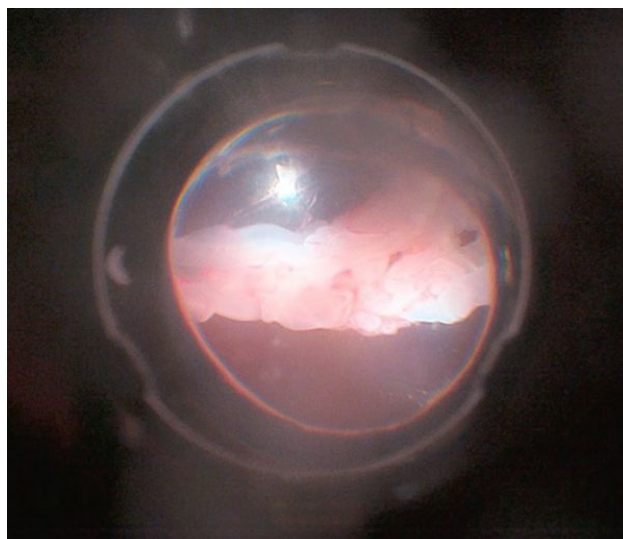for repair of sever complicated forms of RD in order achieve retinal reattachment and to gain at least ambulatory vision for fear of the other eye suffering the same fate.

Keywords: Closed Funnel, PVR, RD

Closed Funnel Post



Closed Funnel Pre



[Abstract:0507]**Psychophysical changes due to visual loss in diabetic patients**

Vladimir Poposki¹, Alejandro Lavaque², Daniela Poposka³, Daniel Vilaplana⁴

¹Parc de Salut Mar, Barcelona, Spain; Institut Català de Retina, Barcelona, Spain;

²Centro de Especialidades Oftalmológicas, Tucumán, Argentina;

³Hospital Municipal de Badalona, Barcelona, Spain

⁴Oftalmo Vilaplana, Sabadell, Spain

Introduction: Diabetic macular edema (DME) constitutes one of the main causes of visual impairment and avoidable blindness in the working-age population. Despite the advances, the associated morbidity is high. Quality of life (QoL) is a concept that represents individual responses to the physical, mental, and social effects that the disease produces in daily life.

Objective: To assess the QoL, to estimate the visual function index, and to determine their mutual influence in patients with moderate DME and severe DME.

Methods: Observational cross-sectional pilot study. 57 patients who met the inclusion criteria were recruited. Three groups of 19 patients each were formed: (I) severe DME; (II) Moderate DME and (III) control group with patients without diabetic ocular pathology. They were given two validated questionnaires to measure subjective functional impairment (visual and general). The two questionnaires were: the visual function loss index, VF-14, and a questionnaire that measures health-related QoL, SF-36. For the statistical analysis, the ANOVA test, the "Post Hoc Tests" Homogeneous Subsets and Multiple Comparisons, and the Pearson Coefficient were used to study the correlation between both questionnaires.

Results: Patients with severe DME have the worst score in Social Function, but also all other dimensions are significantly more affected, except for Emotional Role, which has worse results in moderate DME.

Conclusion: In DME the first to be affected is the Mental Component and then the Physical Component. Likewise, the degree of reduction in Visual Function conditions a worse QoL.

Keywords: Psychophysical changes, Quality of life (QoL), Diabetic Macular Edema (DME)

[Abstract:0508]**Micropulse subthreshold yellow laser in the treatment of central macular edema in central serous chorioretinopathy**

Mladen Zoran Brzakovic¹, Marko Ljubiša Zlatanovic², Maja Ljubiša Zlatanovic², Nevena Predrag Zlatanovic¹, Aleksandra Branimir Hristov¹

¹Eye hospital "Klinika Maja", Niš, Serbia

²Department of Ophthalmology, Faculty of Medicine, University of Niš, Niš, Serbia

Purpose: One of the major causes of CME is disruption of the blood-retinal barrier. Subthreshold micropulse yellow laser (SMYL) has widespread benefits for the treatment of different macular disorders, including CME without foveal damage. We report a series of cases of CME that were completely resolved with the SMYL treatment.

Methods: The results of 18 eyes with central serous chorioretinopathy (CSHR) treated with yellow laser micropulse laser photocoagulation are presented. CSHR was diagnosed in all eyes at the first examination, confirmed by fluorescein angiography (FA) and OCT maculae. Laser intervention was performed according to the results of FA. The results were measured according to visual acuity (Snellen tables), the central thickness of the macula was monitored by OCT maculae and at the last control a FA was performed. Results from the first visit, 15 and 30 days after the intervention were compared. The results are presented using the Microsoft Excel program.

Results: The results obtained indicate a complete cure of CME caused by CSHR by SMPL performed according to FA. According to the last FA report, there was a complete regression of CME, which is confirmed by the central thickness of the macula reduced by an average of 51% and the visual acuity improved by at least 3 lines and reaches 1.0 in all cases. A greater effect of the intervention was seen at the first control, while complete regression occurred at the second control, 30 days after the intervention.

Conclusion: Based on the presented results, it is concluded that subthreshold micropulse yellow laser intervention is a reliable method of treating CME caused by CSHR. OCT results of the macula and visual acuity indicate a complete regression of the disease within 30 days of the intervention.

Keywords: Central serous chorioretinopathy, subthreshold micropulse laser

[Abstract:0512] Application of Single-Molecule Localization Microscopy in Ophthalmology

Hyun Seung Yang¹, Jungmin Kim²

¹Department of Ophthalmology, Seoul Shinsegae Eye Center, Eui Jung Bu, Gyeonggi-do, South Korea

²Department of Applied Bioengineering, Graduate School of Convergence Science and Technology, Seoul National University, Seoul, South Korea

Immunohistochemistry has been a conventional method used to image tissues in ophthalmology research. However, it has its limitations in terms of resolution. With the introduction of super-resolution microscopy techniques, including single-molecule localization microscopy (SMLM), higher resolution images can now be obtained. SMLM, which uses the technology that won Eric Betzig and others the 2014 Nobel Prize, has the highest resolution among super-resolution techniques.

In this study, we developed a high-power laser illumination system for SMLM (figure 1.) and used it to image müller and RPE cells. Our results showed that the high-resolution images obtained through SMLM technology allowed us to observe the qualitative and quantitative changes in cellular structures such as microfilaments, intermediate filaments, microtubules (30nm, figure 2), mitochondria (figure 3), and various types of collagen (I, II, III, IV and IV) after exposure to different cytokines such as TGF- α , VEGF A, VEGF B, and PlGF.

Our findings suggest that SMLM has enormous potential in ophthalmology research. The high-resolution images of cellular structures provide better insights into the mechanisms of various eye diseases, aiding in the development of new treatments. Additionally, the precise colocalization of different biomarkers (GS, GFAP, CLALBP and Alpha-SMA) using SMLM can help in studying the trans-differentiation of müller cells in epiretinal membrane. The study highlights the importance of SMLM technology in ophthalmology research and the potential for improving our understanding and treatment of eye diseases. By observing the changes in cellular structures and their response to different cytokines, we can identify potential targets for drug development. This technology can aid in the development of personalized medicine and improve the outcomes of patients with eye diseases.


Keywords: Single-molecule localization microscopy, Müller cell

Figure 1



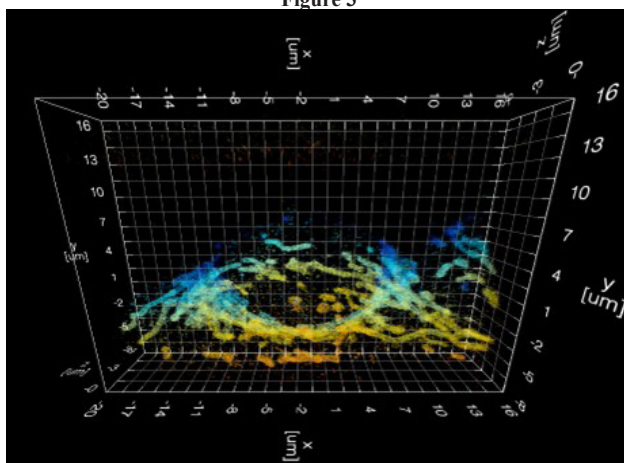
High power laser for illumination for SMLM (405, 488, 561 and 642 nm with 40-1300mw)

Figure



(30nm size)

Figure 3



Super-resolution 3D image of Mitochondria

[Abstract:0513]**A Novel Technique of Subretinal Fluid Drainage in Eyes With Rhegmatogenous Retinal Detachment**Ziya Kapran¹, Tugrul Altan², Nur Acar¹¹Neoretina²Neoretina; Yeni Yuzyl University

Purpose: To evaluate safety and efficacy of draining subretinal fluid (SRF) through direct retinal penetration with 33G polytip subretinal cannula in eyes with rhegmatogenous retinal detachment.

Design: Retrospective consecutive interventional clinical study. **Methods:** 10 eyes of 10 consecutive patients with primary rhegmatogenous retinal detachment who underwent 25-gauge pars plana vitrectomy with subretinal fluid drainage with 33G subretinal cannula (MedOne) were included in the study. Visual acuity and spectral-domain optical coherence tomography were performed preoperatively and at postoperative visits. Visual acuity, anatomical success, peroperative and postoperative complications were evaluated.

Results: Mean age was 64.4±9.6 years (50-81). Single-operation reattachment rate was 90%. Mean (±SD) logMAR visual acuity at the last follow-up was significantly better ($p<0.001$) than preoperatively (2 ± 1.1 vs 0.3 ± 0.5). There was no intraoperative complication due to application of this technique. ERM developed in 1 eye and RPE atrophy at the drainage site was observed in another eye.

Conclusion: Drainage of SRF with 33G subretinal cannula is associated with good anatomical and functional results and low risk of complications. This drainage technique should be evaluated in the long-term in a larger group for anatomical and functional outcomes.

Keywords: Retinal detachment, subretinal fluid drainage, subretinal cannula

[Abstract:0514]**Results of Peripheral Vitrectomy Under Air in Rhegmatogenous Retinal Detachment**Tugrul Altan¹, Ziya Kapran², Nur Acar²¹Neoretina; Yeni Yuzyl University²Neoretina

Purpose: To evaluate the safety and efficacy of peripheral vitrectomy under air in rhegmatogenous retinal detachment (RRD).

Patients and Methods: Patients who underwent 23-gauge or 25-gauge pars plana vitrectomy for RRD were included. After removal of core vitreous and drainage of subretinal fluid, peripheral vitreous was removed under air infusion without scleral indentation. Silicone oil or C3F8 gas was used as tamponade.

Results: Forty-five eyes of 67 patients were evaluated

retrospectively. Mean LogMAR visual acuity was 1.74 ± 1.53 preoperatively. It improved to $0.28 \text{ LogMAR} \pm 0.32$ ($P<0.001$; paired t-test). Initial and final reattachment rates were 91% and 98%, respectively. Scleral indentation was not necessary in any case. Iatrogenic retinal breaks occurred in 7 (10.4%) cases. Macular hole developed in one case after reoperation. Surgery had to be completed with PFCL injection and indentation in 3 cases (4.4%) due to intense fogging under IOL.

Conclusion: Peripheral vitrectomy under air is safe and effective in cases with RRD. Air eliminates the need for scleral indentation, stabilizes the retina, and allows sufficient clarity for vitrectomy.

Keywords: Retinal detachment, vitrectomy under air

[Abstract:0517]**Chandelier-Assisted Scleral Buckling with Illuminated Endolaser Retinopexy**

Nur Acar Gocgöl

Neoretina Eye Clinic, Istanbul, Turkey

Purpose: To report the the results of surgical management of rhegmatogenous retinal detachment (RRD) with chandelier-assisted scleral buckle (CASB) using curved illuminated endolaser retinopexy in a case series.

Methods: CASB was performed under noncontact wide-angle microscopic viewing system with 23-gauge chandelier illumination. Retinopexy was performed with a curved illuminated endolaser probe in 5 phakic eyes with RRD with caution to move the probe very slowly. In all eyes circumferential buckle is placed, combined with radial sponges in 2 eyes. Sclerotomy site was cleared of any vitreous and sutured in all eyes.

Results: Direct visualization enabled the identification of small peripheral fresh tears that could not be seen preoperatively in 2 eyes. In all eyes CASB was effective in finding the tears, localisation of the buckling element and checking the retinal attachment. The curved illuminated endolaser probe was safe to use in phakic eyes, and effective retinopexy was achieved. No additional retinopexy was required postoperatively. Complete retinal attachment was observed on postoperative day 1. No complications were observed during follow-up of 12 months. Best corrected visual acuity increased in all cases, and remained stable.

Conclusion: Retinopexy with curved illuminated endolaser photocoagulation was effective and safe in chandelier illumination-assisted scleral buckle surgery for the management of RRD in phakic eyes. This method may be considered as an option when other modalities of retinopexy is not available at hand. Further studies with longer follow-up is needed.

Keywords: rhegmatogenous retinal detachment, chandelier-assisted scleral buckle, illuminated endolaser

[Abstract:0521]**High Dose Aflibercept Treatment in Naïve Neovascular Age-Related Macular Degeneration: A Real Life Data**Seren Mert Pehlivanoglu¹, Nur Acar Göçgil²¹Seren Mert Pehlivanoglu, MD, Beyoğlu Eye Research and Training Hospital, Istanbul, Turkey;²Nur Acar Göçgil, Prof, FEBO, Neoretina Eye Clinic, Istanbul, Turkey

Purpose: To evaluate the efficacy and safety of intravitreal injections of high dose aflibercept (IVT-AFL) in treatment-naïve patients with neovascular age-related macular degeneration (nAMD) in treat and extend (T&E) dosing regimens.

Methods: This study was longitudinal. Participants diagnosed with nAMD were taken with a detailed history, including demographic data and systemic and ocular history. Written informed consent was obtained from all individuals. A complete ophthalmologic examination, including best-corrected visual acuity (BCVA) measurements, applanation tonometry, a detailed fundus examination after pupil dilation, and optical coherence tomography (OCT) findings were evaluated at the time of initial presentation, on the day of each intravitreal Anti-VEGF administration and at subsequent follow-up visits. All patients received three monthly doses of IVT-AFL 4mg. After loading the dose, a T&E regimen with 4mg IVT-AFL was performed.

Results: Seventeen eyes of 15 patients were included in this study. The mean follow-up time was 18.46±9.28 months. The mean age was 74.9±7.3 (61-86) years, and 9 (60%) of the patients were women. 58.8% of the cases were right eye while 41.2% left eye. The mean baseline BCVA was 59.76±15.1 letter and baseline IOP was 14.1±1.26 mmHg. The mean of number of injection was 8.7±3.3 (4-14). Final BCVA was 72.7±9.1 letter and was found to be increased after IVT-AFL and was statistically significant ($p<0.01$). There was no difference between IOP measures before and after injection ($p=0.06$). In none of the injections anterior chamber parasympathesis was needed. No serious adverse effect or ocular inflammation was detected in study group.

Conclusion: Intravitreal high dose (4 mg) aflibercept treatment with standard three monthly loading doses followed by T&E regimen significantly improved BCVA in patients with neovascular AMD. Additionally, the 4 mg dosing was well tolerated and reduced the need for a repeat injection. Further studies with large numbers and longer follow-up are warranted.

Keywords: neovascular AMD, high dose aflibercept injection, treat and extend

[Abstract:0522]**Scleral Bridge IOL: A novel technique for IOL fixation in aphakia without capsular support**

Hany Hamza

Kasr Elainy School of Medicine Cairo University Egypt

This novel technique presents a cutting-edge approach to implanting a three-piece IOL, utilizing the sclera as a bridge to support the haptics. By externalizing the haptic through one sclerotomy and reintroducing it through another, with the sclera acting as a supportive bridge for the lens, this technique offers a host of benefits. It boasts simplicity and ease of learning, as well as the unique ability to adjust lens position post-implantation, setting it apart from other techniques. Furthermore, this technique could serve as an alternative solution for correcting aphakia, complementing the Yamani technique and Carlavale lens, which may not be universally available.

Keywords: Scleral Fixation IOL

[Abstract:0524]**Vitrectomy for sub ILM hemorrhage: Different causes and visual results**

Hany Hamza

Kasr Elainy School of Medicine Cairo University Egypt

Sub ILM hemorrhage is a rare clinical entity that can result from a variety of causes. These include valsalva retinopathy, blood dyscrasias, laser induced as well as idiopathic and secondary to retinal macroaneurysms. The presentation will show videos of vitrectomy for four cases of sub ILM hemorrhage including one case valsalva induced, 2 cases laser induced and one case due to rupture of macro aneurysm. The indications for intervention will be highlighted and the surgical tips for safe surgery will be elaborated

Keywords: SubILM, hemorrhage, Vitrectomy

[Abstract:0526]**Biopsy for choroidal and retinal tumors: why and how !**

Hany Hamza

Kasr Elainy School of Medicine Cairo University Egypt

With improvement of vitreoretinal surgical techniques and increasing importance of genetic analysis of ocular tumors, biopsy for choroidal and retinal masses is becoming a common practice in ocular oncology centers. Different surgical techniques are used depending on location of the tumor including transvitreal, transscleral routes as well as vitreous biopsy for ocular lymphoma. All techniques will be shown in video cases with special emphasis on the steps and precautions to minimize complications and how to handle the specimen till transport to lab.

Keywords: Biopsy, Choroid, Tumor

[Abstract:0527]**Modified MACULR BUCKLE, the ultimate solution**

Muhammad Samir Alhadad, Ahmad A Magdy Bedd,
Ahmed Abd Alhadi
Alexandria University, Harvard associate.

Purpose: To report the anatomic and visual results of a new sutureless illuminated macular buckle designed for patients with macular hole retinal detachment related to high myopia (MMHRD). Design: Prospective nonrandomized comparative interventional trial.

Methods: Twenty myopic eyes of 20 patients (mean age, 51.4 years; range, 35–65 years) presenting with MMHRD with a posterior staphyloma, in whom the new buckle was used, were evaluated. The buckle used was assembled from a 5 mm wide sponge and a 7 mm wide silicone tire; it was fixed utilizing the sterile topical adhesive Histoacryl Blue (B Braun, TS1050044FP) which polymerizes in seconds upon being exposed to water-containing substances. The primary outcomes measured included aided visual acuity (BCVA) and optical coherence tomography (OCT) findings. The mean follow-up period was 6 months.

Results: Postoperatively, the MH closure was identified by OCT in 8 (40%) eyes. The mean BCVA increased from 0.11 to 0.21 ($p < 0.005$). The axial length of the eyes included decreased from 30.5 mm preoperatively to 29.8 mm ($p = 0.002$) postoperatively.

Conclusion: Preparation of the new sutureless macular buckle is simple and easy. Illumination of the terminal part of the buckle ensures proper placement. Histoacryl Blue is effective in fixing the buckle in its place for at least 6 months with no reported intra- or postoperative complications.

Keywords: Ando plomp, modified ando, MMHRD

[Abstract:0528]**ROP stage 5 different strategies**

Muhammad Samir Alhadad
Alexandria University, Harvard University Associate

The argument is that the anatomic and visual outcomes are often so poor in stage 5 ROP, such interventions are not "worth it." Admittedly, stage 5 ROP is daunting. The surgical learning curve is long and steep. It is zero-error tolerance surgery, as a single iatrogenic retinal break may mean failure. Complete retinal attachment and restoration of near-normal posterior pole anatomy are uncommon. Neurologic comorbidity may limit vision even when surgery is successful. However, poor visual outcome is not invariable, and good visual outcomes are not unheard of. In fact, children having even limited vision can use their vision remarkably well.

Traction along the retinal surface and contraction of the posterior hyaloid face contribute to distortion of the poste-rior

pole architecture. The configuration of the retinal detachment in ROP depends primarily on the location of the ridge and the orientation of vectors of vitreoretinal traction.

In this case series different approaches are illustrated to reach the successful outcome, by using bimanual forceps and scissor with or without biom system by anterior or posterior approaches or by forceps and serrated instrument.

Successful approaches are illustrated by retcam and optos camera.

The surgical goal for stage 5 ROP is to reattach as much of the retina as possible. Form vision can be preserved following vitrectomy for stage 5 ROP.

Maximal recovery of vision following the insult of macula-off retinal detachment and interruption of visual development in infants may take years.

Conclusion: different approaches for stage 5 ROP can lead to successful results as soon as the intervention is early as possible.

Keywords: ROP, Surgical approaches to stage 5 ROP

[Abstract:0529]**Silicone Oil in the Surgical Management of Endophthalmitis**

Murat Öncel
Istanbul İstinye Univ., Ulus Liv Hospital

Purpose: A randomized prospective study was designed to determine the role of silicone oil in the surgical management of endophthalmitis.

Methods: The study subjects were 76 patients in whom clinical signs of endophthalmitis developed within 6 weeks of cataract surgery (phacoemulsification) or secondary lens implantation. All patients had advanced, severe endophthalmitis. They were randomly assigned to treatment with pars plana vitrectomy with or without silicone oil. Preoperative visual acuity in all patients was light perception. The mean follow-up time was 1 year. Forty-two patients received silicone oil (1000cSt) and 34 had only balanced salt solution (BSS). Both groups received infusion fluid containing antibiotics and corticosteroids during the vitrectomy; postoperatively, topical antibiotics, cycloplegics, corticosteroids and systemic antibiotics and corticosteroids were administered.

Results: Data from the trial show that the media cleared much more quickly in the silicone oil group; all eyes in the silicone oil group had clear media, while only 70% in the BSS group had completely clear media. During the follow-up period, there was no retinal detachment in the silicone oil group, but the incidence in the BSS group was 20%. During the entire course of the study, none of the silicone oil group required additional surgery; 40% of the BSS group had additional surgery. The visual acuity was better in the silicone group than the BSS group ($p < 0.01$).

Conclusion: The results of this study indicate that silicone oil can be considered in the surgical management of advanced and severe cases of endophthalmitis. The more rapid clearing of the media with silicone oil could be of clinical importance for certain patients.

Keywords: endophthalmitis vitrectomy silicone oil

[Abstract:0533]

Prognostic factors for visual outcomes following intraocular foreign body removal

Anum Haneef, Hussain Khaqan
lahore general hospital, lahore

Purpose: To determine the influence of prognostic factors on the visual outcome in patients who underwent vitrectomy for intraocular foreign body.

Methods: A retrospective study was conducted at the Ophthalmology Department of Lahore General Hospital between 2017 and 2021. Study included 62 patients between age of 25-55 years who presented with open-globe injuries and retained IOFBs. After informed consent, detailed pre-operative examination was carried out. All patients underwent 23-G ppv with removal of IOFB. In 43 patients, IOFB was removed during first 24 hours after accident. While in 19 patients, who presented, who presented after primary repair, IOFB was removed later than 24 hours after incident. Forcep removal was done in 43 (69.35%) eyes, endomagnet was used in 12 (19.36%) of eyes while 7 (11.29%) foreign bodies were removed with vitrectomy probe. Followup period was 5 years for 29 cases, 3 years for 21 patients while 12 patients had a followup of 1 year. On each followup visit BCVA was noted.

Results: This study included 60 patients. All the patients were males (100%). Mean age was 40 years. Metallic foreign bodies accounted for 49 (79.03%) cases and non-metallic foreign bodies were present in 13 (20.97%) eyes. Entry wound was in cornea in 24 (38.71%) cases, corneoscleral in 29 (46.77%) and sclera in 9 (14.52%) eyes. Size of IOFB ranged from 0.5mm to 22mm in its largest diameter, mean of 5.65mm. Posterior segment was the most frequent location found in 35 (56.45%). Traumatic cataract was found in 35 (56.45%). Retinal detachment was found in 27 (43.54%) cases while 19 (30.64%) eyes presented with vitreous hemorrhage. Final BCVA was improved more than two letters on Snellen's chart in 38 (61.29%), remained same in 21 (33.87%) while decreased in 3 (4.84%) cases. Despite systemic antibiotics, 3 (4.84%) eyes ended up in endophthalmitis. None of the eyes were enucleated.

Conclusion: Prognosis of an IOFB injury is for the most part uncertain due to a complex combination of parameters. Main prognostic factors related to better visual outcome were initial BCVA, time of surgery (first week), initially attached retina, and scleral entry site. Prognostic factors for poor final visual acuity is location, size of IOFB and endophthalmitis.

Keywords: IOFB cornea BCVA

[Abstract:0534]

Visual and anatomical outcomes of pars plana vitrectomy for dropped nucleus

Anum Haneef, Hussain Khaqan
lahore general hospital, lahore

Objective: To evaluate visual and anatomical outcomes of pars plana vitrectomy (ppv) in patients with dropped nucleus following complicated phacoemulsification (pe).

Methods: A retrospective study was conducted at the Ophthalmology Department of Lahore General Hospital between 2017-2022. Study included 51 patients (33 males and 18 females) between age 35-85 years who were referred after complicated phacoemulsification with dropped nucleus. After informed consent, patient's demographic characteristics, interval between complicated pe and ppv, pre and post-ppv visual acuity, pre and post-ppv intra-ocular inflammatory status, pre and post-ppv IOP, the final intraocular lens (IOL) status and complications were recorded. Complications of retained lens fragments was confirmed by ophthalmoscopy or echography in all patients. All the patients underwent 23-G ppv, removal of dropped nucleus with IOL implantation. The range of followup was 2 months to 5 years.

Results: This study included 51 patients in which 33 were males (64.71%) and 18 were females (35.29%). The mean age was 52.5 years. Mean interval between pe and ppv was 7 days. Nuclear fragments were found in 34 (66.67%) eyes, cortical matter in 3 (5.88%) eyes while entire nucleus was dropped in 14 (27.45%) patients. Five (35.71%) patients of 14 patients had retinal detachment at time of presentation. All patients underwent 23-G ppv. Posterior chamber phacofragmentation was carried out in 32 (62.75%) eyes while in remaining 19 (37.25%) patients vitrectomy cutter was used for dropped nucleus. Out of 51, (11.76%) patients received an anterior chamber IOL at time of cataract surgery, 21 (41.18%) eyes IOL in ciliary sulcus, 7 (13.73%) had posterior chamber IOL, and remaining 17 (33.33%) patients were aphakic. Of these 17 aphakic patients, anterior chamber IOL was placed at time of ppv in 7 (41.18%) patients who were judged to have inadequate capsular support. In remaining 10 (58.82%) eyes, where capsular support was deemed adequate, posterior chamber IOL was inserted. Final visual acuity was 20/40 or better in 34 (66.67%) and 20/50 in 6 (11.76%) patients. Main cause of decreased visual acuity was cystoid macular edema and bullous keratopathy.

Conclusion: Poor visual acuity after dropped nucleus can be avoided by managing with prompt skillful ppv manipulation.

Keywords: phacoemulsification, pars plana vitrectomy, intraocular lens

[Abstract:0535]**Development of Cataract following Lens-Sparing Vitrectomy in Pediatric Eyes**

Merve Oral¹, Şengül Özdek¹, Hüseyin Baran Özdemir¹, Ece Özdemir Zeydanlı²

¹Department of Ophthalmology, Gazi University School of Medicine, Ankara, Turkey

²Ankara Retina Clinic, Ankara, Turkey

Purpose: We aimed to present the development of cataract and associated factors following lens-sparing vitrectomy (LSV) in the pediatric age group.

Methods: The research was a retrospective review of pediatric patients who underwent LSV from January 2011 to June 2022. The data was collected according to diagnosis, age at the time of surgery, presence of preoperative retina-lens apposition, presence of preoperative lens opacity, use of a tamponade, direct lens trauma during surgery, final anatomical success, as well as non-operative procedures like laser photocoagulation, cryotherapy, intravitreal anti-VEGF injections, and presence of any additional vitreoretinal surgery performed after LSV surgery.

Results: 294 eyes of 240 pediatric patients were included. Underlying diseases were ROP in 127 eyes, FEVR in 44, Coats in 16, posterior PFV in 19, trauma in 23, CXLR in 17 and miscellaneous (choroidal coloboma, terson syndrome, posterior uveitis, combined hamartoma of retina and retina pigment epithelium) in 48. The mean follow-up was 39 months (min 1, max 127, \pm 33.2). Lens opacity developed in 67 of 294 eyes (22.7%). The mean time between primary surgery and the development of lens opacity was 27.2 ± 36.3 months (1-123 months), of which 32 eyes (10.8%) underwent lensectomy. In the remaining 35 eyes, surgery was not recommended. 7 other eyes (2.4%) underwent lensectomy because of retinal problems. The mean time between primary surgery and lensectomy was 19.2 months (\pm 17.6, min:1, max:65 months). Direct lens trauma during surgery was observed in 6 (2%) eyes, and lensectomy was performed in 5 (83.3%) of these eyes. Retina-lens apposition (p : 0.00) and number of surgeries (p : 0.009) were found to be significantly associated with the lens opacity development.

Conclusion: Development of lens opacity following LSV in pediatric ages usually takes much longer time than adults and develops in a lower rate. Lens opacity rate is higher in eyes with prior lens-retina apposition and with multiple vitreoretinal surgical procedures.

Keywords: lens sparing vitrectomy, cataract, pediatric eyes

[Abstract:0539]**Prediction of functional and anatomical progression in lamellar macular holes**

Emanuele Crincoli¹, Barbara Parolini², Alfonso Savastano³, Fiammetta Catania⁴, Maria Cristina Savastano³,

Veronika Metello², Davide Allegrini⁵, Clara Rizzo⁶,

Raphael Kilian⁷, Mario R Romano⁴, Stanislao Rizzo³

¹Department of Ophthalmology University Vita-Salute IRCCS San Raffaele Scientific Institute, Via Olgettina, 60 20132 Milan, Italy

²Eyecare Clinic, Brescia, Italy.

³Ophthalmology Unit, "Fondazione Policlinico Universitario A. Gemelli IRCCS", Rome, Italy

⁴Humanitas University, Department of Biomedical Sciences, Via Rita Levi Montalcini 4, 20090 Pieve Emanuele – Milan, Italy

⁵Department of Ophthalmology, Humanitas Gavazzeni - Castelli, Bergamo, Italy. Via Giuseppe Mazzini 11, 24128 Bergamo BG, Italia

⁶Ophthalmology, Department of Surgical, Medical and Molecular Pathology and Critical Care Medicine, University of Pisa, Pisa, Italy

⁷Ophthalmology Unit, University of Verona, Verona, Italy

Purpose: To evaluate imaging risk factors for anatomical progression and visual acuity deterioration over time of treatment-naïve degenerative lamellar macular holes (LMHs) with both traditional statistical methods and artificial intelligence (AI) enhanced features

Methods: Multicentric retrospective recruitment of patients diagnosed with LMH with follow up >2 years, no previous pars plana vitrectomy, availability of optical coherence tomography (OCT) B-scan and/or OCT angiography (OCTA) acquisitions at baseline and follow up and age >18 years was performed. Patients were divided in two groups according to the presence or absence of a visual acuity (VA) deterioration >1 line in ETDRS chart during the follow up (respectively VA-STABLE and VA-LOSS groups). Study population was further divided in 2 groups, according to the presence (AN-PROG group) or absence (AN-STABLE group) of anatomical progression during the follow up. Baseline OCT B-scan and OCTA variables of interest were evaluated with both binomial logistic regression and a support vector machine (SVM) model. A deep learning (DL) model for each task was also created.

Results: On 110 eyes of 105 patients (mean follow up 2.9 ± 0.6 years), independent risk factors for anatomical progression and VA deterioration were parafoveal superficial and intermediate capillary plexus (SCP and ICP) vessel density (VD) and vessel length density (VLD), ellipsoid zone (EZ) interruption and choriocapillaris (CC) intercapillary distance (ICD). VA deterioration was also correlated to tissue loss (TL). The SVM and the DL model (550 OCT B-scan images and 320 OCTA images) reached 90.5% and 92.1% testing accuracy for VA deterioration and 91.2% and 93.0% testing accuracy for anatomical progression respectively. Visualization methods enhanced regions of future TL in baseline OCT B-scan images and parafoveal areas in colocalizing with TL in OCTA enface acquisitions.

Conclusion: Parafoveal VD in SCP and ICP and CC ICD are correlated to LMH progression. AI can help visualize regions that will develop TL over time and enhance low flow areas in parafoveal OCTA. AI can accurately predict anatomical and

functional stability of LMHs within 2 years follow-up.

Keywords: Lamellar macular hole, oct angiography, artificial intelligence

[Abstract:0546] Digital Ophthalmology

Linda Anne Lam

USC Keck School of Medicine/USC Roski Eye Institute

Will discuss current applications of Artificial Intelligence in Ophthalmology, with emphasis on retinal applications particularly in Macular Degeneration and Diabetic Retinopathy.

Keywords: AI, AMD, Diabetes

[Abstract:0547] Central Serous ChorioRetinopathy treated with subthreshold 3 ns laser: A retrospective case series

Wilson James Heriot¹, Oubada El Alli¹, Meri Vukicevic², Konstandina Koklanis², Joyce Tang²

¹Retinology Institute, Glen Iris, Victoria Australia

²Discipline of Orthoptics, School of Allied Health Human Services and Sport, La Trobe University, Victoria Australia

Purpose: To test the hypothesis that selective RPE treatment by focal subthreshold 3ns laser can achieve resolution of symptomatic CSCR in a consecutive case series.

Setting: All patients were managed by one retinal specialist (WJH) at Retinology Institute. Written consent was obtained and the audit approved by the HREC of La Trobe University, Victoria, Australia.

Methods: All patients fulfilled the major diagnostic criteria of CSCR. After detailed informed consent, 2-4 threshold determining spots of the 3 ns laser (2RT® AlphaRet) were applied near a major arcade and then the leaking focus directly treated at subthreshold power. Patients were reviewed at 6 and 12 weeks. Data Analysis was with IBM SPSS Version 27 software.

Results: Of the 86 eyes, 72 (84%) had elimination of subretinal fluid (SRF) after a mean of 42.36 days. 15 were retreated; 11 with focal alone, 4 with supplemental grid. Complete resolution at 3m occurred in 93% of eyes. No complications occurred.

Conclusion: These findings support the original hypothesis that limited RPE specific treatment alone can resolve active CSC in the majority of cases, while avoiding treating otherwise well-functioning RPE. An interventional randomised study with the Centre for Eye Research Australia (CERA), has commenced.

Keywords: CSCR, nanosecond, Laser

[Abstract:0548] N-glycosylation patterns across the age-related macular degeneration spectrum

Ivona Bucan¹, Kajo Bucan¹, Kajo Bucan², Ozren Polasek³, Ozren Polasek⁴, Ozren Polasek⁵

¹Eye Clinic, University Hospital Centre Split, 21000 Split, Croatia

²Department of Ophthalmology, University of Split School of Medicine, 21000 Split, Croatia

³Department of Public Health, University of Split School of Medicine, 21000 Split, Croatia

⁴Algebra LAB, Algebra University College, Ilica 242, 10000 Zagreb, Croatia

⁵Croatian Science Foundation, Ilica 24, 10000 Zagreb, Croatia

The pathogenesis of age-related macular degeneration (AMD) remains elusive, despite numerous research studies. Therefore, we aimed to investigate the changes of plasma and IgG-specific N-glycosylation across the disease severity spectrum. We examined 2835 subjects from the 10.001 Dalmatians project, originating from the isolated Croatian islands of Vis and Korcula. All subjects were classified into four groups, namely (i) bilateral AMD, (ii) unilateral AMD, (iii) early-onset drusen, and (iv) controls. We analysed plasma and IgG N-glycans measured by HPLC and their association with retinal fundus photographs. There were 106 (3.7%) detected cases of AMD; 66 of them were bilateral. In addition, 45 (0.9%) subjects were recorded as having early-onset retinal drusen. We detected several interesting differences across the analysed groups, suggesting that N-glycans can be used as a biomarker for AMD. Multivariate analysis suggested a significant decrease in the immunomodulatory bi-antennary glycan structures in unilateral AMD (adjusted odds ratio 0.43 (95% confidence interval 0.22–0.79)). We also detected a substantial increase in the pro-inflammatory tetra-antennary plasma glycans in bilateral AMD (7.90 (2.94–20.95)). Notably, some of these associations were not identified in the aggregated analysis, where all three disease groups were collapsed into a single category, suggesting the need for better-refined phenotypes and the use of disease severity stages in the analysis of more complex diseases. Age-related macular degeneration progression is characterised by the complex interplay of various mechanisms, some of which can be detected by measuring plasma and IgG N-glycans. As opposed to a simple case-control study, more advanced and refined study designs are needed to understand the pathogenesis of complex diseases.

Keywords: age-related macular degeneration, N-glycans, biomarker

[Abstract:0549]**Tips in dealing with surgical challenges of myopic macular holes with AXL more than 32 mm**Khahid Sabti*Kuwait specialized eye center, Kuwait*

Dealing with Myopic macular holes in very long eyes of AXL more than 32mm is quite challenging. In most of these cases it is very difficult or even impossible to peel ILM due to relative instruments short shaft to perform membrane peel. We are demonstrating a practical and simple surgical technique to overcome this surgical challenge. This novel surgical technique was used successfully in 8 cases in which all membrane peel was successful with closure of all holes.

Keywords: Myopic macular holes in high myopia

[Abstract:0550]**IOL exchange using Iris-Claw IOLs**Matteo Forlini*Matteo Forlini, Department of Ophthalmology, San Marino State Hospital, Republic of San Marino*

In this presentation I'm showing how to manage complex cases of IOL exchange using Artisan Iris-Claw IOL implantation. Most of cases present IOL subluxation in posterior chamber, or complete IOL luxation in vitreous chamber, as well as IOL opacification: all these different scenarios can require IOL removal with a secondary IOL implantation. In our experience, secondary IOL implantation with Iris-Claw IOL represents a safe and fast procedure, with low risks of complication, and good functional results.

Keywords: Iris-Claw, IOL exchange, Secondary IOL

[Abstract:0551]**A Novel Modified Flapless surgical Technique for sutureless scleral fixation of FIL SSF intraocular lens: a retrospective case series**Daniilo Iannetta¹, Marc D De Smet², Nicola Valsecchi¹, Luigi Fontana¹¹*IRCCS Azienda Ospedaliero- Universitaria di Bologna - Bologna -Italy*²*Helvetia Retina Associates, Micro Invasive Ocular Surgery Center LAUSANNE SWITZERLAND*

Purpose: To report two variations of a novel modified flapless surgical technique in patients who underwent implantation of Soleko FIL-SSF lens.

Methods: Thirteen eyes of thirteen consecutive patients requiring secondary IOL implant were evaluated, with a three-month minimum follow up. The variation to the standard surgical technique was represented by the creation of two 1/3 thickness scleral grooves, instead of the typical partial thickness scleral flaps. The two anchors of the FIL-SSF lens

were positioned in the grooves, avoiding any exposure. The conjunctival was closed with 8-0 vicryl suture or equivalent, making sure that the anchors were well covered.

Results: Mean age of patients was $70 \pm 14,8$ years, with average preoperative visual acuity of $1,2 \pm 0,8$ LogMAR. No intraoperative complications occurred. Anatomical success was achieved in all patients. Three months after surgery, mean visual acuity was $0,87 \pm 0,77$ LogMAR. Transient IOP elevation was reported in 3/13 (23,1%) patients and cystoid macular edema was observed in 1/13 (7,7%) patient during postoperative follow up. No other complications, such as conjunctival erosion, were reported.

Conclusion: Flapless surgical technique for Soleko FIL-SSF IOL implantation has shown to be safe and effective as the standard technique, revealing shorter surgical time.

Keywords: Scleral Fixation Intraocular lens, secondary Implant, Carlevalle Lens

[Abstract:0552]**Results of 140 cases of IOL implantation with Yamane technique combined with pars plana vitrectomy**Gianluca Besozzi¹, Giuseppe Nitti¹, Ermete Giancipoli², Andrea Palma Modoni¹, Milena L'abbate¹, Flavio Cassano¹, Giacomo Boscia³, Maria Carmela Costa¹¹*Vito Fazzi Hospital, Dept of Ophthalmology, Lecce, Italy*²*Dept of Ophthalmology, University of Foggia, Foggia, Italy*³*Dept of Ophthalmology, University of Bari, Bari, Italy*

The aim of the presentation is to present the results of 140 consecutive cases of IOL implantation with Yamane technique combined with pars plana vitrectomy for various conditions, such as complicated cataract surgery, traumatic and / or spontaneous crystalline lens dislocation in vitreous chamber, traumatic and/ or spontaneous crystalline lens dislocation in vitreous chamber. Anatomical and functional results were described, as well as intraoperative and postoperative complications.

Keywords: Yamane IOL implant, complicated cataract surgery, cataract/IOL luxation

[Abstract:0554] Unexpected Complication After Macular Hole Surgery with Temporal Inverted ILM Flap Technique

Aysegul Mavi Yildiz, Remzi Avci
Bursa Retina Eye Hospital

A 55 year-old male presented with blurry vision and metamorphopsia in the left eye for 4 weeks. Biomicroscopic anterior segment examination was bilateral unremarkable. Best corrected visual acuity (BCVA) was 20/20 in the right eye and 20/100 in the left eye, intraocular pressure was 14 mmHg bilaterally. Dilated fundus examination revealed a full thickness macular hole in the left eye, which was confirmed with optical coherence tomography (OCT). The minimum hole diameter was 262 μ m. The patient underwent 27 gauge pars plana vitrectomy (PPV), temporal inverted internal limiting membrane (ILM) technique and air tamponade. Face down head position was recommended for 24 hours. Five days after the surgery the BCVA was 20/30 in the left eye and the patient complained of distorted vision. The OCT scan revealed the presence of a sub-ILM flap perfluorocarbon liquid (PFCL) bubble. We performed a repeat PPV including removal of the PFCL bubble using a 41-gauge extendible subretinal injection cannula and re-inversion of the ILM flap. Three weeks after the second surgery, the BCVA raised to 20/25 and closure of the hole. The recovery of the ellipsoid zone and outer retinal layers were confirmed with OCT.

Keywords: Macular hole, Perfluorocarbon liquid, Temporal Inverted ILM Flap

[Abstract:0555] InTraocular EMulsion of Silicone oil (ITEMS) grading system

Mario Romano
Humanitas University, Milan, Italy

Aim: To propose the InTraocular EMulsion of Silicone oil (ITEMS) grading system for the assessment of silicone oil (SiO) emulsion, applicable in a routine clinical setting and validated through an expert-led consensus procedure.

Methods: Seven experts on intraocular liquid tamponades, led by a facilitator, performed a literature review on the detection of SiO emulsion. Based on the proposed ideas, a questionnaire was developed and submitted to the experts on the methods to detect SiO emulsion and the items to grade. After two rounds of individual ranking using a nine-point scale and related discussion, the final grading system was developed including items that reached consensus (score ≥ 7 from $\geq 75\%$ of members).

Results: The agreed ITEMS grading system includes the identification of SiO microbubbles and large SiO bubbles through slit lamp biomicroscopy, gonioscopy, fundus examination under mydriasis or ultra-widefield fundus

photography. Moreover, macular and disc OCT are used to detect SiO-associated hyperreflective dots.

Conclusion: An evidence-based expert-led consensus was conducted to develop grading system of SiO emulsion, allowing, for the first time, homogenous collection of data on SiO emulsion. This has the potential to improve our understanding of the role and clinical relevance of SiO emulsion allowing comparisons between different studies.

Keywords: silicone oil emulsification, silicone oil score

[Abstract:0556] Toxicity in VR surgery

Mario Romano
Humanitas University, Milan, Italy

Purpose: to evaluate viability of retinal cells after the use of multiple intraoperative devices.

Methods: We collected real-life clinical cases of toxicity associated to the use of intraocular devices in vitreoretinal surgery, characterized by post-operative retinal necrosis, pale optic disc, damage of outer retinal layers at the posterior pole, peripheral inflammatory foci. For all cases, the surgical technique and the devices used were reported and reproduced in the lab on porcine eyes to analyze retinal toxicity. We correlated the clinical findings detected in the eye with the findings detected in the lab, analyzed according to the International Organization for Standardization. We also reported the cumulative toxicity of combined use of medical devices.

Results: Clinical and surgical data of forty-six patients were collected. The surgical technique and medical devices used were reproduced in the lab on porcine eyes. Retina extracted from 25 porcine eyes globes subjected to no surgery and sham surgery showed optimal cell viability (96-100%). Retina extracted after the surgery with residues removal showed good cell viability (86%), while retina from eye bulbs after surgery with high residues and cytotoxic control resulted in high retinal cytotoxicity corresponding to low average cell viability of 40% and 29%, respectively. We also reported that the cell viability, membrane damage and metabolic activity of human ARPE-19 was significantly affected by TA in any formulation (TA no-alcohol, TA with alcohol, TA diluted) compared to lutein, and the interaction of TA with PFCL increase the cytotoxicity.

Conclusion: VR performed with the combined use of multiple medical devices does affect retinal viability if the residues of used medical devices are not properly removed. Moreover, the use of TA is cytotoxic, and even more in presence of direct contact between TA and PFCL. An adequate surgical technique is recommended to avoid dangerous iatrogenic interactions.

Keywords: iatrogenic damage, retinal toxicity

[Abstract:0559]**Gore-Tex scleral fixed intraocular lenses refractive results**

Carla Rocio Perez Montaño, Jorge Guevara Chipolini,
Juan Abel Ramirez Estudillo
Hospital de la Luz Retina Department, Mexico City, Mexico

Purpose: Although visual and safety results of scleral IOL fixation with Gore-Tex suture are favourable, little is known about the refractive results. For scleral fixated IOLs, the following has been assumed: a position inside the lens bag to calculate its power. But there is no evidence that supports this. These surgeries represent a challenge due to a unique anatomical position, determined by the location of the suture in the sclera. For any lens with a power greater than 5 diopters, its position with respect to the eye affects optical correction. For this reason, the exact IOL position must be known, to be able to adjust the power of the lens preoperatively. Using a formula taking into account a focal length change, it could give more accurate refractive results. A 2 mm posterior to the limbus IOL placement, will cause an IOL focal length backward displacement; so using this new focal distance as a factor in the calculation formula, will dampen the refractive result, resembling to the target chosen pre-surgically.

Methods: Prospective, surgical case series at Hospital de la Luz, Retina Department in Mexico City. Fixation of an Akreos A060 lens to the sclera with an 8-0 Gore-Tex suture was done in each patient. Four sclerectomies at 2 mm posterior to the corneoscleral limbus were placed. One side 2 Sclerectomies were separated from each other by 4 mm. The spherical equivalent obtained post-surgically will be compared vs the refractive target chosen for the calculation of the lens in the bag.

Results: 11 eyes were included. The average sphere target was -0.27, and our postoperative sphere was 0.15. However, if we look at the postoperative cylinder, an average of -1.9 was obtained. When assessing keratometric astigmatism, we saw that an average of -2.09 was induced according to the Warren Hill calculation.

Keywords: aphakia, Gore-Tex, scleral fixation IOL

[Abstract: 0560]**The role of Peripheral retinal OCT in vitreoretinal disorders**

Daniela Bacherini

Department of Neurosciences, Psychology, Drug Research and Child Health, Eye Clinic, University of Florence, AOU Careggi, 50121 Florence, Italy.

Studying the peripheral retina with new widefield and ultra-widefield imaging modalities, including OCT is a research field of growing interest, as it allows for a more in-depth analysis of the anatomy and ultrastructure of the peripheral retina.

The aim of this study is to evaluate the use of peripheral ultra-widefield OCT in the characterization of peripheral retinal degenerations, by means of a multimodal platform imaging (Optos Silverstone).

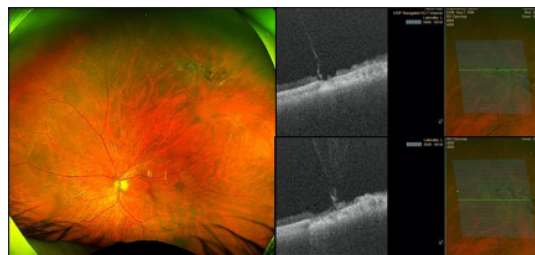
We performed a retrospective cross - sectional observational study of 55 patients (48 eyes) with peripheral retinal degenerations, evaluated at the Careggi University Hospital (Florence) between March 2021 and August 2023. Each patient underwent fundus examination and multimodal imaging, including peripheral scans using Swept Source OCT.

We evaluated different types of peripheral retinal degeneration: lattice degeneration, microcystic degeneration, snail track degeneration, retinal tufts, retinal tears, peripheral retinal holes, peripheral retinoschisis. We evaluated these principle OCT Findings: presence of vitreous traction, detached edges, subretinal and intraretinal fluid, adjacent microcystic changes, and artifacts such as inverted image.

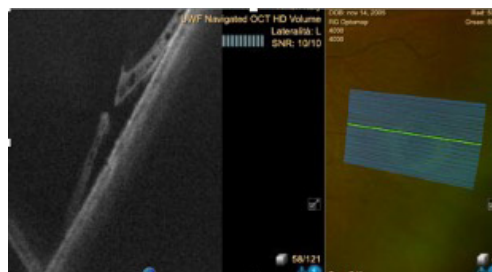
In conclusion, we hypothesize that the characterization of peripheral retinal degenerations using ultra-widefield imaging SS-OCT provides information that can directly influence the clinical management, such as evaluation of prophylactic laser therapy.

Keywords: peripheral OCT, SS-OCT, peripheral retinal degeneration

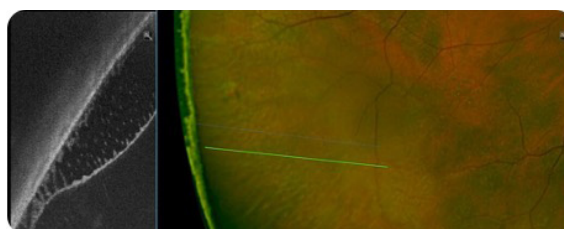
Lattice degeneration



Peripheral retinal hole



Peripheral retinoschisis



[Abstract:0562]**Postoperative refractive outcomes in eyes undergoing combined phacovitrectomy surgery for Epiretinal Membrane**

Wilson Heriot¹, Oubada El Ali¹, Meri Vukicevic²,
Konstandina Koklanis²

¹Retinology Institute, Glen Iris, Victoria Australia,

²Discipline of Orthoptics, School of Allied Health Human Services and Sport, La Trobe University, Victoria Australia

Purpose: To evaluate the post-operative refractive outcomes from three different IOL power prediction protocols for combined phacovitrectomy for epiretinal membranes.

Methods: This single-center retrospective cohort outcome study of combined phacovitrectomy surgery performed by one surgeon. Eyes were divided into three protocols depending on the biometer (Zeiss IOL Master 500 and the Heidelberg Anterior), and the strategy to determine the posterior (RPE) peak. Protocol 1 accepted the proprietary software determination versus manual RPE identification in Protocols 2 and 3. The primary outcomes were the postoperative refractive prediction error (PE) and mean absolute error (MAE).

Results: Seventy-five eyes of 67 patients were included; 24 eyes (32%) were in Protocol 1, 11 eyes (15%) in protocol 2 and 40 (53%) in protocol 3. The average PE of Protocol 1 (PE -0.24D) trended for myopia consistent with current literature. The PE for Protocol 2 and 3 combined was 0.008 D. A Mann-Whitney U test revealed a significant difference in the distribution score for MAE between Protocol 1, and Protocol 2 and 3 combined ($U = 163.0$, $z = -4.676$, $p < .001$).

Conclusion: This study demonstrated that post-operative refractive outcomes were accurate and consistent in protocols 2 and 3 where the biometry scans were interrogated to ensure the RPE peak was used to determine the AL, and not the ERM peak. A refractive outcome of ± 0.25 D was achieved in 90% ($n=9$) of eyes in Protocol 2 and 72% in Protocol 3 ($n=72$) which is comparable to standalone cataract surgery, whereas only 18% of eyes achieved this accuracy in protocol 1.

Keywords: refractive outcomes, epiretinal membranes, phacovitrectomy

[Abstract:0566]**Diabetic tractional retinal detachment in Mexico**

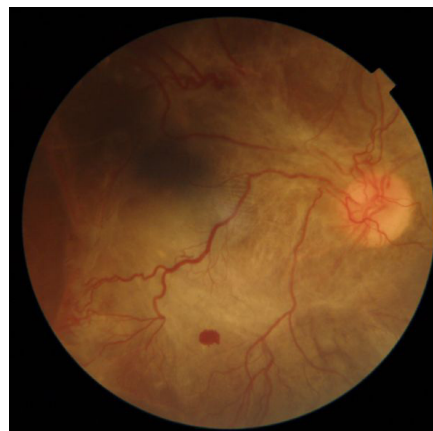Fausto Miguel Lechuga

Central de Especialidades Médicas de La Paz, Mexico.

Diabetic retinopathy is a very common complication in patients with diabetes. It is the leading cause of blindness in people of reproductive age; it occurs in approximately 50% of patients with 10 years of diabetes and 90% of patients with more than 30 years of diabetes. Retinal detachment is a serious and common complication in patients with diabetic retinopathy and must be treated as soon as possible to try to avoid blindness. Vitrectomy is necessary, following an elaborate and detailed technique in order to release traction

removing fibrous tissue and membranes attached to the retina, as well as the use of laser to prevent the appearance of new blood vessels and also used to prevent further bleeding. At the end of vitrectomy surgery, silicone oil or gas is often used in order to keep the retina in the proper position to restore vision.

Keywords: Diabetic Retinopathy, Vitrectomy

Macular Fibrosis

Macular Fibrosis in Diabetic Retinopathy

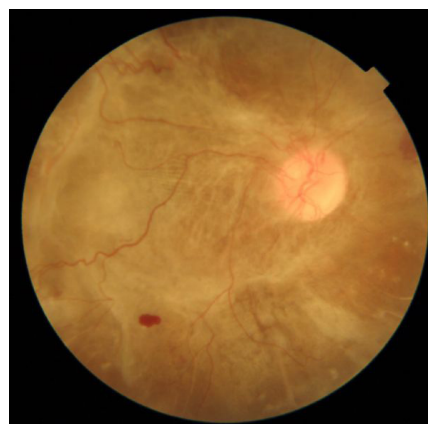
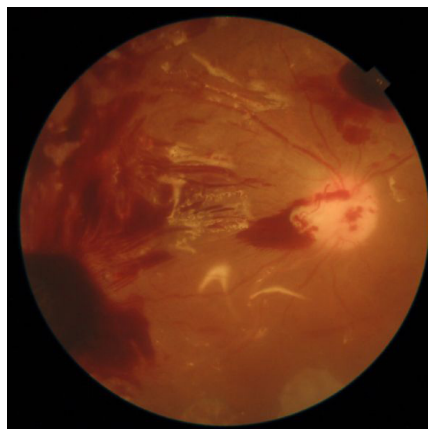
Macular Fibrosis with Anti-VEGF treatment.

Image of diabetic macular fibrosis on the third day of injection of Anti-VEGF treatment.

Postoperative Result of Macular Fibrosis

Result of the first post-operative day after vitrectomy surgery in a case of macular fibrosis.

[Abstract:0570]**The importance of fluorescein angiography in ROP**

Susana Teixeira, Mafalda Mota, Maria Vivas, Catarina Monteiro, Julio Almeida, Graça Pires, Isabel Prie
Retina Department, Hospital Professor Doutor Fernando Fonseca, Lisbon

Purpose: To present the findings of fluorescein angiography (FA) in ROP and the importance of this exam in ROP monitorization.

Introduction: FA is a relatively safe procedure in paediatric population. It enables us characterize the vascular anomalies associated with ROP that are not readily detected in indirect ophthalmoscopy. It can accurately characterize ROP stages, enhance vascular anomalies after anti-VEGF treatment, monitoring vascular interface in peripheral avascular retina and help in the detection of recurrence. Also has a role in the exclusion of the different diseases that are differential diagnosis of ROP.

Methods: A retrospective analyses of FA images obtained between January 2010 and June 2023 in a single institution. The authors present the fluorescein findings in the different ROP stages, vascular anomalies after anti-VEGF therapy, vascular interface in PAR and ROP recurrences.

Results: The authors present the fluorescein findings in: the different ROP stages, the vascular anomalies after anti-VEGF therapy, the characterization of the vascular interface in PAR and in ROP recurrences.

Conclusion: FA provides a body of information that help us in the characterization of ROP and in the monitorization of peripheral vascular changes after anti-VEGF treatment. It is a very promising exam that should be included in future studies in order to find reliable biomarkers for recurrence and progressive ROP.

Keywords: ROP, Fluorescein angiography, peripheral avascular retina

[Abstract:0571]**Surgical management of adult ROP complications**

Çağrı Beşirli
Department of Ophthalmology and Visual Sciences, University of Michigan, Ann Arbor, MI, USA

In addition to potential manifestations in infancy, ROP is a life-long disease that can present with numerous late-onset complications. Some of these complications including peripheral retinoschisis, retinal detachment, and vitreomacular traction require surgical intervention. This presentation will review surgical approaches to adult ROP complications using a case based approach.

Keywords: ROP, surgery

[Abstract:0572]**Laser Prophylaxis in Patients with Stickler Syndrome**

Michael Blair¹, Michael Shapiro¹, Sarah Rodriguez², Saira Khanna²
¹*Retina Consultants LTD, Des Plaines, USA*
²*University of Chicago, Chicago, USA*

Purpose: To evaluate the association among laser prophylaxis treatment, retinal detachment (RD), and visual acuity (VA) in patients with Stickler syndrome (SS).

Design: Retrospective comparative case series.

Participants: Patients with SS.

Methods: Patients received extended vitreous base laser (EVBL), nonprotocol laser (NPL), or no laser prophylaxis treatment of any kind.

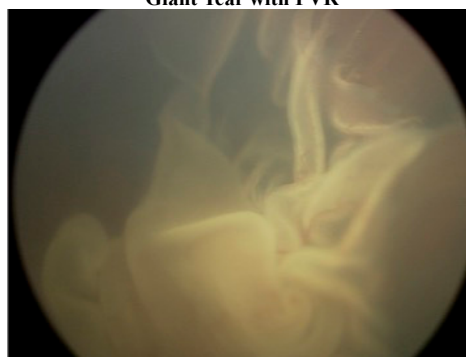Main Outcome Measures: The 2 main outcome measures that were examined in these patients were rates of RD and VA.

Results: In this study, 230 eyes of 115 patients were included. Fifty-nine patients were women (51%). The median age at the time of laser prophylaxis treatment was 9.5 years (interquartile range [IQR], 6e13 years), and the median age of patients with RD was 11 years (IQR, 7e18 years). Of the 230 eyes, 92 did not undergo any laser treatment, 9 received NPL treatment, and 129 received EVBL treatment. Of the 129 eyes that underwent EVBL treatment, 4 (3%) had RD, compared with 74 eyes (73%) that had RD and did not receive laser or NPL treatment ($P < 0.001$). Eyes that received EVBL treatment had approximately 8 lines better vision, on average, compared with those that did not receive laser or NPL treatment (0.86 logarithm of the minimum angle of resolution; 95% confidence interval, 1.1 to 0.64; $P < 0.001$).

Conclusion: Treatment with EVBL seems to reduce the rate of subsequent RD and is associated with better VA in patients with SS.

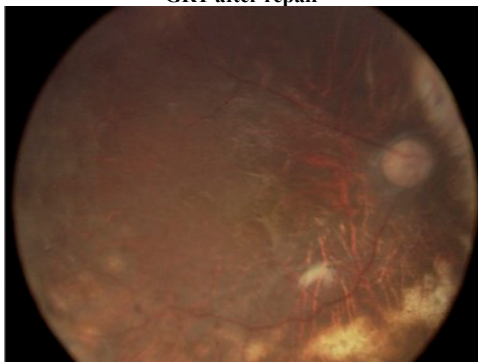
Keywords: Stickler Syndrome, Laser Prophylaxis

Giant Tear with PVR



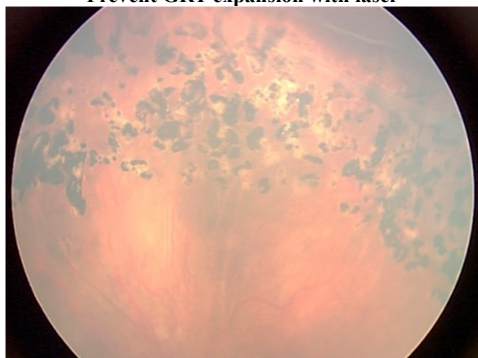
Giant Tear and PVR lead to poor outcome

GRT after repair



Retina may be reattached, but vision may be poor

Prevent GRT expansion with laser



Note Peripheral break is limited by laser

[Abstract:0574]

Is it true that macular buckle induces atrophy? a long-term review and comparison with natural history

Jaime Francisco Rosales Padrón, Barbara Parolini
Eyecare Clinic, Brescia, Italy.

Myopic traction maculopathy (MTM) accounts for one third of the patients with pathologic myopia (PM), a tailored treatment is mandatory to release the tractional forces involved in this progressive disease. Macular Buckle (MB) should be used as a first line treatment, alone or combined with vitrectomy, depending on the stage of MTM. Despite the excellent outcomes, a few cases of atrophy and pigmentary changes related to the buckle have been reported.

To find out any possible MB-related atrophy, we evaluated the progression of PM in patients with MB and compared it with a non-surgery control group with PM, by fundus imaging analysis, with mid-term (1-5y) and long-term (>5y) follow-up.

116 eyes of 66 patients operated by a single surgeon in Eyecare Clinic, Brescia, IT. were included, 70 eyes in the MB-surgery group and 46 eyes in the control group. Baseline characteristics were similar in both groups, 91% and 97% had any stage of PM at baseline, the most common was diffuse atrophy. In the MB group, we found progression in 41.4% of eyes (n=29) with a follow-up of 58.17 +/- 35 months, of which 27.6% progressed to a more advanced stage and 72.4% remained

on the same stage, 2 eyes developed a CNV (2.8%). 39.5% and 43.8% progressed in the mid and long-term follow-up, respectively. No MB-related atrophy was found. Progression in the control group was found in 50% of eyes (n=23) with 53.6 +/- 30 months follow-up, 8.7% developed a new CNV. 46.4% and 55.5% showed progression in mid and long-term subgroups, respectively.

Based on META-PM Group classification, the progression of PM was similar in both groups, even mildly grater in the control group. We did not find any MB-related pigmentary changes or atrophy. The findings in pattern, incidence, and rate of progression were comparable to previous long-term studies.

Keywords: Macular Buckle, MTM, atrophy

[Abstract:0576]

Autologous retinal transplant: Mexican consortium. Experience of 66 cases

Sergio Rojas Juarez¹, Silvia Medina Medina¹,
Raúl Vélez Montoya², Abel Ramirez Estudillo¹,
Sergio Hernández Da Mota³, Virgilio Morales Cantón²
¹Hospital Fundación Nuestra Señora de la Luz
²Asociación Para Evitar la Ceguera en México APEC
³Clínica David

Purpose: To determine visual and anatomical outcomes of autologous retinal transplant for macular hole treatment.

Methods: Multicentric retrospective cases series. Clinical records were reviewed and demographic data (age and sex), pre and postoperative ophthalmologic assessment (best correct visual acuity, slit lamp examination, intraocular pressure and funduscopy) and ocular coherence tomography features (minimal and base diameters) were registered; after surgery macular hole closure type were also recorded; only cases with complete clinical records and at least 6 months follow-up were included.

Results: 66 eyes of 64 patients were included, mean age was 66 ± 9.6 years, and female sex was more frequent. Initial best corrected visual acuity was 1,1 ± 0,52 logMAR, a mean minimal diameter of 826,4 ± 450,7µm and mean base diameter of 1318 ± 542µm were registered, most cases were idiopathic (63%). In all cases pars plana vitrectomy, ILM peeling and autologous retinal transplant were performed, in 71% of eyes the procedure was associated with phacoemulsification. Retained perfluorocarbon was the main postop complication (6%), 1,5% of eyes developed PVR; 3% ocular hypertension and 3% presented secondary retinal detachment. Anatomical closure was achieved in 78,7% and type 1C closure was more frequent, mean postoperative BCVA was 0,8 ± 0,3 logMAR (p: 0,000). Mean follow-up was 16,6 ± 10,3 months.

Conclusions: Autologous retinal transplant is an effective technique for large and complex macular holes, with good anatomical closure rates and uncommon postoperative complications.

Keywords: Autologous retinal transplant, macular hole, macular surgery

[Abstract: 0577]**Lyophilized amniotic membrane for rhegmatogenous retinal detachment**

Sergio Rojas Juarez, Silvia Medina Medina
Hospital Fundación Nuestra Señora de la Luz

Purpose: To determine the safety and efficacy of lyophilized amniotic membrane patch as replacement of conventional endotamponades for rhegmatogenous retinal detachment repair surgery

Methods: Prospective case series. Patients older than 18 years-old with primary rhegmatogenous retinal detachment and superior tears within one meridian extension or less and visual acuity of hands movement or better were included. Demographic features, complete ophthalmological assessment including intraocular pressure, best corrected visual acuity and lens status were registered before and after surgery. 25G pars plana vitrectomy was performed in every case; associated with phacoemulsification and intraocular lens implant if needed, according to surgeon criteria. Standard vitrectomy was performed and after air-solution exchange a lyophilized amniotic membrane patch was placed over the causal lesion. Patients were followed-up for at least 3 months after surgery. Patients with inferior causal breaks or grade C inferior proliferative vitreoretinopathy or another visual impairing pathology (glaucoma, uveitis, diabetic retinopathy, etc) were excluded.

Results: 13 eyes of thirteen patients were included, female sex was predominant, 92% had retinal detachment with macular involvement, visual loss was manifested 36.5 ± 63.2 days before surgery. Initial visual acuity ranged from 2.5 to 0.3 logMAR. All cases underwent vitrectomy and 62% of them had phacoemulsification due to the presence of lens opacities. Most common complication during surgery was amniotic membrane loss or insufficient size, and there were no postoperative complications related with a amniotic membrane patch, only one eye has retinal redetachment due to preexistent PVR. Retinal reattachment was achieved in 100% of cases and all patients remained stable, with no significant changes in intraocular pressure, lens transparency, or posterior capsule.

Conclusions: Amniotic membrane constitutes an alternative to long-term tamponades since it allows the sealing of causal lesions, and shows several advantages over conventional tamponades such as potential reduction of proliferative vitreoretinopathy.

Keywords: Retinal detachment, Vitrectomy, Lyophilized amniotic membrane

[Abstract:0579]**Peripheral and central retinal vascular changes in asymptomatic family members of patients with familial exudative vitreoretinopathy**

Atike Burçin Tefon Arıbaş¹, Şengül Özdek², Hatice Tuba Atalay²

¹Department of Ophthalmology, Ankara State Hospital, Ankara, Turkey

²Department of Ophthalmology, Gazi University, Ankara, Turkey

Purpose: To evaluate the peripheral vascular changes and effects of these on macular microvasculature in asymptomatic family members of familial exudative vitreoretinopathy (FEVR) patients.

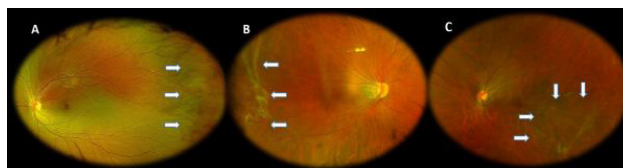
Methods: A retrospective study including 61 eyes of asymptomatic family members of FEVR patients. Retinal abnormalities were assessed via ultra-widefield fluorescein angiography (UWF-FA) and optical coherence tomography angiography (OCTA). Eyes were grouped into 3: The first group comprised of eyes with normal findings on UWF-FA; the second group comprised of eyes with abnormal findings on UWF-FA but without any retinal ischemia and the third group involved eyes with retinal ischemia or neovascularization.

Results: Best corrected visual acuity (BCVA) was 20/20 in all eyes. 40 eyes (65.6%) had abnormalities on UWF-FA. The most common feature was peripheral vascular looping, increased tortuosity, and anastomosis (63.9%). ODM/ODD ratio was higher in group 3 compared to group 1 and 2. Deep foveal VD was lower in group 1 compared to group 2 and 3. The mean FAZ area and perimeter were smaller in group 2 and 3 compared to group 1.

Conclusion: Even asymptomatic family members of FEVR patients may have significant peripheral retinal vascular abnormalities which may be associated with smaller optic disc, macular ectopia and macular microvascular changes.

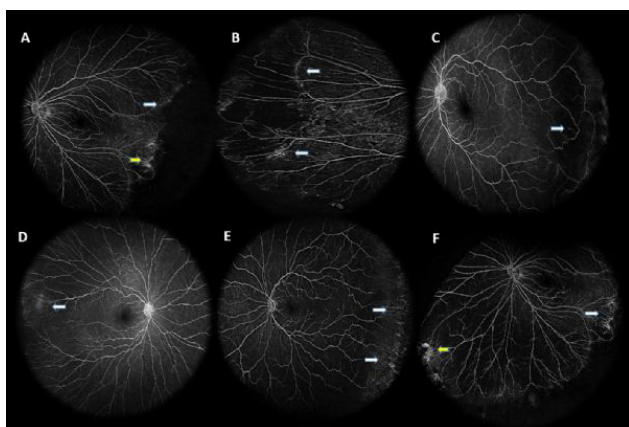
Keywords: familial exudative vitreoretinopathy, optical coherence tomography angiography, ultra-wide field fluorescein angiography

Figure 1



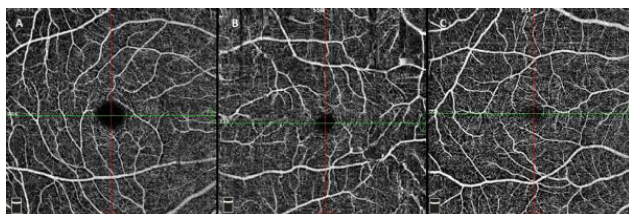
Retinal abnormalities on UWF-CFP: A. peripheral avascular retina, B, C. vascular loops & anastomosis, straightening of the temporal retinal vascular arcades, temporally ectopic macula, sudden termination of vessels, neovascularization (NV) with whitish epiretinal membrane-like vitreoretinal interface pathologies in the vascular-avascular junction (arrows)

Figure 2



UWF-FA images in asymptomatic family members of FEVR patients. There was no pathology seen ophthalmoscopically or in UWF-CFP. Note the peripheral avascular area in all FA's to some extent, capillary drop out (B), vascular loops (C), hyperfluorescent dots on periphery (A, B, E, F) and late phase fluorescein angiographic peripheral or posterior leakage (LAPPEL) sign (D).

Figure 3



FAZ area images of asymptomatic family members of FEVR patients (superficial retinal layers). A. Image of an eye from group 1, B. group 2, C. group 3. Note that FAZ area is the largest in the eye from group 1 and the narrowest in the eye from group 3

[Abstract: 0582]

The importance of structural OCT in the assessment of patients with central serous chorioretinopathy

Enrico Borrelli¹, Costanza Barresi¹, Marco Battista¹, Alessandro Berni¹, Federico Ricardi¹, Maria Lucia Cascavilla¹, Michele Reibaldi², Francesco Bandello¹

¹Vita-Salute San Raffaele University Milan, Italy & Vita-Salute San Raffaele University Milan, Italy &

²Department of Ophthalmology, University of Turin, Italy

Purpose: To assess relationships between demographics, clinical characteristics and optical coherence tomography (OCT) characteristics with persistence of metamorphopsia after resolution of subretinal fluid in eyes with chronic central serous chorioretinopathy (CSC).

Methods: One-hundred participants with “resolved” (absence of subretinal fluid) chronic CSC were retrospectively analyzed. Patients underwent a complete ophthalmological evaluation including assessment of presence of metamorphopsia. At

the study visit, OCT scans were reviewed for qualitative and quantitative features.

Results: Sixty-six out of 100 (66.0%) patients complained of metamorphopsia. Both the foveal and parafoveal ganglion cell complex (GCC) thicknesses were thinner in CSC eyes with metamorphopsia ($35.1 \pm 10.6 \mu\text{m}$ and $82.0 \pm 18.1 \mu\text{m}$ vs. $40.7 \pm 11.8 \mu\text{m}$ and $93.1 \pm 13.5 \mu\text{m}$, $p=0.030$ and $p<0.0001$). In the foveal region, the outer plexiform layer and outer nuclear layer (ONL) thicknesses were thinner in patients with metamorphopsia ($24.6 \pm 8.5 \mu\text{m}$ and $63.1 \pm 20.9 \mu\text{m}$ vs. 29.1 ± 8.7 and $76.2 \pm 18.2 \mu\text{m}$, $p=0.016$ and $p=0.005$). The ellipsoid zone band was more frequently discontinued in eyes with metamorphopsia (56.1 % vs. 35.3%, $p=0.039$). Multivariate stepwise linear regression analysis demonstrated that the strongest associations with presence of metamorphopsia were with parafoveal GCC thickness ($p=0.004$), foveal ONL thickness ($p=0.010$), and number of previous recurrences of subretinal fluid accumulation ($p=0.017$). The time interval from the last subretinal fluid resolution was not associated with the presence of metamorphopsia.

Keywords: Central serous chorioretinopathy, Macula, Metamorphopsia

[Abstract: 0583]

MTM-Stop device: Outcomes of the first 15 years of study on macula buckling

Barbara Parolini

Eyecare Clinic

Purpose: Myopic traction maculopathy (MTM) has been thoroughly studied and divided in 12 stages in the MTM staging system. It has been observed that, while stages with full thickness macular holes (FTMH) such as stages “c” need to be treated with vitrectomy and ILM flap, stages with severe schisis and macular detachment benefits more from a macular buckle.

The aim of the study is to report long term results on 265 eyes operated with macular buckle and followed up for 15 years.

Methods: Two hundred and 65 eyes affected by MTM were operated with macular buckle with or without combined vitrectomy. The follow up was ranged between 1 and 15 years. The following parameters were studied: improvement of anatomical result and vision, improvement in microperimetry, change in axial length and refraction, complications.

Results: The anatomical partial or complete was 98%. Improvement of vision of at least 3 lines was observed in 85% of eyes. In 25% vision had a limited improvement or remained stable due to preoperative atrophy. Macular buckle did not induce further sign of atrophy progression when compared with the contralateral eye in a period of 15 years.

Conclusion: Macular buckle offers an efficient, safe and long lasting resolution of MTM. Macular buckle should be chosen as first line of treatment for macular schisis and detachment secondary to MTM.

Keywords: Myopic traction maculopathy, MTM, FTMH

[Abstract: 0584] Wnt Retinopathies

Antonio Capone Jr.

*Affiliations: Professor of Ophthalmology, Oakland University William Beaumont Hospital School of Medicine, Auburn Hills, MI
Chief Clinical Officer, EyeCare Partners, Ballwin MO
Partner, Associated Retinal Consultants, Royal Oak, MI*

The Wnt signaling pathway plays a pivotal role in vascular morphogenesis in the eye, ear and central nervous system. Wnt ligands and receptors are key regulators of ocular angiogenesis during development. Mutations in Wnt signaling components cause rare genetic eye diseases in humans such as Norrie disease, osteoporosis-pseudoglioma syndrome (OPPG) and familial exudative vitreoretinopathy (FEVR) with defective ocular vasculature. This lecture will provide insights into the pathogenesis of Wnt retinopathies, their management, and avenues of pharmacotherapeutic research.

Keywords: Wnt signaling, Norrie disease, osteoporosis-pseudoglioma syndrome (OPPG), familial exudative vitreoretinopathy (FEVR)

[Abstract: 0585] Phenomenology of spontaneous closure in degenerative and mixed type lamellar macular hole

Fiammetta Catania^{1,2}, Mario R Romano^{2,3}, Emanuele Crincoli⁴, Davide Allegrini³, Alexandra Miere⁴, Ismael Chehaibou¹, Youssef Abdel Massih¹, William Beaumont¹, Thibaut Chapron¹, Eric H Souied⁴, Georges Caputo¹

¹Department of Ophthalmology, Hopital Fondation Adolphe De Rothschild, 29 Rue Manin, 75019 Paris, France

²Humanitas University, Department of Biomedical Sciences, Via Rita Levi Montalcini 4, 20090 Pieve Emanuele – Milan, Italy

³Department of Ophthalmology, Humanitas Gavazzeni - Castelli, Bergamo, Italy. Via Giuseppe Mazzini 11, 24128 Bergamo BG, Italia

⁴Department of Ophthalmology, Centre Hospitalier Intercommunal de Créteil 40, avenue de Verdun, 94100 Créteil, France

Purpose: To describe OCT imaging characteristics of a cohort of patients showing spontaneously closing degenerative or mixed type lamellar macular holes (LMH) and to compare them to the ones of a sex and age matched group showing stable lesions.

Methods: Patients diagnosed with degenerative and mixed type LMHs showing OCT-documented spontaneous anatomical closure were retrospectively selected from 3 specialized retina centers. An equal number of age and sex

matching subjects were randomly selected among patients with anatomically stable lesions.

Results: Eleven (11) spontaneously closing (SC group) and 11 stable (ST group) degenerative LMH with a mean follow up of 4 years were recruited. Hyperreflective inner border (HIB) and linear hyperreflectivity in the outer plexiform layer (LHOP) at baseline were significantly more prevalent in SC group in processed images (respectively $p=0.007$ and $p=0.003$). A borderline significance in lamellar hole associated epiretinal proliferation (LHEP) at last follow up was detected ($p=0.085$). As for mixed type LMH, 10 patients for SC group and 10 for ST group were recruited. LHOP at baseline in processed images was significantly more prevalent in SC group ($p=0.005$).

Conclusions: Spontaneously closing LMHs show higher prevalence of HIB and LHOP at the beginning of the closing process, a difference which is enhanced by image processing. These signs might be a signal of microglial and Muller cells coordinated activation

Keywords: lamellar macular hole, microglia, muller cells, outer plexiform layer, spontaneous closure, posterior vitreous detachment, retina, wait and watch, follow up, hyperreflective foci

Abstract: 0586] Subthreshold stimulation laser in central serous chorioretinopathy

Ivan Fišer, Filip Brazda, Martina Rubesova

While the central serous chorioretinopathy (CSC) can easily be treated with laser when a focus of leakage can be defined, treatment of CSC without visible focus, i.e. with multiple or diffuse leakage is difficult. Half dose PDT used to be tried for twenty years with limited success but neither Visudyne nor the special lasers are available now. Instead, different types of micropulse lasers are used nowadays.

Having no micropulse laser, since twenty years ago we have been using a standard laser in a modified way. Subthreshold laser power with a small diameter spot and shorter time does not cause laser burns but presumably it rather stimulates the RPE which then either seals the area of leakage or improves the reabsorption of fluid. The results of our small study are showing that this method brings success comparable to the classical focal laser of the well-defined focus. We are using this technique also in diabetic macular edema and in idiopathic perifoveal teleangiectasia.

Take home message: Subthreshold laser treatment can be performed even without special lasers, just using a standard laser machine.

RAPIDFIRE ORAL PRESENTATIONS

[Abstract:0106]

Purpose: To report three cases of unilateral Eales disease with presumed tubercular etiology and management, including a combination of oral steroids plus antituberculosis (anti-TB) therapy. **Methods:** The clinical, serological, tuberculin skin test, a

Omer Othman Abdullah

Ibnsina Modern Eye and Retina Center

Purpose: To report three cases of unilateral Eales disease with presumed tubercular etiology and management, including a combination of oral steroids plus antituberculosis (anti-TB) therapy.

Methods: The clinical, serological, tuberculin skin test, and angiographic evaluations for each patient were carried out.

Result: The first case received only oral steroids for the first four months, but the disease progressed, therefore, shifted to the full anti-TB combined with oral steroids. The latter two cases received the same combination with no progression. The third case had stopped oral steroids abruptly caused reactivation of the disease.

Conclusion: The diagnosis of Eales disease is an exclusion diagnosis. The natural course, clinical picture, and the FFA findings of the illness make the diagnosis possible. Patients at risk to predispose to tuberculosis needs particular concern when presented with vitreous hemorrhage. Steroid monotherapy causes progression of the disease, and sudden steroid withdrawal results in reactivation.

Keywords: Jarisch–Herxheimer reaction, Steroid monotherapy in eales, Unilateral Eales

FFA of the left eye of case 1

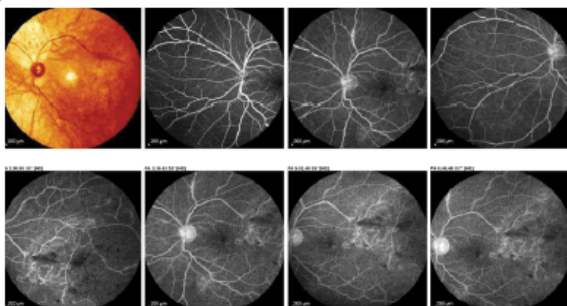


Figure 2a FFA of the left eye of the Case number 1.

fundus image and FFA of the right eye of case 2. Showing leakage and ischemi

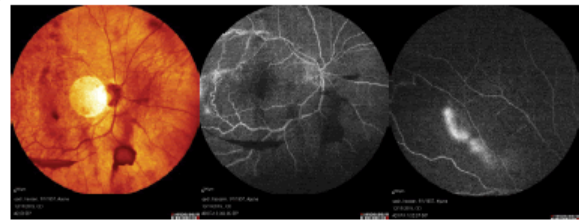


Figure 5 The right eye of the Case 2. Colored fundus image on the left side showing very slight vitreous hemorrhage with subhyaloid hemorrhage in the inferior part. The FFA in the middle and left side; showing, leakage from NVE and collateral vessels in the temporal part of the macula with the ischemic area outlined well.

fundus image and FFA of the right eye of case 3. Showing leakage, ischemia and vitreous hemorrhag

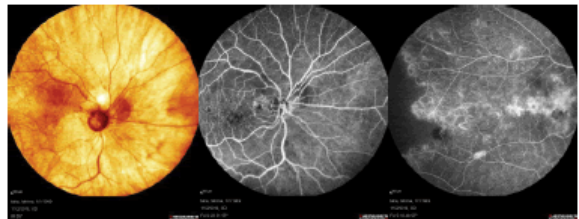


Figure 6 The right eye of the Case 3. Colored fundus image on the left side showing very slight vitreous hemorrhage. The FFA in the middle and left side; showing, leakage from NVE and other blood vessels in the temporal part of the macula with the ischemic area outlined well.

[Abstract:0128]

When the macula acts tough

Pooja Sinha

A B Eye Institute, Patna, India

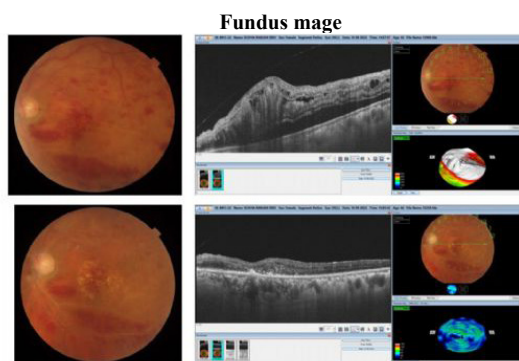
Aggravation of retinal hard exudates and fibrin following intravitreal anti vascular growth factor therapy for the management of macular edema secondary to BRVO/CRVO is an unwanted complication leading to further deterioration of vision. The prognosis in such eyes has been reported to be better than those with diabetic macular edema. This is because of inner retinal vascular leakage and relatively normal blood supply of RPE in vascular occlusion compared to retinal inflammation and breakdown of blood retinal barrier in diabetic eyes.

Long CME duration and high serum low density lipoprotein cholesterol levels are risk factors for hard exudate progression.

In our study of 5 cases of vascular occlusion we experienced hard exudate migration leading to poor visual prognosis following anti vegf injection.

Identification of risk factors in such eyes is therefore very important for better visual outcome of such patients.

Keywords: retinal hard exudates, subfoveal migration



[Abstract:0129]

EVRS Retina Premier League

Sangeet Mittal¹, Maged Gergess², Manisha Agarwal³, Sengul Ozdek⁴, Nishikant Jaywant Borse⁵, Barbara Parolini⁶, Saurabh Luthra⁷, Hussain Khaqan⁸, Neeraj Sanduja⁹, Jayant Shekhar Guha¹⁰, Susana Teixeira¹¹, Eleonara Beatriz Lavaque¹²

¹Thind Eye Hospital, Jalandhar, India

²Al Watany Eye Hospital, Cairo, Egypt

³Dr Shroff's Charity Eye Hospital, New Delhi, India

⁴Gazi University School of Medicine, Ankara, Turkey

⁵Insight Eye Clinic, Mumbai, India

⁶Eye Care Clinic, Brescia, Italy

⁷Drishti Eye Institute, Dehradun, India

⁸Hafeez Eye Center, Lahore, Pakistan

⁹Vaan Eye & Retina Centre, New Delhi, India

¹⁰Sai Retina Foundation, New Delhi, India

¹¹Hospital Fernando Fonseca, Lisbon, Portugal

¹²Universidad de Buenos Aires, Argentina

Retina Premier League will be a video based session. There will be 2 teams of 5 participants each. Each time will have one captain and one star player which will be reported to match referee beforehand. A toss will take place to decide which team comes first for presentation. The winner of toss can choose either to raid or defend. The captain of the team will decide which player to send for presentation. The player will present a 4 minute video of challenging or funny VR surgery case/cases. The opposite team will send one of their members as a defender to present a 4 minute video. The videos will be judged by 7 judges who will give judgement in terms of which video they like. Each judge equals one point. Number of judges in favour of video equals the number of points scored by team. Star players have the chance of winning double points. Any player exceeding their time beyond 4 minutes will be considered a foul and team will lose the points. Team that scores higher after 5 rounds will be winner.

Keywords: Vitrectomy, Challenges

[Abstract:0146] Ecological retina

Francesca March De Ribot, Alper Bilgic
University hospital

Session Description: Ophthalmology and retina are significant contributors to waste and contamination. Reducing waste, reusing instruments and medication and increasing our use of telemedicine can all contribute to reducing the carbon footprint of our specialty. We have an outstanding quantity of patients, surgery and clinics, including intravitreal injections and disposable instruments. The healthcare sector is a major contributor to gas emissions, equivalent to 4.4% of the global through energy consumption, medication, disposables and patient travel. We have the highest clinical and surgical volumes in medicine. We can make a difference.

Public health impact of Climate Change, Combatting Carbon Footprinting

Assessing waste and generating a change: Dropping the drapes

Attitudes Toward Operating Room Waste: eyedrops, consumables, endolaser, cryo, gas, forceps and more

Reducing waste in the clinic and intravitreal injections

Best sustainable practices

Keywords: Sustainability, climate change, ecology

[Abstract:0147]

Method for vitreous body microsurgical anatomy studying

Natalia Kisilitsyna¹, Sergey Novikov²

¹Eye Microsurgery Complex Institute of Professional Education

²Eye Microsurgery Complex SEP Ltd

Purpose: The vitreous body (VB), due to the complexity of its structure, remains one of the least studied anatomical structures to this day. The most relevant works are the studies of J. Worst et al. in 1973, in which the authors proposed new methods of CT preparation with the introduction of dyes. The purpose of the study is to develop the algorithm of examination of the vitreous body microsurgical anatomy that would let to assess its topographic specifics

Methods: The proposed method of macromicroscopic examination was used to study the VB topographic anatomy of 38 cadaver eyeballs. In order to color transparent structures of the vitreous, poorly soluble barium sulfate (Vitreococontrast) was used. Macroscopic examination was performed using a operating microscope with a magnification, microscopic changes were evaluated by light microscopy at multiple magnification with microscope followed by photographic recording. The algorithm for macroscopic examination performing.

The result of macroscopic preparation was the compilation of individual anatomical and topographic maps of VB patients. A distinctive feature of the developed method is the ability to dissect any VB structure and to isolate each cortical layer with the possibility of studying its anatomical and topographic features and relationships with underlying tissues (internal limiting membrane, ciliary body, lens capsule). In addition, the method allows to maintain the shape and integrity of the specimens after passing through all stages of histological processing. In order to fixate VB samples, we used a method with fixing VB structures on a special adhesive-metric tablet, and placing them in a biopsy bag placed in a biopsy cassette. Light microscopy used. Conclusion. The developed technique of macromicroscopic examination of the vitreous allows to create an individual map of the VB topographic anatomy.

Keywords: vitreocontrast, vitreolenticular interface, vitreoretinal interface

[Abstract:0161]

Evaluation of retinal microvascular differences after successful macular hole surgery with superior inverted flap technique or temporal inverted flap technique

Utku Limon, Işıl Özsoy Saygın, Tuğba Ayoğan Gezginaslan, Erdinç Bozkurt, Betül Ilkay Sezgin Akçay
University of Health Sciences Umraniye Training and Research Hospital
Eye Clinic Istanbul/Turkey

Purpose: To evaluate the differences in microvascular changes between the patients after successful idiopathic macular hole surgery with the superior inverted flap technique or temporal inverted flap technique

Methods: In this retrospective study, patients with idiopathic macular holes with a horizontal diameter between 200-400 µm at the narrowest point were included in the study. Group 1 included 14 patient's 14 eyes who have treated with the superior inverted flap technique. Group 2 included 15 patient's 15 eyes who have treated with the temporal inverted flap technique. The vessel density (VD) ratios in superficial capillary plexus (SCP), and deep capillary plexus (DCP) at the center area and at the four parafoveal quadrants were compared between the groups at baseline and postoperative month 6 with optical coherence tomography angiography (OCTA, OCT Triton, Topcon, Japan).

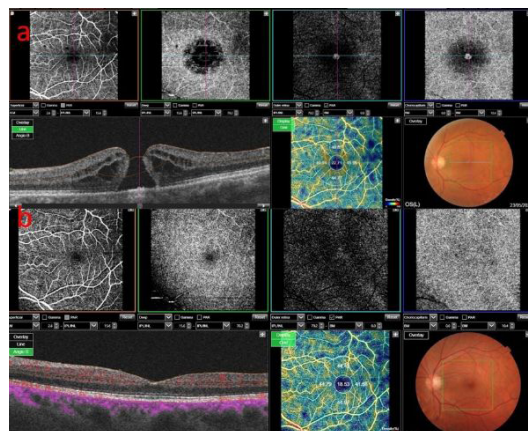
Results: The mean baseline BCVA improved significantly in two groups at postoperative month 6 (respectively 1,21 to 0,50 and 1,32 to 0,52 logMAR, $p < 0.05$, $p < 0.05$). There was no significant difference in mean BCVA between the two groups at postoperative month 6 ($p < 0.05$). The mean VD in SCP in the center area increased significantly in both groups at month 6 postoperatively ($p = 0.011$ and $p = 0.020$), but the mean VD in DCP in the center area did not significantly change in both groups compared with its preoperative state ($p = 0.079$ and $p = 0.078$). The mean VD ratios in SCP and DCP at the four parafoveal quadrants did not change significantly in both

groups at month 6 from baseline values ($p < 0.05$ at all).

Conclusions: In both techniques, there was no change in SCP and DCP at the four parafoveal quadrants while there was a significant increase in SCP in the central area at month 6 after the surgery.

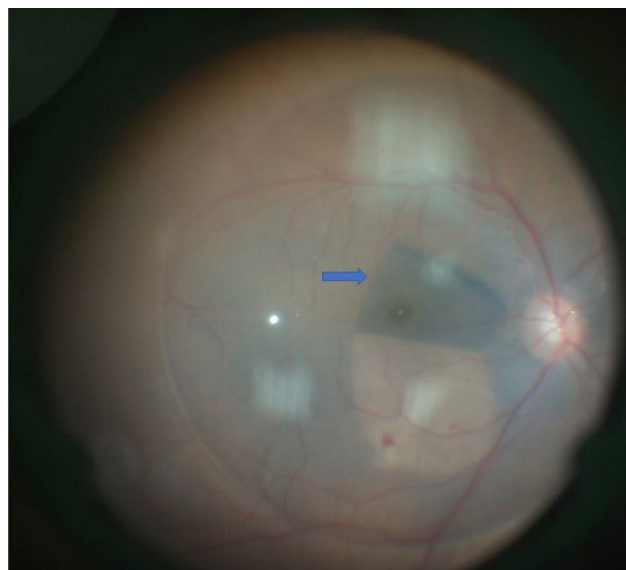
Keywords: Superior inverted flap technique, temporal inverted flap technique, optical coherence tomography angiography

Figure 1



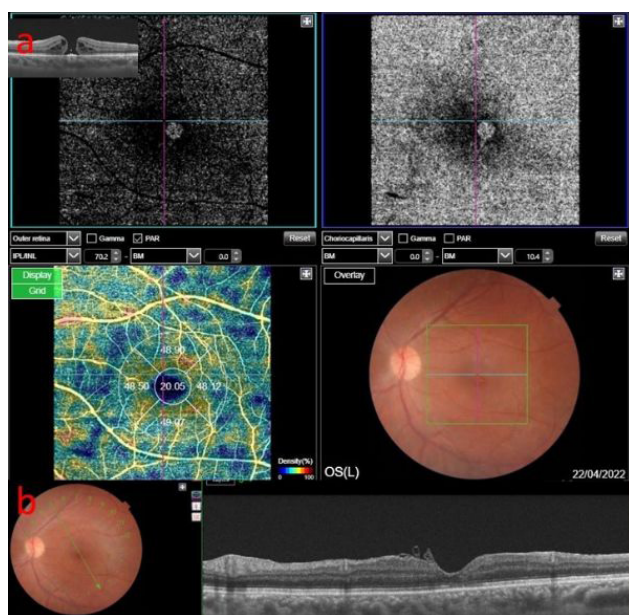
Preoperative (a) and postoperative month 6 (b) optical coherence tomography angiography images of the patient who underwent macular hole surgery with the superior inverted flap technique

Figure 2



Intraoperative image of a patient treated with superior inverted flap

Figure 3



Postoperative month 6 images of a patient treated with temporal inverted fleb

[Abstract:0173] Vitrectomy for Silicone Band Intrusion In Vitreous Cavity

Hussain Khaqan
PGMI,AC,LGH,Lahore

Purpose: To remove the intruded silicone band and manage the complications

Material-Methods: Total 4 cases, male, mean age 17 years were included in this study, presented with silicone band intrusion after encircling buckle. Three eyes has associated retinal detachment. All eyes underwent 23 gauge PPV, cutting the band inside vitreous cavity, complete vitrectomy and endotamponade of silicone oil..

Results: All four eyes retina attached, in three eyes silicone oil was removed after 04 months. Silicone band internal part has no complications, mean follow up is 18 months.

Conclusion: Cutting the silicone band inside the vitreous cavity with horizontal cutting scissor is novel & safe technique in experts hands to manage the associated complications and prevent the further complications.

Keywords: Intrusion, Silicone band, Vitrectomy

[Abstract:0175] Cystic Retinal Detachment

Fathi Omar Zenbil¹

¹Vitreoretinal unit in Tripoli Eye Hospital / Tripoli University, Tripoli -Libya

²Vitreoretinal unit in Almsarra Clinic / Tripoli -Libya

Surgical video for 2 cases of Complicated PVR-RRD with Large retinal cysts

Keywords: Cystic RRD, PVR

[Abstract:0186] Sympathetic Ophthalmia: Three Years

Perfecto Elpidio Octavio Roy Cagampang III
Manila Doctors Hospital

A case of 21 year old male with ocular trauma to the left, hit by a steel pitcher. Repair of the left ocular injury was delayed by more than a month resulting to a sympathizing right eye. Sympathetic ophthalmia, although a rare eye condition secondary to trauma, can have several pathogenesis. Treatment has to be tailor made to the response of the eye, in this case, steroids and cyclosporine. Timing of laboratory tests, ocular and systemic led to a final vision of 20/20 in the left eye from 20/400 during three years of treatment.

Keywords: Sympathetic Ophthalmia

[Abstract:0209] Breaking the Retinal Barrier: Journey into Sub-Retina & Supra-choroid

Jayanto Shekhar Guha¹, Sangeet Mittal², Barbara Parolini³, Hany Hamza⁴, Nishikant Jaywant Borse⁵, Gokhan Gurelik⁶, Athanasios Nikolakopoulos⁷, Agnieszka Nowosielska⁸

¹SRF Eye Hospital, New Delhi, India

²Thind Eye Hospital, Jalandhar, India

³Eyecar Clinic, Brescia, Italy

⁴Hany Hamza Clinic, Giza, Egypt

⁵Insight Eye Clinic, Mumbai, India

⁶Gazi University, Ankara, Turkey

⁷Papanikolaou Hospital, Thessaloniki, Greece

⁸Warsaw Eye Hospital, Warszawa, Poland

With improvements in Vitreo-Retina techniques, indications of Vitreo-retinal surgery are expanding to include procedures involving choroid. There exists many sub-retinal conditions where patients can benefit from timely and appropriate surgical management. It becomes important for Vitreo-Retina surgeons to anticipate, diagnose and take appropriate remedial measures to manage these complex situations.

Unfortunately most VR surgeons are wary of doing sub-retinal and choroidal surgeries because of lack of training and exposure.

This advanced level instruction course aims at VR surgeons in training or in practice.

It will be conducted by eminent experts and give insights into complex sub-retinal conditions, their causes, prevention and management.

After attending the course, vitreo-retina surgeons shall be able to recognize these complex situations, plan and perform these procedures to maximize their results.

The course also aims to spread awareness among ophthalmologists about the possibility, limitations and results in managing these complex situations

Keywords: Sub-retinal space, Choroid, Vitreo-retinal surgery

[Abstract:0215]

Comparison of postoperative retinal displacement in diabetic and idiopathic epiretinal membranes

Muhammed Numan Işın, Semra Koca, Ender Sırakaya
Department of Ophthalmology, Kayseri City Hospital, Kayseri, Turkey.

Purpose: To compare the postoperative retinal displacement in idiopathic epiretinal membrane (iERM) and diabetic epiretinal membrane (dERM).

Methods: This retrospective study included 36 iERM and 22 dERM cases. In cross-sectional OCT images (B-scan) the presence of foveal pit, subfoveal fluid, cotton ball sign (CBS), foveoschisis and disorganization of retinal inner layer (DRIL) were recorded. Central macular thickness (CMT), ectopic inner foveal layer (EIFL) were calculated. Retinal displacement was quantified using infrared image of OCT consisting of the fovea-disc margin, interarcade and perimacular distance.

Results: There was no difference between the groups in terms of age and gender. The mean postoperative follow-up duration was 11.5 and 11.3 months in the iERM and dERM groups, respectively. While the presence of subfoveal fluid and DRIL was significantly higher in the dERM group, presence of foveal pit, CBS and foveoschisis were similar in both groups pre-operatively. In the postoperative period, only DRIL was significantly higher in the dERM group. While CMT decreased significantly in both groups, there were no difference between the groups in both pre and post-op periods. Preoperatively, EIFL thickness was thicker in the iERM group compared to dERM group. EIFL thickness reduction with vitrectomy was significant only in the iERM group. In the iERM group, while the fovea-disc margin distance decreased, the interarcade and perimacular distance increased significantly. In the dERM group, the disc-fovea distance change was not significant. Significant visual improvement was achieved with vitrectomy in both groups. Although preoperative visual acuity (VA) was not different between groups, post-operative VA remained significantly lower in the dERM group. In the dERM group, the presence of DRIL was associated with pre and post-op VA.

Discussion: Significant retinal displacement occurs after vitrectomy in both iERM and dERM. The low VA in the dERM group may be related to the presence of DRIL.

Keywords: Diabetic, Epiretinal membrane, Retinal displacement

[Abstract:0222]

Comparison of 27-gauge unimanual and 25-gauge bimanual vitrectomy outcomes of tractional retinal detachment in diabetic patients

Yusuf Cem Yılmaz, Serife Ciloglu Hayat, Seyfi Aydın, Ece Ozal, Serhat Ermis, Sadik Altan Ozal
University of Health Sciences, Basaksehir Cam and Sakura City Hospital, Department of Ophthalmology, Istanbul, Turkey

Purpose: To assess the surgical outcomes of 27 and 25-gauge vitrectomy in proliferative diabetic retinopathy (PDR) with tractional retinal detachment (TRD).

Methods: This retrospective study includes 41 eyes with TRD (23 eyes for 27g and 18 eyes for 25g) who undergone pars plana vitrectomy (PPV) between June 2021 and January 2023. Preoperative ocular factors (baseline visual acuity [VA], vitreous haemorrhage [VH], severity of trd, retinal photocoagulation), general factors (sex, age, diabetes duration, HbA1c level), surgical procedures (preoperative anti-vascular endothelial growth factor injection, internal limiting membrane peeling, combined cataract surgery) were evaluated. Silicone oil was given to all patients. Intra and post surgical complications were noted. The post-surgical results were regularly followed up at 6 months.

Results: The mean age of patients who undergone 27-gauge and 25-gauge surgery was 58,04±12,3 and 57,05±8,5 years. The mean duration of diabetes was 12,42±4,1 years and mean HbA1c level was 9,28±2,33 for all participants. All eyes underwent intraoperative laser photocoagulation. The mean length of follow-up was 268±61 days after the surgery. The mean operation time was 85,7±13,3 minutes in the 27-gauge group and 63,6±16,3 minutes in the 25-gauge group (p<0.05). Mean BCVA for 27 and 25-gauge surgery improved from logarithm minimum angle of resolution (logMAR) 1,94±0,53 to 1,37±0,66 and 2,15±0,22 to 1,14±0,65 respectively (p<0.05). Second surgery was not needed for retinal reattachment. There were 4 cases of intra-operative iatrogenic tears and 3 of them belonged to the 27g vitrectomy group. In these 3 cases, conversion from unimanual surgery to bimanual surgery was needed. There were no cases of endophthalmitis in our cohort.

Conclusions: The 27 and 25g PPV was found effective in diabetic TRDs. More intraoperative complications were seen in 27g group compare to 25g. After the surgery positive functional and anatomic success was achieved in both groups.

Keywords: Proliferative diabetic retinopathy, tractional retinal detachment, unimanual and bimanual ppv

[Abstract:0231]**The visual outcomes of idiopathic epiretinal membrane surgery in eyes with ectopic inner foveal layers**

Doğukan Cömerter, Eyüp Düzgün, Murat Sönmez
Department of Ophthalmology, Istanbul Sultan Abdulhamid Han
Training and Research Hospital, Istanbul, Turkey

Purpose: To describe the functional and anatomical outcomes of pars plana vitrectomy (PPV) with epiretinal membrane (ERM) and internal limiting membrane (ILM) peeling in eyes with and without ectopic inner foveal layers (EIFL) based on SD-OCT staging system.

Methods: In this retrospective study, 63 eyes of 63 patients who underwent 25 G pars plana vitrectomy (PPV) for idiopathic ERM with a minimum follow-up of 12 months were included. Preoperative and postoperative ophthalmic examinations and OCT scans were recorded in all patients. The association of the EIFL and other SD-OCT parameters with preoperative and postoperative best corrected visual acuity (BCVA) was analyzed.

Results: Preoperatively, the EIFL were present in 33 eyes (52%). When all patients were considered together, visual acuity improvement was statistically significant ($p < 0.0001$). However; as an EIFL stage, only progression in Stage 2 ERMs was significant ($p < 0.001$). Preoperative EIFL thickness was positively correlated with the central macular thickness (CMT), but not with BCVA. ($r = 0.552$; $p = 0.0001$). While there was a statistically significant positive correlation between visual acuity and outer nuclear layer (ONL) thickness before surgery, no correlation was found postoperatively. No relationship was found between pre- and postoperative CMT and macular volume with BCVA. ($p > 0.05$) There was no statistically significant difference in visual acuity according to the presence of cotton ball sign, cystoid macular edema, vitreomacular traction, and ellipsoid zone disruption. ($p > 0.05$) EIFL developed in 5 cases after surgery in stages 1 and 2.

Conclusion: The presence of EIFL is an independent predictor of worse postoperative BCVA. In terms of surgical timing, early stages may be preferred for providing good anatomical and visual recovery.

Keywords: epiretinal membrane, ectopic inner foveal layers, optical coherence tomography

[Abstract:0234]**The Clinic Outcome of Open Ophthalmic Injuries in Western of Turkey**

Erdinc Aydın¹, Erdem Eris², Hazan Gul Akduman³,
Levent Kazanci³

¹Department of Ophthalmology, Izmir Katip Celebi University, Izmir, Turkey

²Eye Clinic, Behcet Uz Training and Research Hospital, Izmir, Turkey

³Eye Clinic, Atatürk Training and Research Hospital, Izmir, Turkey

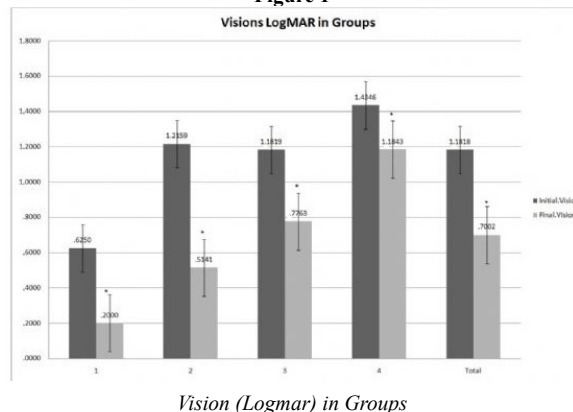
Purpose: To evaluate open globe traumas in a tertiary hospital, Turkey.

Methods: From 2015 January to October 2019 patients that were referred to us from the Emergency Unit at our hospital for an emergency ophthalmologic surgery were evaluated retrospectively. The patients were divided into four groups based on their age: 0–14 years as group 1, 15–34 years as group 2, 35–59 years as group 3, and ≥ 60 years as group 4. Initial and final best corrected visual acuity (BCVA) were converted into logarithm of the minimum angle of resolution (LogMAR) units to make an analysis. Inclusion criteria required that participants did not have a previous ocular surgical, ocular trauma history and follow up period over 1 month. Exclusion criteria were a history of any ocular disease or any systemic disease with ocular findings, previous ocular surgery, laser therapy and follow-up periods were less than 1 month.

Results: Eighty two (75.9%) male and 26 (24.1%) female 108 patients were included in the study. The mean age of the patients were 40.42 ± 17.79 . Visual improvement in group 1; 0.42 ± 0.40 LogMAR ($p = 0.021$), in group 2; 0.70 ± 0.50 LogMAR ($p < 0.01$), in group 3; 0.40 ± 0.45 LogMAR ($p < 0.01$) and in group 4; 0.25 ± 0.38 LogMAR ($p = 0.036$). Visual improvement statistically significantly correlated with patient's age ($p = 0.003$) initial vision ($p = 0.007$) and retinal disorder ($p = 0.002$).

Conclusion: Males more predisposed to ocular trauma. Also, the prognosis is not good for elderly patients with a large injury size, posterior segment disorders and intraocular foreign body.

Keywords: Trauma; Ocular globe injury; Intraocular foreign body; Retinal injury

Figure 1

[Abstract:0237]**Investigation of choroidal vascularity changes after dexamethasone treatment in diabetic macular edema**

Ali Safa Balci, Sehnaz Ozcaliskan, Seren Pehlivanoglu, Murat Arici, Ozgur Artunay
University of Health Sciences, Beyoglu Eye Training and Research Hospital, Istanbul, TÜRKİYE

Purpose: In this study, we aimed to examine the choroidal vascularity changes in patients who underwent dexamethasone implant for DME.

Materials: The files of patients who underwent IVD injection with the diagnosis of DME in our clinic were reviewed retrospectively. The study included 25 patients with regular follow-up at 1, 2, and 4 months before and after IVD injection, and measurements made with Topcon DRI Triton swept source OCT. 25 age- and gender-matched patients were taken as the control group. Central choroidal thickness (CCT) values were measured automatically from OCT images of patients who had IVD injection. OCT images were binarized with Image J, total choroidal area (TCA) and luminal area (LA) were separated by semi-automatic program and CVI value was calculated by dividing LA value by TCA value.

Results: Significant structural and choroidal changes were detected in patients with DME compared to the control group. While pre-injection CVI was $66.06\% \pm 33.1\%$, it was $68.73 \pm 24.17\%$ and $67.82 \pm 42.65\%$ at the 1st and 2nd months after injection, respectively ($p < 0.001$ and $p = 0.003$). There was no significant change in CVI values at the 4th month after the injection compared to the pre-injection measurements. While LA measurements did not show a statistically significant difference from the baseline values at the 1st and 4th months after the injection, a statistically significant increase was observed in the LA values at the 2nd month. A statistically significant decrease was found in SA measurements at 1 and 2 months after IVD injection.

Conclusion: CCT and CVI measurements in patients with DME may vary compared to healthy adults. In addition to providing the resolution of edema in DME, IVD can also change the vascularity of the choroid. Longitudinal studies with a prospective design may enable CVI to be defined as a parameter in the follow-up of patients with DME.

Keywords: Choroidal vascularity index, diabetic macular edema, intravitreal dexamethasone injection

[Abstract:0260]**EVRS: 10 years**

Perfecto Elpidio Octavio Roy Cagampang III
Manila Doctors Hospital

Oral presentation to inspire young EVRS members in line with the ideals and vision of EVRS. It chronicles the ten years as a member of EVRS thru the words of mentors, colleagues and friends.

Keywords: EVRS

[Abstract:0262]**Management of Complex Rhegmatogenous Retinal Detachment and its Complications**

Hussain Khaqan¹, Tayana Avanesova², Tural Galbinov³, Muhammad Samir Alhadad⁴
¹PGMI,AMC,LGH,Lahore
²Central Clinical Hospital of Presidential Administration,Moscow
³Azerbaijan Medical University, Dept of Ophth
⁴Alexandria University, Egypt

Purpose: To present management of retinal detachment, different techniques, complications and management of per operative, post operative complications.

Methods: Update on Vitrectomy Machines, Trocars (Different Gauges), Vitrectomy Cutters (Different Gauges), Endo Lights (Different Gauges), Lasers (Different Types) & Endotamponades.

Surgical Techniques will be PNR, Buckling, PPV with Gas, PPV with Oil, Encirclement & PPV And challenging cases with video presentations and Tips & Tricks how to manage complex cases and how to manage per operative, post operative complications.

Results: At the end of course participants will have good understanding about vitrectomy machines, disposables used in different techniques to manage the retinal detachment, complex cases, different techniques and how to manage complications in complex cases.

Keywords: Retinal Detachment, Complex Cases, Course

[Abstract:0263]**Changes in the Schlemm's canal microarchitecture after silicone oil removal in retinal detachment**

Gülşay Yalçınkaya Çakır¹, Seren Pehlivanoglu², Ihsan Çakır², Halil Özgür Artunay²
¹Patnos State Hospital, Agri, Turkey
²Beyoglu Eye Training and Research Hospital, Istanbul, Turkey

Purpose: To evaluate the alterations in the Schlemm's canal (SC) morphology after the removal of silicone oil (SO) in eyes that had a pars plana vitrectomy (PPV) with swept-source

optical coherence tomography (OCT).

Methods: It was a cross-sectional study of 15 eyes of 15 patients (study group) and 15 fellow eyes of them (control group). The anterior chamber angle images at the temporal corneoscleral limbal area were captured with the line anterior segment mode of swept-source OCT before and one week after SO removal of eyes had undergone PPV with SO tamponade. The images were processed using the ImageJ program to measure the anteroposterior diameter (SC-APD), the radial diameter (SC-RD), and the cross-sectional area of the SC (SC-CSA).

Results: The indication for PPV with SO was retinal detachment (RD) in 12 eyes, tractional RD in 3 eyes. Nine of 15 patients were bilateral pseudophakic. The mean age was 62.47 ± 7.44 years. The mean SO removal time was 6.13 ± 2.13 months. In the study group, the mean intraocular pressures were 21.87 ± 9.73 and 15.27 ± 7.28 mmHg pre- and postoperatively, respectively ($p=0.04$). The mean SC-APD were 171.25 ± 66.47 and 256.38 ± 111.36 mmHg pre- and postoperatively, respectively ($p=0.02$). The mean SC-RD were 7.38 ± 5.45 and 28.89 ± 21.38 mmHg pre- and postoperatively, respectively ($p=0.02$). The mean SC-CSA were 1238.50 ± 689.74 and 4478.20 ± 875.38 mmHg pre- and postoperatively, respectively ($p=0.03$). Although the SC-RD was significantly higher (23.33 ± 10.51) in the control group compared to the preoperative value of the study group ($p=0.001$), other measurements were similar ($p=0.07$). In addition, there was a negative correlation between the SO removal time and the change in SC-APD in the study group ($p=0.02, r=-0.778$).

Conclusions: There was an enlargement of the SC after SO removal. These results show the mechanical compression effect of SO on the SC. Permanent structural changes may occur in SC as the duration of SO stays in the eye is prolonged.

Keywords: Intraocular pressure, Schlemm's canal, silicone oil removal

[Abstract:0265]

Evaluation of the effects of silicone oil and C3F8 gas tamponade with pattern-multifocal electroretinography in patients with rhegmatogenous retinal detachment

Murat Karapapak, Ece Özal, Serkan Güler, Hakan Baybora, Serhat Ermiş, Yusuf Cem Yılmaz, Şerife Çiloğlu Hayat, Sadık Altan Özal

University of Health Science, Basaksehir Cam and Sakura City Hospital, Ophthalmology, Istanbul, Turkey

Purpose: It was aimed to compare the pattern erg (PERG) and multifocal erg (MfERG) evaluations of patients who underwent vitreoretinal surgery for freshly macula-off rhegmatogenous retinal detachment and were given silicone oil and perfluoropropane gas (C3F8) as tamponade.

Methods: Fifteen of the patients included in the study were given silicone oil (Group 1) as tamponade, and C3F8 (Group 2) was given to fifteen patients. The other healthy eyes of

these patients who did not have retinal detachment were included in the study as the control group (Group 3). Detailed ophthalmoscopic examination, number of retinal tears, time between visual loss and surgery, and follow-up periods of all patients included in the study were evaluated. All patients were evaluated for PERG and MfERG with the Diopsys® NOVA™ (Diopsys, Inc., Pine Brook, NJ) device and compared with the control group.

Results: Fifteen patients were included in groups 1 and 2, and of both groups, 9 were male and 6 were female. The mean age of group 1 patients was 58.3 ± 7.1 , and 54.1 ± 7.4 years of group 2 patients. While the preoperative BCVA value of groups 1 and 2 did not differ significantly, the postoperative BCVA value was significantly lower in group 1, 0.3 ± 0.2 - 0.5 ± 0.2 , respectively. ($p=0.024$) The mean follow-up period was 8.3 ± 5.9 months for group 1 and 8.6 ± 2.3 months for group 2. No significant difference was observed between all groups in the PERG evaluation. In MfERG R1 and R2 evaluation, group 2's N1P1 nV/d2 and N2P1 Nv/d2 results were found to be significantly higher than the other groups. ($p<0.05$).

Conclusion: In freshly macula-off rhegmatogenous retinal detachment patients, the use of tamponade gas was found to be more successful in terms of visual outcome and MfERG evaluation compared to silicone. These results may be due to the direct or indirect retinal damage mechanisms of silicone oil.

Keywords: C3F8 gas, retinal detachment, silicone oil

[Abstract:0282]

Role Of Optical Coherence Tomography Findings In Visual Prognosis After Epiretinal Membrane Surgery

Bilge Tarım, Nil Irem Uçgun Zeki Fikret, Cenk Zeki Fikret
University of Health Sciences, Ankara City Hospital, Department of Ophthalmology

Purpose: To evaluate the macular optical coherence tomography findings in patients undergoing epiretinal membrane surgery and to examine their relationship with visual acuity

Methods: 25 patients who underwent vitreoretinal surgery with epiretinal membrane (ERM) and internal limiting membrane peeling were included in this retrospective study. Visual acuity (VA), intraocular pressure (IOP) and macular thickness in central (CMT) and also in 4 quadrants, average macular thickness (AMT), ganglion cell layer (GCL) were measured preoperatively and postoperatively at 1st, 3rd, 6th months evaluated by optical coherence tomography (OCT). In addition, presence of preoperative disorganization of retinal inner layer (DRIL), intraretinal fluid (IRF), subretinal fluid (SRF), macular hole, foveal contour and postoperative dimpling, cystoid degeneration were noted.

Results: While the mean age of the patients was 68.32 ± 7.47 years; 56% (14 patients) were male and 44% (11 patients) were female. At the end of the surgery; 48% C3F8, 32% air,

12% SF6 and 8% silicone were given as tamponade. 64% of the patients were diabetic ERM and 36% were idiopathic ERM. While VA at postoperative 6th month was found to be significantly higher than preoperatively ($p < 0.01$); no significant difference was found in postoperative IOP values compared to the preoperative values ($p > 0.05$). Central, superior, inferior, temporal macular thickness ($p < 0.01$, for all) and AMT ($p < 0.05$) at postoperative 6th months were lower than preoperative values. There was no significant difference between pre- and postoperatively in terms of GCL ($p > 0.05$). The presence of preoperative DRIL, IRF, SRF and the presence of postoperative dimpling and cystoid degeneration did not have any effect on VA at the postoperative 6th month ($p > 0.05$).

Conclusion: Visual gain after ERM surgery becomes significant after 6 months, and in this study, there was a decrease in macular thickness in the central, superior, inferior and temporal quadrants during the period of increased visual acuity. In addition, morphological changes in OCT were not associated with visual prognosis.

Keywords: Epiretinal Membrane, Optical Coherence Tomography, Vitreoretinal Surgery

[Abstract:0283]

Foveal Avascular Zone Distortion in Epiretinal Membrane by Optical Coherence Tomography Angiography

Ilkay Kilic Muftuoglu¹, William R Freeman²

¹Istanbul Training And Research Hospital, Istanbul, Türkiye

²Jacobs Retinal Center Shiley Eye Institute University of California San Diego, USA

Purpose: To show the morphologic changes on the foveal avascular zone (FAZ) in patients with epiretinal membrane (ERM) using optical coherence tomography angiography (OCTA) and to demonstrate the correlation between distortion of FAZ and features of the ERM.

Methods: FAZ eccentricity index (longest diameter of FAZ/shortest diameter of FAZ) was measured in 52 patients with ERM and compared with 27 healthy subjects' values. The density of the ERM was quantified using a grading scale (0-3) on multicolor scanning laser images, and spectral-domain OCT characteristics of the eyes were assessed.

Results: Of the 52 eyes with ERM, 31 eyes (59.61%) showed some foveal remodeling, including full (13.46%) or partial (30.76%) apparent vascularization of FAZ, presence of a vessel crossing the fovea (9.61%), and horizontal or vertical elongation of FAZ (5.76%). The mean FAZ eccentricity index was 0.84 ± 0.46 (range: 0.0-1.86) in eyes with ERM and 0.98 ± 0.07 (range: 0.96-1.02) in the control subjects, respectively ($P = .02$). There was a negative significant correlation between FAZ eccentricity index and central macular thickness ($P = .04$).

Conclusion: Thickening of the central fovea leads to foveal remodeling in ERM eyes, and OCTA enables the visualization of architectural FAZ changes

Keywords: erm, oct, octa

[Abstract:0284]

Factors Related to Cotton Sign Ball Sign Secondary to Epiretinal Membrane

Ilkay Kilic Muftuoglu¹, William R Freeman²

¹Istanbul Training And Research Hospital, Istanbul, Türkiye

²Jacobs Retinal Center Shiley Eye Institute University of California San Diego, USA

Purpose: To demonstrate factors related to the presence of subfoveal detachment (SD) secondary to epiretinal membrane (ERM) and to characterize the predictors for the resolution of SD after membrane peeling.

Methods: A retrospective chart review was conducted for the patients who underwent pars plana vitrectomy for the idiopathic ERM peeling. Preoperative spectral domain optical coherence tomography characteristics of the eyes including central foveal thickness, foveal center point thickness, presence of intraretinal cyst, continuity of the membrane, area of the membrane within fovea (1 mm), and entire macula (6 mm) were evaluated to find the best predictors for the presence of SD. These predictors as well as perioperative parameters including use of internal tamponade and volume of SD were considered for time of resolution of SD.

Results: Of 158 included eyes, 20.2% eyes (32 eyes) had SD, and the presence of SD was significantly related to involvement of the membrane within the macula. After surgery, SD completely resolved in 90.6% of eyes (29 eyes) at a median of 2.97 months (range: 0.03-12.0 months). The area of the membrane within fovea was the only significant predictor for time to resolution of SD (hazard ratio = 1.20, 95% confidence interval = 1.100-1.324, $P = 0.021$). A small percent of eyes showed some further changes including fluctuation (6.2%) or persistence (3.1%) of fluid.

Conclusion: A larger extension of ERM over the macula is related to higher likelihood of the presence of SD. Time for resolution of subfoveal detachment does not seem to be affected by the preoperative and perioperative factors except the extent of membrane within 1,000 μ m of the fovea.

Keywords: erm, cotton ball, oct

[Abstract:0289]

Full Thickness Corneal Patch Graft Outcomes in Traumatic or Spontaneous Corneal Perforation

Sibel Ahmet, Nilay Kandemir Beşik, Ahmet Kırız

University of Health Sciences, Beyoglu Eye Training and Research Hospital, Istanbul

Purpose: To report the indications, long-term results, and prognostic factors for the success of corneal patch grafts.

Methods: The files of patients who underwent a full-thickness corneal patch graft procedure for traumatic or spontaneous

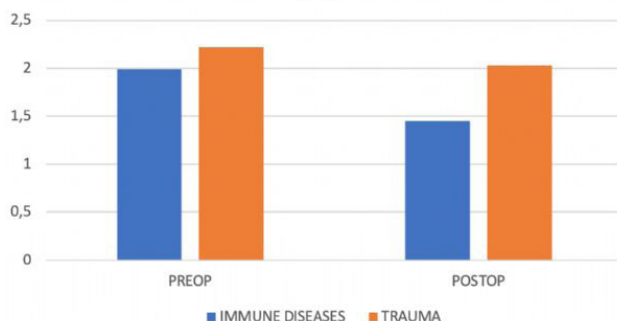
traumatic corneal perforation in our clinic between 2018 and 2022 were reviewed retrospectively. Demographic information, follow-up times, preoperative and postoperative best corrected visual acuity (BCVA, logMAR) at 1, 3, 6, 12, 24, and 36 months, indications, and complications of the patients were recorded.

Results: Twenty-three eyes of 23 patients (17 male, 6 female) were included in the study. The mean age of the patients was 53.30 ± 23.5 years (range 4-82), and the mean follow-up time was 10.22 ± 12.83 months (range 1-41 months). Anatomical success was achieved in all patients; a second corneal patch graft application was required in 2 (8.7%) cases due to graft failure. The mean best corrected visual acuity was 2.08 ± 1.14 logMAR preoperatively, and 1.68 ± 1.11 logMAR at the last postoperative follow-up (Wilcoxon Signed Ranks Test, $p=0.023$). The cause of perforation was trauma in 9 cases (39.1%) and immune diseases in 14 cases (60.9%). There was no statistically significant difference between the two groups in postoperative visual acuity levels (Mann-Whitney U, $p=0.196$). The corneal patch graft location was central in 8 (34.8%) cases and paracentral in 15 (65.2%) cases. Postoperative visual acuity levels were 2.34 ± 0.93 logMAR in central grafts and 1.33 ± 1.05 logMAR in paracentral ones. A statistically significant difference was observed between the two groups (Mann-Whitney U, $p=0.047$).

Conclusion: Corneal patch grafting has recently become a preferred method in cases of traumatic or spontaneous perforation. In this study, anatomical and functional success was achieved. Different optical procedures can be applied at later stages for further visual rehabilitation.

Keywords: Corneal Spontaneous Perforation, Corneal Traumatic Perforation, Corneal Patch Graft

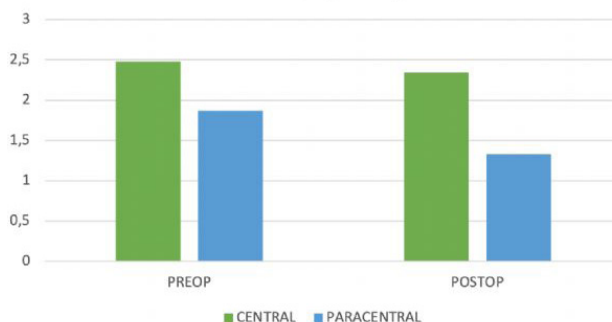
Graphic 1
BCVA (Log MAR)



Graphic of the mean preoperative and last postoperative follow-up BCVA levels in two groups with corneal perforation caused by trauma and immune diseases

Graphic 2

BCVA (Log MAR)



Graphic of the mean preoperative and last postoperative follow-up BCVA levels in two groups with corneal graft places central and paracentral

[Abstract:0290] CNVM in vogt koyanagi harada disease

Kshitij Raizada

Dr. Raizada Eye Centre, Bareilly, India

Vogt Koyanagi Harada Disease is a bilateral granulomatous panuveitis which may or may not have extra ocular manifestations. The disease usually manifests in females, mainly in the 2nd – 5th decade of life.

VKH disease is a T-cell-mediated autoimmune reaction against melanocytes, melanin, and retinal pigment epithelium (RPE). The disease usually manifests in 4 stages - i) Prodromal Stage ii) Uveitic Stage iii) Chronic Stage iv) Acute exacerbations and Complications.

CNVM is a late complication of VKH Disease and is reported in the literature in 2-15% of VKH cases.

We had a 36-year-old female, who presented to us with bilateral diminution of vision for 1 day. Visual loss was preceded by a headache for 2-3 days. Her BCVA was CF@1m bilaterally. There was bilateral granulomatous inflammation in the anterior segment. She was diagnosed with Vogt Koyanagi Harada Disease. She was initiated on Intra-Venous Methylprednisolone 1 gram x 3 days followed by oral prednisolone. The patient responded well to the treatment and she was 6/9 bilaterally one week later. Her oral steroids were tapered gradually and she was started on azathioprine.

The patient was lost to follow up, and she reported 6 months later with a drop in vision in the left eye for the past 15 days. Her BCVA in the left eye was CF@1m. She was diagnosed with CNVM in the left eye.

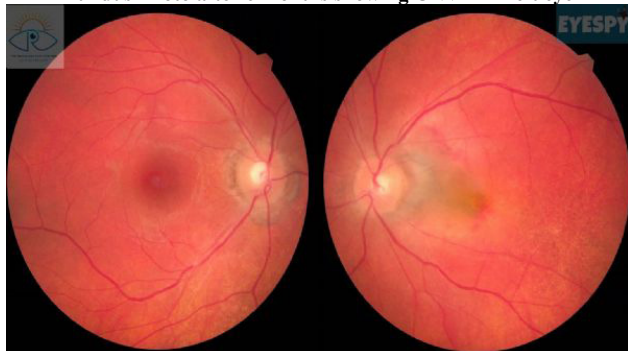
She was given 3 Intra-Vitreous Ranibizumab injections in the left eye at one month intervals.

After 3 doses, her BCVA in the left eye had improved to 6/24P.

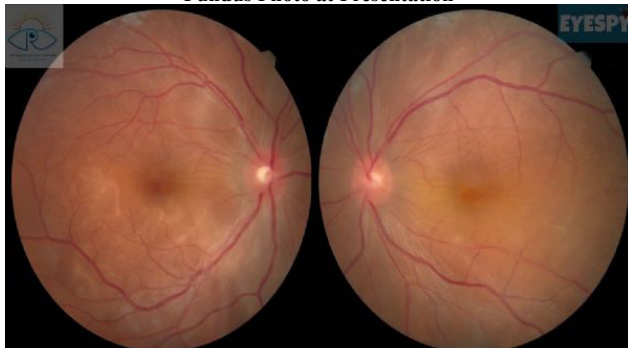CNVM in VKH Disease has a rare incidence. Through this case, we would like to throw light on the development of CNVM in VKH Disease and discuss its rarity, clinical features, diagnosis and management.

Keywords: VKH Disease, CNVM, Anti-VEGF

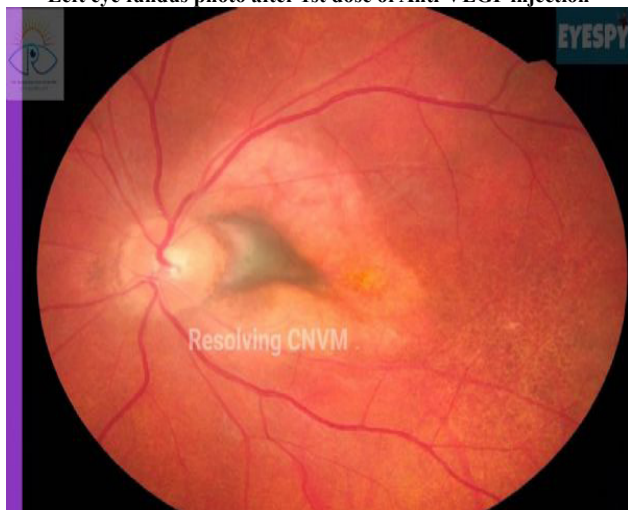Fundus Photo after 6 months showing CNVM in left eye



Fundus Photo at Presentation



Left eye fundus photo after 1st dose of Anti-VEGF injection



[Abstract:0305]

Relation of Optical Coherence Tomography Biomarkers and Visual Function in Diabetic Epiretinal Membrane

Güner Üney, Özlem Candan, Nurten Ünlü, Dicle Hazirolan, Gözde Orman

University of Health Sciences Ankara Training and Research Hospital

Purpose: To investigate the effect of optical coherence tomography (OCT) findings on visual function in epiretinal membrane (ERM) with diabetic retinopathy (DR).

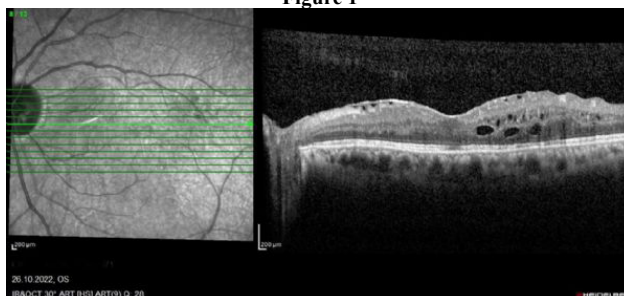
Material-Method: Cases with DR having ERM findings on OCT were examined. Demographic data, DR stage, central foveal thickness (CFT), best corrected visual acuity (BCVA), ellipsoid zone (EZ) damage, disorganization of retinal inner layers (DRIL), presence of lamellar hole, cystoid degeneration, shape of the foveal contour were examined. The effect of the OCT findings on BCVA was evaluated.

Results: The CFT of 117 cases was $403.2 \pm 119.2 \mu\text{m}$ and the BCVA was $0.61 \pm 0.57 \log\text{MAR}$. Proliferative diabetic retinopathy (PDR) was present in 41% of cases. There was EZ damage in 56.6%, DRIL in 40.2%, cystoid degeneration in 35%, and lamellar hole in 19.7% of the cases. In 67.5% of the cases, the foveal contour was distorted due to grade 3 ERM, lamellar hole and cystoid degeneration. There was a statistically significant positive correlation between CFT and BCVA logMAR value ($r=0.4$; $p=0.0001$). In the presence of EZ disruption ($p=0.0001$), DRIL ($p=0.0001$) and cystoid degeneration ($p=0.002$) BCVA was significantly lower. Univariate analysis revealed that the presence of cystoid degeneration ($p=0.01$) and CFT ($p=0.01$) had a statistically significant effect on visual acuity. The presence of PDR did not have a negative effect on BCVA in ERM cases ($p=0.41$).

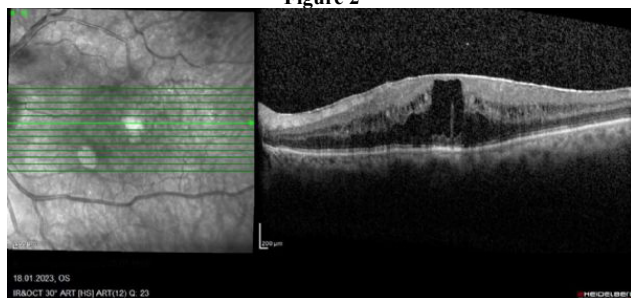
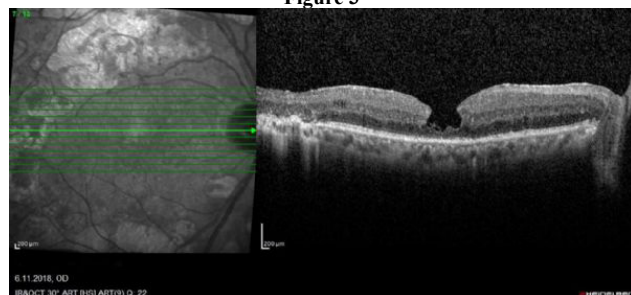
Conclusion: Ellipsoid zone damage, presence of DRIL and cystoid degeneration adversely affect visual acuity in ERM cases with diabetic retinopathy. When all factors were evaluated together, CFT and the presence of a large cyst in the fovea were determined as the most important reason for reducing visual acuity.

Keywords: Diabetic retinopathy, Epiretinal membrane, Optical coherence tomography

Figure 1



Epiretinal membrane sparing foveal contour.

Figure 2*Epiretinal membrane with cystoid degeneration.***Figure 3***Epiretinal membrane with lamellar macular hole.***[Abstract:0318]****Large Retinal Hole following injury by Q-Switched Nd:YAG Laser**

Kshitij Raizada

Dr. Raizada Eye Centre, Bareilly, India

Lasers are widely used in cosmetic medicine, scientific research, and industry. The eye can be injured during cosmetic laser procedures involving the face. Accidental laser discharge during the preparation of a laser device and not using protective goggles are the main causes of laser injuries.

A Dermatology Post Graduate reported to us with complaints of sudden onset diminution of vision in her right eye. She had unprotected exposure to Q-Switched Nd:YAG Laser while performing a cosmetic procedure. Her BCVA in the right eye was 1/60. On Fundus examination, there was a large retinal hole, supero-temporal to the superior vascular arcade, oozing blood in the vitreous cavity.

A barrage Laser (Double Frequency Nd:YAG Laser - 532 nm) was done around the retinal hole to prevent the development of Retinal Detachment. The large Retinal Hole was successfully barraged. The patient did not develop retinal detachment and the vitreous haemorrhage gradually absorbed leading to complete recovery of the vision of the patient. Her final BCVA was 6/6.

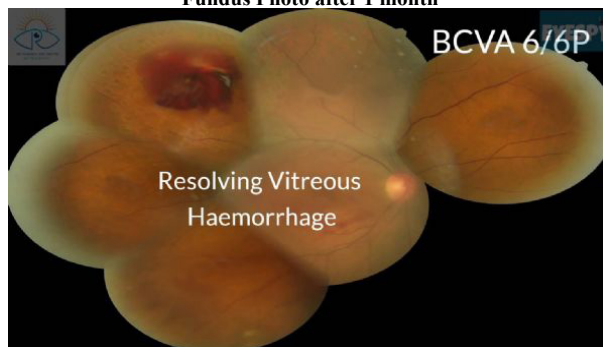
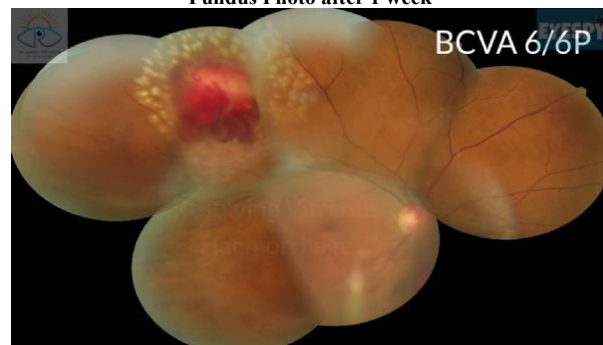
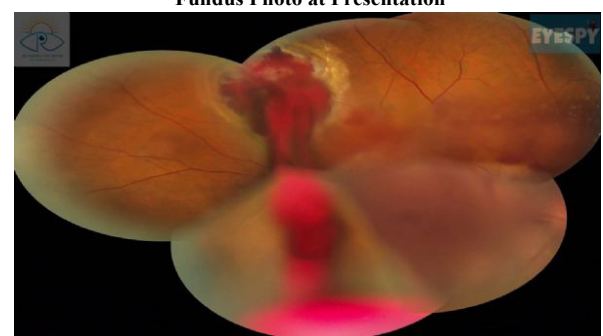
Long term complications include Choroidal Neovascularisation at the site of injury and long term follow up of the patient is required to keep a check for the same.

The literature has very few case reports of a treating doctor

being injured by a laser while administering treatment. This unusual and rare case report highlights the potential hazards, lasers pose for Medical Practitioners. The report throws light on the possible ocular injuries that can be caused by Cosmetic Lasers and ways that can prevent such debilitating injuries.

Lasers are being used on a widespread basis for cosmetic purposes. Users need to be aware of the potential hazards of such lasers and must use eye protection at all times while using the laser. Laser injuries to the eye can be devastating.

Keywords: Q-Switched Nd:YAG Laser, Large Retinal Hole, Vitreous Haemorrhage

Fundus Photo after 1 month**Fundus Photo after 1 week****Fundus Photo at Presentation**

[Abstract:0321]**Superior Inverted Internal Limiting Membrane Flap Technique in Idiopathic Macular Hole Surgery**

Emre Avcı, Ece Ozal, Murat Karapapak, Serhat Ermiş,
Yusuf Cem Yılmaz, Serife Ciloglu Hayat, Hakan Baybora,
Sadık Altan Ozal
*Başakşehir Çam ve Sakura Şehir Hastanesi, Göz Hastalıkları
Departmanı, İstanbul*

Aim: To evaluate the anatomical and functional outcomes of the superior inverted internal limiting flap technique, in cases with idiopathic macular holes.

Material-Method: Twenty two eyes of 22 patients who underwent pars plana vitrectomy combined with superior inverted flap technique were retrospectively evaluated. A detailed ophthalmologic examination and optical coherence tomography measurement were performed in all patients in the preoperative period and at 1st, 3rd and 6th month postoperatively. The anatomical closure rate, best corrected visual acuity (BCVA) were recorded. The pre- and postoperative ellipsoid zone (EZ), and external limiting membrane (ELM) defects were compared.

Results: Fourteen of 22 eyes were female and 8 were male. The average age of the patients were 64. Anatomic closure was achieved in all eyes during the postoperative period. Statistically significant improvement was observed in the comparison of preoperative BCVA values (mLogMAR 1.1318) of the patients with their postoperative 3rd month (mLogMAR 0.590), and 6th month (mLogMAR 0.440) BCVA values ($p<0,001$), $p<0,001$). A significant reduction in EZ defect size was observed at 6 months postoperatively compared to preoperative EZ defect size ($r = -0.446$, $p = 0.038$). A statistically significant reduction in the size of the ELM defect was observed at 6th month postoperatively ($p<0,001$). There was no significant correlation between the postoperative closure pattern and preoperative base hole diameter, minimum hole diameter and EZ defect width ($r=-0.135$, $p=0.52$). However, these macular hole parameters had a positive and significant correlation with each other.

Conclusion: We achieved a significant increase in BCVA level, high rates of anatomical closure and improvement in ellipsoid zone defects with the superior inverted flap technique in the treatment of idiopathic macular holes.

Keywords: Macular hole, superior inverted flap technique, ellipsoid zone

[Abstract:0323]**Epimacular membrane surgery. My way**

Wael Ahmed Ewais
*Department of Ophthalmology, Faculty of Medicine, Kasr alaini, Cairo
University, Cairo, Egypt*

I will describe in details my approach to Epimacular membrane (EMM) and Internal limiting membrane (ILM) peeling.

Technique: Infusion is stopped temporarily until the Brilliant Blue G stain (BBG) is injected. The surgeon identifies the EMM as the unstained area that is surrounded by a stained area. In case of a visible EMM edge; the surgeon grasps and peels the EMM. If not; ILM is stroked by the closed tip of the ILM forceps and ILM is peeled in the direction of the EMM till it can be entangled.

Then further injection of BBG is performed. And ILM peeling is then extended and completed.

Advantages of Double-staining
Proper identification of surrounding
ILM and underlying ILM remnants
Complete ILM removal
Minimal EMM recurrence
BBG isn't toxic to the macula.

Keywords: epimacular membrane, Internal limiting membrane, Brilliant Blue G

[Abstract:0324]**Giant Macular Hole in complex Trauma**

Wael Ahmed Ewais
*Department of Ophthalmology, Faculty of Medicine, Kasr Alaini, Cairo
University, Cairo, Egypt*

Single Case: Giant full thickness macular hole (traumatic), under silicone oil, in a case of a penetrating open globe injury, Traumatic retinal detachment, with recurrent PVR.

I performed an autologous retinal transplantation (ART) for the case

I'm presenting a Demonstration of the technique and outcome.

Keywords: Trauma, PVR, RD

[Abstract:0328]**Combined ILM Flap under Perfluorocarbon liquid and laser Ablation for Optic Disc Pit Maculopathy: Technique and Rationale**

Wael Ahmed Ewais

*Department of Ophthalmology, Faculty of Medicine, Kasr Alaini, Cairo University, Cairo, Egypt***Technique:**

- Triamcinolone acetate injection
- BBG staining
- PFC injection
- Laser temporal to the optic disc
- ILM Flap creation and embedding into the pit under PFC
- PFC-Air exchange

Advantages of PFC

- Easy placement (Inversion) of ILM
- No Eversion or Displacement of the flap

Disadvantages of PFC

- Additional cost
- Incomplete removal of PFC, Foveal Toxicity

Keywords: Optic disc Pit, ILM flap, perfluorocarbon**[Abstract:0330]****Retinal Push Technique during vitrectomy for primary retinal detachment in children**

Wael Ahmed Ewais

*Department of Ophthalmology, Faculty of Medicine, Kasr Alaini, Cairo University, Cairo, Egypt***Purpose:** To report anatomical and functional outcome of “Retinal push technique” in patients for whom primary vitrectomy was performed for retinal detachment.**Methods:** Retrospective consecutive case series. Twenty-six eyes of twenty-six children, for whom vitrectomy had been performed for primary retinal detachment, were identified. Bimanual peeling of the posterior hyaloid had been performed using a Tano scraper or cutting probe in one hand, and forceps in the other hand. Retina had been pushed by the blunt scraper or probe instead of pulling endlessly by a probe or forceps.

Outcome measures: anatomical reattachment, and iatrogenic retinal breaks.

Results: Primary reattachment occurred in 23 / 26 eyes, secondary reattachment occurred in 25 / 26 eyes (96.2%). Iatrogenic retinal breaks were induced in 2 cases (one break in each).**Keywords:** Retinal Detachment, Retinal Push, Vitrectomy**[Abstract:0333]****To drain or not to drain**

Mahmood Othman Mekki

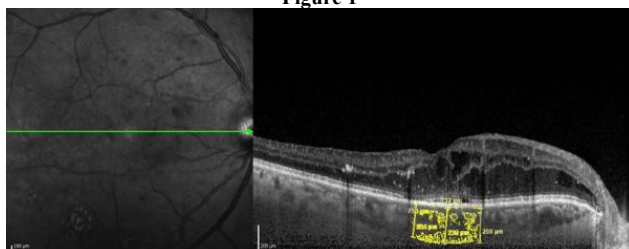
*Al Mashreq Eye Center, Cairo, Egypt.***Abstract Objective:** To show the result of avoiding draining subretinal fluid in cases of tractional retinal detachment (TRD).**Methods:** A case of a 48 yrs old female patient with diabetic TRD underwent 23 G pars plana vitrectomy (PPV) with dissection, segmentation and peeling of all pre-retinal tractional membranes without creating any break. Retina was left under air tamponade.**Results:** Few weeks after the surgery visual acuity (VA) improved significantly (from CF 50 cm pre-operatively to 0.15 post-operatively).**Conclusion:** Avoiding drainage of subretinal fluid in cases of TRD carries great post operative results, avoiding the complications of unnecessary drainage retinotomy.**Keywords:** PPV, TRD, Drainage**[Abstract:0340]****The effect of Dexamethasone implant application on the morphological and vascular structure of the choroid in diabetic macular edema with inflammatory biomarkers**Cemal Ozsaygılı¹, Nurettin Bayram², Demet Mutlu¹¹Kayseri City Hospital, Department of Ophthalmology, Kayseri, TURKEY²Etilik City Hospital, Department of Ophthalmology, Ankara, TURKEY**Purpose:** To examine the effects of intravitreal dexamethasone implant (IVD) administered after 3 months of loading dose intravitreal bevacizumab injection on choroidal thickness (CT) and choroidal vascularity index (CVI) in eyes with treatment-naïve diabetic macular edema (DME).**Methods:** In treatment-naïve DME cases with inflammatory biomarkers, IVD implant (0.7 mg) was administered after 3 loading doses of intravitreal bevacizumab injection (1.25 mg/0.05 ml). CT at a distance of 750 µm from the subfoveal, nasal and temporal and subfoveal (fovea-centered 1.5 mm) CVI measurements were performed. CT and CVI before IVD, and 1, 2, 3 months after IVD measured and compared. The mean CT measured from subfoveal, nasal, and temporal 750 µm distance was expressed as mean CT. The choroid was imaged using the Spectralis Domain (SD) OCT enhanced depth imaging (EDI) mode. CVI (ratio of lumen area to total choroidal area) was calculated with ImageJ software.**Results:** Of the 32 patients included in the study, 19 were female and 13 were male. The mean age of the patients was 58.30±7.24 years. The mean CT of the patients before IVD implantation was 328.27±10.61 µm, and the subfoveal CVI was 65.6%. At 1 month of IVD implantation, the mean CT was 277.77±16.54 µm, and the subfoveal CVI was 63.12% (P< 0.05 for all). At 2 months of IVD implantation, the

mean CT was $257.30 \pm 10.39 \mu\text{m}$, and the subfoveal CVI was 61.10% ($P < 0.05$ for all). At 3 months of IVD implantation, the mean CT was $239.80 \pm 7.57 \mu\text{m}$, and the subfoveal CVI was 60.09% ($P < 0.05$ for all).

Conclusion: It was observed that IVD implant applied following anti-VEGF injection with the diagnosis of DME caused significant changes in both CVI and CT. The decrease in CVI in parallel with the decrease in CT in the follow-ups after IVD application showed that vascular changes were effective in thinning the choroid.

Keywords: Choroidal vascular index, Dexamethasone implant, Diabetic macular edema

Figure 1



Calculation of submacular choroidal vascular index (CVI) with ImageJ program on EDI-OCT image

[Abstract:0355]

Intraretinal hyperreflective lines in eyes with vitreomacular adhesion

Fatma Bağcı, Mehmet Çitırık

Ophthalmology Department, Etlik City Hospital, Ankara, Türkiye

Purpose: To investigate the prevalence of intraretinal hyperreflective lines (IHL) in eyes with vitreomacular adhesion.

Setting: A retrospective study in Ophthalmology Consult - Ophthalmology Department of the Etlik City Hospital, Ankara, Turkey.

Methods: 49 eyes of 49 patients with VMA were included. Spectral domain optical coherence tomography (SD-OCT) volume scans were analysed for the presence of a central vertical hyperreflective line. The sequential OCT images of the fellow eyes of patients with IHL were further studied to analyse the changes in vitreous interface status during the follow up period.

Result: IHL was observed in 10 of 49 eyes (20.4%) of patients with vitreomacular adhesion (VMA). The vitreous interface status of patients with IHL included VMA (eight eyes) and posterior hyaloid detachment on foveal region (two eyes). In fellow eyes, 5 VMA, 2 vitreomacular traction (VMT), 2 full thickness macular hole (FTMH), 1 full thickness macular hole rhegmatogenous retinal detachment (FTMH-RRD) were detected. At later periods, in the 2 eyes with VMA, lamellar and full-thickness macular hole developed. 5 of fellow eyes displayed IHL in the course of time.

Conclusion: The presence of IHL detected by SD-OCT in patients with VMA may indicate that posterior hyaloid firmly attached to the fovea. This in turn may reflect the onset of foveal dehiscence due to the structural changes on foveal architecture. The increase in the prevalence of vitreomacular interface disease (VMID) in fellow eyes of patients with IHL may require close follow up.

Keywords: Vitreomacular adhesion, intraretinal hyperreflective lines

Figure 1: Intraretinal hyperreflective line (IHL) detected by SDOCT

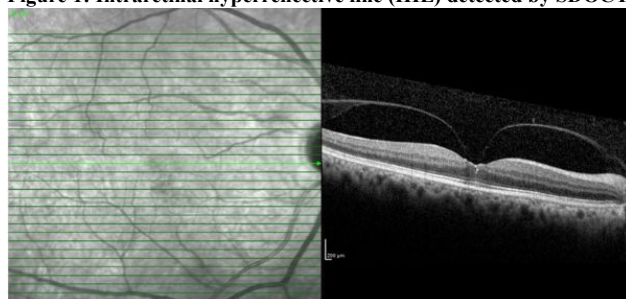


Figure 2: Posterior hyaloid detachment and IHL

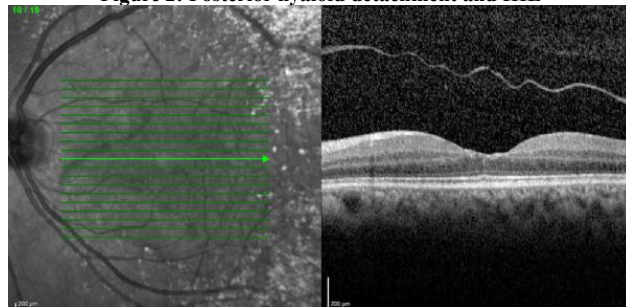
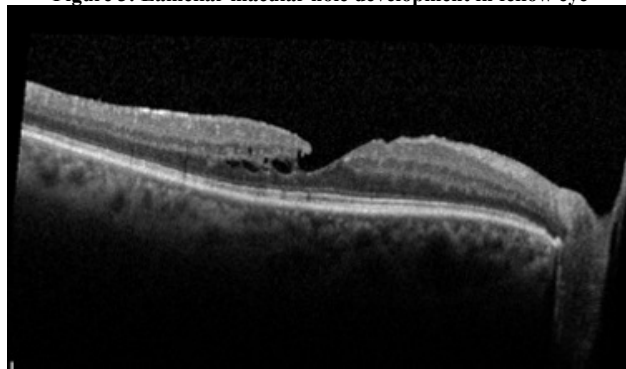


Figure 3: Lamellar macular hole development in fellow eye



[Abstract:0361]

Comparative analysis of OCTA and ultra-wide field angiography in cases of branch retinal vein occlusion

Muhammed Altinisik, Deniz Dilan Karabacak, Selin Deniz Oruc, Mustafa Erdogan

Manisa Celal Bayar University, Department of Ophthalmology, Manisa, Turkey.

Purpose: To compare the interaction of central and peripheral pathologies in branch retinal vein occlusion (BRVO) cases

using optical coherence tomography angiography (OCTA) and ultra-widefield fluorescein angiography (UWFA).

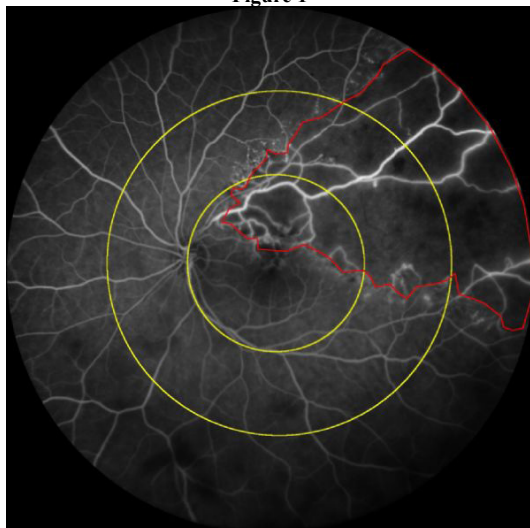
Methods: Simultaneous OCTA (Optovue) and UWFA (Spectralis) measurements were performed in treatment-naïve BRVO cases. UWFA images were divided into three areas as central, mid-peripheral and far-peripheral with Image-J program (Figure 1). The ischemic index was calculated by dividing the ischemic areas by the total area. Foveal avascular zone (FAZ) metrics and retinal vascular densities (VD) were calculated with 6*6 mm OCTA scans. The presence of subretinal fluid (SRF) was recorded. The relationship between OCTA metrics, ischemic index and macular edema was analyzed.

Results: Thirty-eight cases, 26 (68.4%) women, were included in the study. The mean age was 64.5 ± 8.86 years, and the visual acuity was $\log\text{MAR } 0.58 \pm 0.39$. Macular edema was detected in 26 (68.4%), and SRF was present in 16 (61.5%) cases. The mean ischemic index was $27.56 \pm 12.36\%$. The distribution of ischemic index by zones was as follows: $13.52 \pm 7.95\%$ in the far-periphery, $9.73 \pm 4.77\%$ in the mid-periphery, and $4.31 \pm 2.62\%$ in the central. There was no correlation between VD measurements and ischemic index in any quadrant ($p > 0.05$). Central macular thickness (CMT) was associated with central ischemic index ($r = 0.6$, $p = 0.08$). While the FAZ area was not affected by the peripheral ischemic index, it was negatively correlated with the central ischemic index ($r = -0.44$, $p = 0.048$) and CMT ($r = -0.46$, $p = 0.04$). The central ischemic index was found to be significantly higher in SRF cases ($5.88 \pm 2.34\%$ vs $3.15 \pm 2.24\%$; $p = 0.02$).

Conclusion: OCTA VD and FAZ measurements may not have a significant role in predicting the severity of peripheral ischemic index in BRVO cases. The increase in central ischemia may cause the formation of SRF, increasing CMT and decreasing the OCTA FAZ area, contrary to expectations.

Keywords: Optical coherence tomography angiography, branch retinal vein occlusion, ultra-wide field fluorescein angiography

Figure 1



[Abstract:0362]

Optical coherence tomography angiography changes after surgery for optic disc pit maculopathy: a case series and literature review

Muhammet Kazım Erol¹, Melih Akıdan², Birumut Gedik³, Elçin Süren¹

¹University of Health Sciences, Antalya Education and Research Hospital, Department of Ophthalmology, Antalya/Turkey

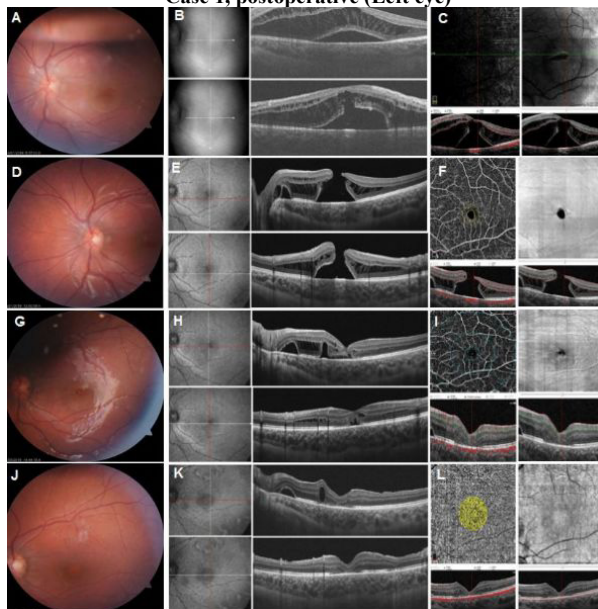
²Antalya Kepez State Hospital, Department of Ophthalmology, Antalya/Turkey,

³Antalya Serik State Hospital, Department of Ophthalmology, Antalya/Turkey,

We report the optical coherence tomography angiography (OCTA) outcomes of six consecutive patients with optic disc pit maculopathy (ODP-M) who were treated with 25-gauge pars plana vitrectomy (PPV). Case 1 is a 18-year-old female patient with ODP-M with an outer retinal hole. After surgery, a full-thickness macular hole developed. Following the second surgery performed three months later, maculopathy and hole were observed to resolve. Case 3 is a 38-year-old male patient who had maculopathy with outer retinal hole similar to the first case. Maculopathy resolved completely after surgery. Case 2 (23-year-old female), Case 4 (50-year-old male), Case 5 (40-year-old male) and Case 6 (42-year-old female) patients who was found to have a marked decrease in maculopathy after surgery. In all 6 cases, best-corrected visual acuity (BCVA) improved after vitrectomy, there was anatomical improvement on optical coherence tomography (OCT), vascular density and flow increase, a decrease in the foveal avascular zone (FAZ) area was observed on OCTA.

Keywords: Macular hole, optical coherence tomography angiography, optic disc pit maculopathy

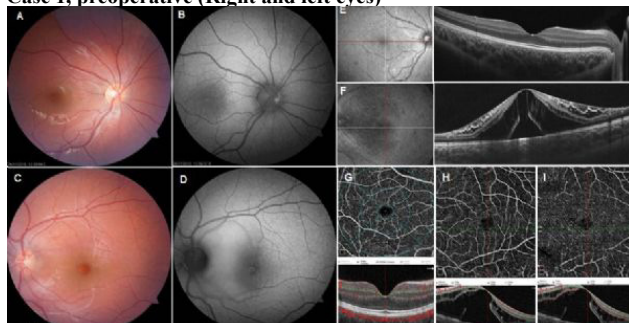
Case 1, postoperative (Left eye)



A) 1 week, fundus image; gas tamponade resorbed, B) 1 week, EDI-OCT images; outer nuclear layer schisis, intraretinal+subretinal fluid with

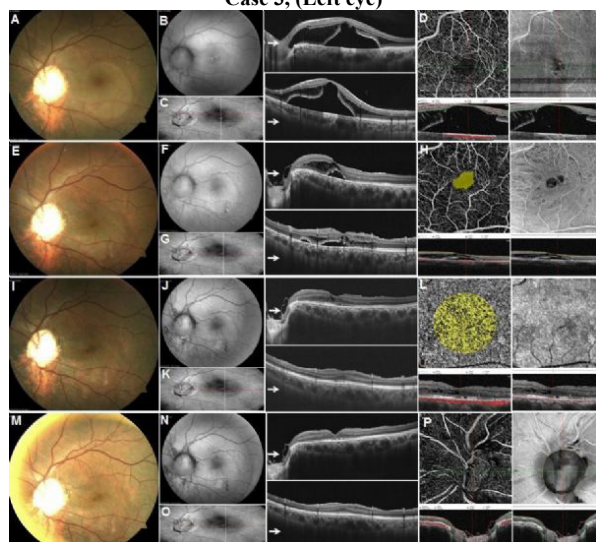
outer retinal hole persist, C) 1 week, OCTA outer retina cross-section (B-scan) and En face images, D) 3rd month, fundus image; macular hole appears, E) 3rd month, EDI-OCT images; full-thickness macular hole is present, F) 3rd month, retinal FAZ area's cross-section with OCTA (B-scan) and En face images, G) 6th month, fundus image; no serous macular detachment and hole, slightly irregular appearance of the foveal contour, H) 6th month, EDI-OCT images; subretinal fluid resolved, hole closed and cystic changes are present, I) 6th month, OCTA superficial capillary vascular density measurement rings and En face images, J) 12th month, fundus image; subretinal fluid not present, foveal irregularity regressed, K) 12th month, EDI-OCT images; cystic changes decreased, IS/OS band restoration continued, L) 12th month, OCTA choriocapillaris flow area and En face images.

Case 1, preoperative (Right and left eyes)



A, C) Fundus images; normal view in the right eye, while in the left eye, ODP associated with serous macular detachment on the temporal part of the OD, B, D) Fundus autofluorescence (FAF) images; normal view in the right eye, while in the left eye, iso-fluorescence in the serous detachment area, E, F) Enhanced depth imaging optical coherence tomography (EDI-OCT) images; normal OCT view in the right eye, while in the left eye, outer nuclear layer schisis, intraretinal+subretinal fluid with outer retinal hole, G) OCTA superficial vascular density measurement rings of right eye, H, I) OCTA superficial and deep capillary plexus cross-section (B-scan) images of left eye, respectively.

Case 3, (Left eye)



A) Preoperative, fundus image; ODP-M associated with serous macular detachment and schisis, B) Preoperative, FAF image; iso-fluorescence in serous detachment area and hyper-autofluorescence due to a few precipitates in the central area, C) Preoperative, EDI-OCT images (arrows); outer nuclear layer schisis, intraretinal+subretinal fluid with outer retinal hole, D) Preoperative, OCTA superficial capillary plexus cross-section (B-scan) and En face images, E) 3rd month, fundus image; serous macular detachment appears to be regressed, F) 3rd month, FAF image; G) 3rd month, EDI-OCT images (arrows); marked improvement, little subretinal fluid present, H) 3rd month, OCTA superficial non flow area and En face images, I) 9th month, fundus image; improvement in fundus findings, J)

9th month, FAF image, K) 9th month, EDI-OCT images (arrows); subretinal fluid resolved, IS/OS restoration, L) 9th month, OCTA choriocapillaris flow area and En face images, M) 12th month, fundus image, N) 12th month, FAF image, O) 12th month, EDI-OCT images (arrows); almost total recovery, IS/OS restoration continued, P) 12th month, OCTA disc images; radial peripapillary capillary cross-section (B-scan) and En face images.

[Abstract:0374]

Microperimetric findings could explain subjective visual complaints in patients, whose vision improved to 20/20 (logMAR 0) after macular hole surgery

Fevzi Sentürk, Cengiz Aras, Mahmut Doğramacı, Fatma Feyza Nur Keskin Perk

Department of Ophthalmology, Medipol University, Istanbul, Türkiye

Purpose: To report the results of microperimetric changes in patients with a visual acuity of 20/20 (logMAR 0) after macular hole surgery, albeit with persistent subjective visual complaint

Methods: Microperimetric changes of 3 patients whose vision improved to 20/20 (logMAR 0) one year after macular hole surgery were evaluated. Three eyes of 3 patients with stage 4 idiopathic macular holes of less than 6 months duration underwent vitrectomy with ILM peeling. Macular sensitivity, fixation stability and location were determined using microperimetry. Anatomic success was evaluated with optical coherence tomography.

Results: Best corrected visual acuity was 20/20 (logMAR 0) in 3 of 3 eyes. All eyes had central and stable fixation and a central relative scotoma. Anatomic success was achieved in all eyes.

Conclusion: Relative scotomas could be observed using microperimetry in patients after macular hole surgery, even if their final visual acuity improves to 20/20. Central scotoma could explain the ongoing subjective complaints in this cohort of patients with very good post operative final visual acuity.

Keywords: macular hole, vitrectomy, microperimetry

[Abstract:0377]**Clinical and Demographic Characteristics of Treatment Requiring Retinopathy of Prematurity (ROP) in Big Premature Infants in Turkey – BIG-ROP STUDY Report No:1**

Huseyin Baran Ozdemir¹, Sengul Ozdek¹, Zuhul Ozen Tunay², Sadik Etka Bayramoglu³, Emine Alyamac Sukgen⁴, Nur Kir⁵, Esin Koc⁶, Big Rop Study Group⁷

¹Department of Ophthalmology, Gazi University Faculty of Medicine, Ankara, Türkiye

²Department of Ophthalmology, Ankara Şehir Hospital, Ankara, Turkey.

³Department of Ophthalmology, Kanuni Sultan Süleyman Education and Research Hospital, Istanbul, Turkey

⁴Department of Ophthalmology, Adana Şehir Hospital, Adana, Turkey

⁵Department of Ophthalmology, Istanbul University Istanbul Faculty of Medicine, Istanbul, Turkey

⁶Department of Neonatology, Gazi University School of Medicine, Ankara, Turkey

⁷BIG-ROP Study group

Purpose: To analyze the clinical and demographic features of infants with gestational age (GA) of 32-37 weeks (wk) and birth weight (BW) of >1500 g who developed treatment-requiring retinopathy of prematurity (ROP).

Methods: Retrospective, descriptive, multicenter study was conducted by the Turkish Ophthalmological Association ROP commission. Data on the infants with a GA of 32-37 wk and BW >1500 g who developed treatment-requiring ROP (TR-ROP) were collected from the 33 ROP centers in Türkiye. GA, BW, type of hospital, neonatal intensive care units (NICU) level, presence of an ophthalmologist and neonatologist in the same hospital, length of stay in NICU, duration of oxygen therapy, comorbidities, type of ROP and timing for TR-ROP development were analyzed.

Results: 366 infants were included in the study. The mean GA and BW were 33±1 wk and 1896±316g, respectively. Duration of hospitalization was 3-4 wk in 46.8% of them. The first ROP examination was performed at postnatal 4-5 wk in 80.3% of infants, which was significantly later in level 2 and lower NICUs and non-university clinics. ROP was detected in 90.9% of infants at the first ROP examination, especially in clinics without an ophthalmologist. In 15.3% of the infants, treatment was required in postnatal fourth week. The mean postnatal week of TR-ROP development was 6.16±2.04 wk.

Conclusion: ROP screening thresholds need to be expanded in hospitals with suboptimal NICU conditions considering the development of TR-ROP in more mature and heavier preterm infants, and the first ROP examination should be no later than postnatal fourth week.

Keywords: Neonatal care, retinopathy of prematurity, ROP screening

[Abstract:0379]**Do We Need to Screen Very Big Babies for Retinopathy of Prematurity?**

Ayşe İpek Akyüz Ünsal¹, Duygu Güler¹, Kadir Aksoy¹, Meriç Yıldız¹, Imran Kurt Ömürlü², Abdullah Barış Akcan³, Sema Dündar¹

¹Department of Ophthalmology, School of Medicine, Aydın Adnan Menderes University, Aydın, Türkiye

²Department of Biostatistics, School of Medicine, Aydın Adnan Menderes University, Aydın, Türkiye

³Department of Neonatology, School of Medicine, Aydın Adnan Menderes University, Aydın, Türkiye

Purpose: To present the demographic and clinical characteristics of babies born above 36 weeks of gestation evaluated for retinopathy of prematurity.

Methods: This is a cross-sectional, comparative, retrospective preliminary study that included infants screened for ROP between 2017 and 2023. Group 1 (ROP) was the infants with ROP, Group 2 (NO-ROP) was the control group. Gestational age, birth weight, gender, comorbidities of infants and mothers, assisted reproductive techniques, mode of delivery, breast milk intake, hospital type, length of stay in the neonatal intensive care unit (NICU), and oxygen therapy duration were analyzed and compared between these groups.

Results: A total of 3031 infants referred to a tertiary ROP clinic were retrospectively screened. There were 333 babies born above 36 weeks of gestation, and 9.6% of them had stage 1 ROP findings (Group 1:32). None of them needed treatment. The mean birth weight of Group 1 (2717.81±650.94 grams) was lower than Group 2 (2978.78 ±560.55 grams). The duration of stay in the neonatal intensive care unit was longer in Group 1 (12.94±13.71 days) than in Group 2 (7.59±7.76 days). There was no statistically significant difference between the groups, except for birth weight and length of stay in the neonatal intensive care unit (p=0.022, p=0.031).

Conclusion: Although pediatricians know that babies with a gestational age above 36 weeks do not have the risk of treatment requiring ROP; they continue to refer babies to screening for ROP, possibly out of concern for malpractice issues. The results of this preliminary study suggest that the main cause of ROP is prolonged NICU stay in very large infants. ROP screening may be limited by the prolonged NICU time in these very large infants.

Keywords: Retinopathy of prematurity, very big baby, screening

[Abstract:0389]

Peripapillary and Macular Choroidal Vascularity Index in Migraine Patients During Acute AttacksDilara Özkoyuncu Kocabaş¹, Kemal Özülken¹,Aslıhan Taşkıran Sağ²¹Ophthalmology, TOBB Economics and Technology University Faculty of Medicine, Ankara, Turkey²Neurology, TOBB Economics and Technology University Faculty of Medicine, Ankara, Turkey

Purpose: To evaluate the choroidal vascularity alterations of macula and peripapillary area in migraine patients during acute migraine attacks and compare with control group participants.

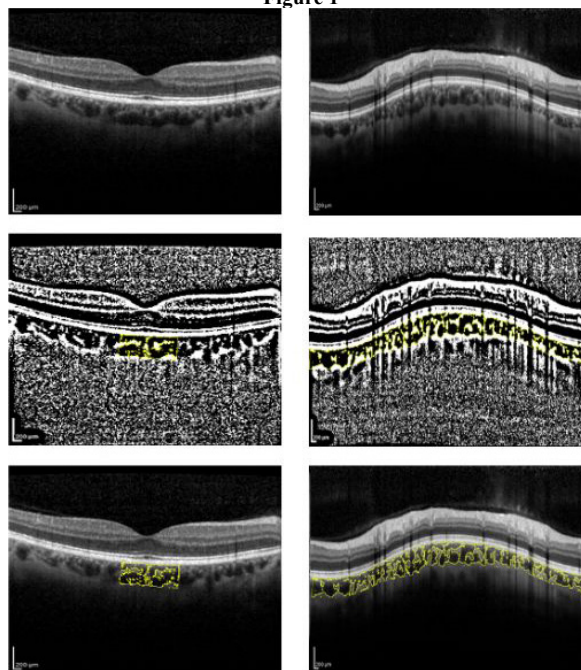
Methods: A total of 28 patients diagnosed with migraine (24 female and 4 male) and 28 age matched-healthy controls (21 female and 7 male) were included in this cross-sectional study. Enhanced depth imaging optical coherence tomography scans of the macula and peripapillary regions were analyzed. Images were binarized using ImageJ software (National Institutes of Health, Bethesda, MD, USA) (Figure 1). The choroidal thickness (CT), total choroidal area (TCA), luminal area (LA), stromal area (SA), and the choroidal vascularity index (CVI) were compared between the groups.

Results: The subfoveal and 750 microns nasal (N750) and temporal (T750) to the fovea CT were increased in migraine patients ($P=0.004$, $P<0.001$ and $P<0.001$, respectively). The mean subfoveal CVI value was 65.7 ± 6.8 in migraine patients and 63.6 ± 4.8 in healthy controls ($P=0.159$). The mean peripapillary CT at the temporal, nasal, and inferior regions were increased in migraine group ($P=0.010$, $P<0.001$ and $P<0.001$, respectively). The mean CVI values of temporal and nasal quadrant in the peripapillary region were significantly increased in the migraine group as compared with the control group ($P=0.005$ and $P<0.001$, respectively). The increase TCA and LA in both fovea and peripapillary regions were statistically significant in migraine group compared to healthy controls ($P<0.05$ for all). Both groups had similar measured values for other parameters ($P>0.05$ for all).

Conclusion: According to our findings, increased CT, TCA, LA and CVI values may indicate a rebound vasodilatation in the ocular blood flow, as in the vasogenic theory contributing to pain.

Keywords: Choroidal Vascularity Index, Migraine, Peripapillary Area

Figure 1



The enhanced depth optical coherence tomography (EDI-OCT) images of macular and peripapillary scans (a,b). Illustration of submacular and peripapillary choroidal vascularity index measurements using ImageJ software. The scans were binarized to determine the total choroidal area (TCA) using the autolocal threshold tool (Niblack method, 8-bit type) c, d. The yellow lines represented the luminal area (LA) (dark pixels) using the color threshold tool (e, f).

[Abstract:0390]

ROP multiple injections, when to stop?!

Sara Ahmed Tawfik

Al-Ferdaws Eye Hospital, Egypt

Purpose: ROP has majorly involved lower income countries with high rate of ROP that indicated treatment (type one). Intravitreal anti-VEGF injection has been first line of treatment in most of centers in Egypt. Although being effective and rapid treatment line, it has higher rate of recurrence than laser photocoagulation which may necessitate repeated injection.

Methods: Case report study of 2 cases with initial diagnosis of A-ROP (Aggressive retinopathy of prematurity) that has bilateral intra vitreal anti-VEGF injection as first line of treatment and went through multiple reactivation episodes.

Results: two babies with bilateral A-ROP received intra vitreal injection of anti-VEGF (ranizumab) with subsequent two reactivations bilaterally for each baby with 4-6 weeks interval inbetween. first baby had full vascularisation after third injection while second had persistent avascular retina about 4DD and went for laser photocoagulation. OCT and FFA imaging using flying baby technique were performed for both with 2 years follow up.

Conclusion: Intra vitreal injection of anti-VEGF for ROP as first line of treatment can be accompanied by high rate of reactivation that necessitate close and tight follow up. However, repeated injections can be used in order to save more peripheral retina. Systemic work up and side effects analysis should be studied although none with reported in our cases.

Keywords: ROP multiple injections

[Abstract:0392]

Experimental Laboratory Modelling of Choroidal Vasculature: a Study of the Dynamics of Intraoperative Choroidal Hemorrhage during Pars Plana Vitrectomy

Mahmut Dogramaci¹, Funda Dikkaya², Fevzi Şentürk², Cengiz Aras²

¹Princess Alexandra hospital NHS trust, Harlow, Essex, UK

²Medipol University School of Medicine, Department of Ophthalmology, Istanbul, Turkey

Purpose: Choroidal hemorrhages (CH) result from rupture of choroidal vessels leading to extravasation of blood into the suprachoroidal space. In this study, we aimed to understand the hemodynamic of CH through a purpose-built scaled model for choroidal vasculature and calculated stress levels in the model under different circumstances.

Methods: We modelled choroidal vasculature using a 10 cm long rubber tube with a cross section of 1 cm, the tube was wrapped with conductive yarn to enable the measurement of stress at the walls of the tube. Stress levels across the tube were continuously measured under different systemic intravascular blood pressure levels (IVP), intraocular pressure (IOP) levels and distortion.

Results: Stress values across choroidal vessel model correlated negatively with IOP and positively with IVP and distortion. All correlations were statistically significant ($p < 0.05$) and were stronger when the model was filled with expansible tamponade compared to non-expansible tamponades. Distortion showed the strongest correlation in terms of increasing stress across the model compared to IVP, which intern showed stronger correlation compared to IOP. Raising IOP to counteract the stress in the model was effective when the stress in the model was secondary to increased IVP, but this approach was not effective when the stress in the model was generated from distortion.

Conclusion: Excessive distortion of the eyeball during surgical maneuvers could be the primary reason for the rarely observed intra-operative CH. The use of non-expansible ocular tamponade provides better support for vascular bed against the CH and it should be the recommended choice of tamponades in patients with established CH. Increasing IOP excessively, is of limited effect in preventing CH in vessels, that are under stress as a result of distorting surgical maneuvers.

Keywords: Choroid hemorrhage, Vitrectomy

[Abstract:0414]

Relationship Between Epiretinal Membrane and Pseudoexfoliation Glaucoma

Nilgun Solmaz, Ekin Ece Oskan, Feyza Onder
Haseki Eğitim ve Araştırma Hastanesi, Göz Hastalıkları Anabilim Dalı, Istanbul

Objective: To determine the incidence of epiretinal membrane (ERM) in patients with asymmetrical pseudoexfoliation glaucoma (PXG) and to investigate the effect of ERM on glaucoma follow-up parameters.

Method: 98 eyes of 49 asymmetrical PXG patients with clinically detected pseudoexfoliation in only one eye and 100 eyes of 50 randomly selected age-matched patients with primary open angle glaucoma (POAG) were included in the study. Optical coherence tomography angiography (OCTA) imaging was performed in all cases. The presence of ERM was investigated by raster scanning. Age, PEX, hypertension, diabetes, history of intraocular surgery, peripapillary retinal nerve fiber layer (pRNFL) and vascular density (VD) parameters were investigated as predictor factors on ERM formation.

Results: The mean age of the PXG and POAG groups was 65.8 ± 6.1 and 65.79 ± 6.8 respectively ($p = 0.988$). There was no difference between PXG and POAG groups in terms of pRNFL, ganglion cell complex (GCC), peripapillary and macular VD (ppVD and mVD) parameters (all $p > 0.05$). All parameters were significantly better in fellow eyes of PXG cases (all $p < 0.001$). In PXG group, ERM was detected in 12 eyes (24.5%) with pseudoexfoliation and 4 fellow eyes (8.2%), 2 being bilateral. In POAG group, 6 eyes of 5 patients (6%) had ERM. The frequency of ERM in eyes with PXG was significantly higher than both fellow eyes and eyes with POAG ($p = 0.039$ and $p = 0.001$ respectively). Logistic regression analysis showed that PXG increases the risk of ERM approximately 5-fold ($p = 0.002$) but other factors were found to be non-significant. In both PXG and POAG, presence of ERM caused a significant deterioration in visual field mean deviation (MD) and ppVD compared to eyes with no ERM ($p = 0.004$ and 0.013 respectively) whereas no significant difference was detected by means of pRNFL, GCC and mVD.

Discussion: PXG is an important risk factor for ERM formation. The presence of ERM causes significant deterioration in MD. In order to better interpret the changes in visual field parameters, patients with PXG should be followed up with detailed macular imaging.

Keywords: pseudoexfoliation glaucoma, epiretinal membrane, optical coherence tomography angiography

[Abstract:0425]**Rop Screening & Imaging modalities...our way**Ahmed Mansour¹, Sara Tawfik², Ahmed Habib¹¹Ophthalmology department, Ain Shams University, Cairo, Egypt²Ophthalmology department, Ferdaws Eye hospital, Zagazig, Egypt

This presentation will show the ROP Screening from A-Z Starting with demographics and screening programs endings with paper that has been published of 200+ pts through 2 years... Setting our own criteria of screening, in same presentation will show the new imaging technique we use for ROP

Keywords: ROP, screening, imaging

[Abstract:0432]**Coats disease: The whole spectrum**Ihab Saad Othman¹, Ihab Saad Othman²¹Faculty of Medicine, Cairo University, Cairo, Egypt²EyeWorld Hospital, Giza, Egypt

Introduction: Coats disease presents in childhood with a whole spectrum from retinal vascular telangiectasia to a blind painful eye.

Materials-Methods: A retrospective evaluation of 89 cases of Coats disease presented at EyeWorld hospital and ophthalmology department at Cairo University and the National Eye center.

Results: Age ranged from 4 months to 19 years. There were 60 males and 29 females. All cases were unilateral. Thirty cases presented with retinal telangiectasia on a flat retina with or without macular exudates/nodules and were managed with laser peripheral ablation to the ischemic retina. 40 cases were managed by transcleral drainage of lipid exudates and intravitreal injection of triamcinolone 2mg in 0.2 ml then laser peripheral ablation. Six cases were enucleated because of a blind painful eye or uncertainty in diagnosis and none revealed retinoblastoma. Thirteen cases presented with vitreous hemorrhage associated with a tractional retinal detachment. These were managed with pars plana vitrectomy, releasing of the tractional membranes and endorser. Three cases needed silicone oil tamponade as an accidental break was associated with the surgery. Retinal stability could be achieved in ten out of thirteen uncomplicated cases. Retreatment with laser, cry to active telangiectasia and or anti-VEGF injection was necessary in 30 cases on follow up of 102 months.

Conclusion: Coats disease presents with wide clinical presentations. Management is on-going and necessitates long term follow up to conserve the eye. Vitrectomy associated with retinal break formation ends up by recurrent retinal detachment and eye loss.

Keywords: Coats disease spectrum

[Abstract:0439]**Ocular Oncology for Retina Specialists**Murat Hasanreisoglu¹, Tuba Atalay², Marco Pellegrini³, Martina Angi⁴¹Koç University, School of Medicine, Ophthalmology Department²Gazi University, School of Medicine, Ophthalmology Department³University of Milan, Department of Biomedical and Clinical Sciences⁴University of Liverpool, Department of Molecular and Clinical Cancer Medicine

Ocular oncology is the ophthalmic subspecialty that diagnoses and treats malignant and benign ocular tumors, including tumors of the retina, the optic nerve, and the uveal tract. Retina specialists frequently encounter cases that require referral to ocular oncologists to confirm the diagnosis. Even if benign, these cases may also be followed by retina specialists for the possibility of malignant transformation and because of other possible vision threatening complications. Proposed course aims to provide a comprehensive ocular oncology update particularly for retina specialists. The course will focus on, up-to-date, diagnosis and management of major intraocular tumors such as choroidal melanoma, retinoblastoma, metastatic, vascular tumors, and their masqueraders with special focus on multimodal imaging findings.

Keywords: Ocular oncology, retina

[Abstract:0440]**Vitrectomy for complications of proliferative diabetic retinopathy**Hassan Ali Mortada

Faculty of medicine, department of ophthalmology, Cairo university

Using high quality surgical videos (4K), this didactic course is intended to describe the management of complications associated with proliferative diabetic retinopathy including: traction, combined traction / rhegmatogenous RD & fibrovascular tissue covering the posterior pole.

This course will also deal surgical management of tractional diabetic macular edema

Keywords: PDR, traction DME

[Abstract:0441]**Optometrist based screening for retinopathy of prematurity - a validation study using portable wide-field paediatric imaging system**Vishal Govindahari¹, Bala Vidyadhar¹, Gvs Murthy², Rajan Shukla²¹Pushpagiri Vitreo Retina Institute, Hyderabad, India²Indian Institute of Public Health, Hyderabad, India

The study aimed to validate screening for Retinopathy of Prematurity (ROP) at the community level by optometrists using a mydriatic portable wide-field imaging system (Neocam, Forus, India). The optometrists underwent intensive

imaging training following which hand-holding and image validation were performed by a trained ophthalmologist in a staggered fashion to ensure safety. The imaging was performed at special new born care units (SNCUs) in three districts of Telangana, South India. Each eye had six images captured which included superior, inferior, nasal and temporal periphery along with central images at the disc and macula. Hence each baby had a total of 12 images in both eyes.

Validation performed included number of zones totally imaged in each baby (max 12), gradability of images captured and the inter-observer agreeability between the optometrist and trained ophthalmologist's ROP grading.

A total of 234 babies were screened by the optometrist over a period of three months. In 203 (86.75%) babies, 10 or more zones were successfully imaged by the optometrist. Out of the 3141 images captured by the optometrist, 3122 (99.4%) images were deemed gradable by the trained Ophthalmologist. The overall measure of agreement (Kappa statistic) was 0.931 which showed high inter-observer reliability between the imaging optometrist and ophthalmologist.

This pilot study attempted to democratise the process of screening for ROP and making it less ophthalmologist and institution dependent while ensuring safe and ethical screening. Difficulties faced by the optometrists included difficulty in handling small babies and media haze in sick babies. The results were encouraging with regards to the efficacy of optometrist based screening and would serve as baseline data towards the development of a hub-spoke model with optometrist/ para-medical personal screening in the community using portable cameras and a base hospital serving as a hub for hand-holding, examination and management of referred babies.

Keywords: Retinopathy of Prematurity, Wide-field Imaging, Non-ophthalmologist screening

[Abstract:0442]

The effect of retinopathy of prematurity on corneal topography and corneal endothelial function parameters

Sibel Yavuz, Mehmet Fatih Küçük, Muhammed Kazım Erol
Antalya Eğitim ve Araştırma Hastanesi

Purpose: The pathological development of vascular tissues in eyes that have undergone retinopathy of prematurity (Rop) leads to various degrees of anatomical and functional changes. Our aim is to observe the effects of Rop on the cornea.

Methods: February 2013- February 2023 between the dates which have been followed by ROP cases, corneal specular microscopy and corneal topography measurements taken between the ages of 5-9 years were retrospectively examined. ROP stages and spherical equivalent values were saved. Central corneal thickness (CCT), keratometry (K), endothelial cell density (CD), hexagonality (CV), pleomorphism parameters

were evaluated by taking corneal topography and corneal specular microscopy measurements of the patients. It was compared with the parameters of the control group consisting of healthy children in the same age group.

Results: Eighty-four eyes of 42 patients with ROP were included in the study group and 80 eyes of 40 healthy children were included in the control group. The age of the cases was between 5 and 9 years in both groups. While the mean central corneal thickness (CCT) measurements in the study group were 527 µm and the mean keratometry measurements were 44.87, they were 544 µm and 43.11 in the control group, respectively.

Conclusion: CCT measurements of the cases in the study group were statistically significantly lower compared to the control group ($p = 0.019$; $p < 0.05$). The mean K values of the cases in the study group were statistically significantly higher compared to the control group ($p = 0.001$; $p < 0.01$). There was no statistically significant difference between the two groups in CD, CV and pleomorphism parameters. Although there is no difference in corneal endothelial cell function parameters in cases developing rop, increased keratometry parameters may play a role in the tendency to myopic refraction.

Keywords: retinopathy of prematurity, cornea

[Abstract:0451]

Principle, pitfalls and artifacts in Optical Coherence Tomography (OCT) and Optical Coherence Tomography Angiography (OCTA)

Ali Erginay

Ophthalmology Department, Lariboisiere Hospital, APHP, Paris University

OCT/OCTA is a novel noninvasive imaging technique that enables high-speed, high-resolution imaging of the retinal and choroidal structures. Unfortunately, the images obtained are not always perfect and there can be extra or missing pieces of information (artifacts) leading to misinterpretation and diagnosis errors. The aim of this course is to explain the principles of OCT/OCTA and to provide a framework for young ophthalmologists to understand, recognize and avoid artifacts to reduce risk of misinterpretation.

Keywords: OCT, OCTA, artifact

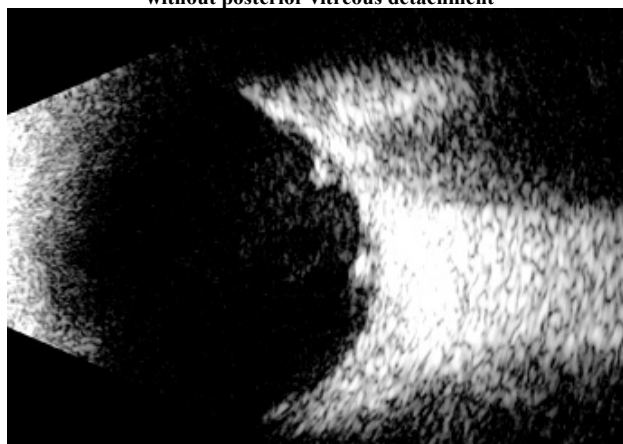
[Abstract:0454]**Changes in the density of the vitreous body in patients with diabetic vitreopapillary traction syndrome**

Dilara Babaeva, Mikhail Shishkin, Rinat Fayzrakhmanov, Ibragim Akhtaev

Federal State Budgetary Institution "National Medical and Surgical Center named after N.I. Pirogov", Ophthalmology Department, Moscow, Russia

The article presents the results of observation of 70 patients with diabetic vitreopapillary traction syndrome. The preoperative examination consisted of standard ophthalmological examinations, as well as ultrasonic kinetic B-scanning, microperimetry, fluorescein angiography and in the presence of transparent optical media, optical coherence tomography was performed. The results of our own research indicate that one of the main links in the pathogenesis of vitreopapillary traction syndrome is pathological changes in the vitreous body, namely biomechanics and an increase in the density of the vitreous body. Results of our own observations indicate that the development of pathological changes in proliferative diabetic vitreoretinopathy is due not only to the action of systemic metabolic disorders and retinal ischemia, but also to the influence of the vitreous body undergoing changes, including due to an increase in its density. B-scanning of the vitreous body in the kinetic mode allowed us to note not only the presence of partial posterior vitreous detachment, but also to qualitatively register in real time the change in the mobility of the vitreous body. The increasing rigidity of its structures was registered by us in dynamics in half of the patients who were under our supervision. According to fluorescein angiography after surgery, a decrease in pathological leakage was recorded at the sites of vitreoretinal fixation, which proves the restoration of the hematoophthalmic barrier after removal of tractions. The initial manifestations of proliferative diabetic retinopathy can develop without obvious clinical manifestations of posterior vitreous detachment and can be detected only according to optical coherence tomography and kinetic B-scan over time. Timely diagnosis of vitreopapillary traction syndrome, early vitreoretinal surgery can prevent biomechanical damage to the papillomacular bundle, traction displacement of retinal areas adjacent to the optic nerve and stop the progression of the proliferative process.

Keywords: vitreopapillary traction syndrome, density of vitreous, diabetic retinopathy

Ultrasound scan patient with vitreopapillary traction syndrome without posterior vitreous detachment**[Abstract:0458]****Surgery in Uveitis and Endophthalmitis**

Ahmed Sallam¹, Mohamed Moghazy², Mahmoud Soliman³

¹University of Arkansas for Medical Sciences, Little Rock, USA

²Ain Shams University, Cairo, Egypt

³Cairo University, Cairo, Egypt

A practical video-based course focusing on surgery in uveitis and endophthalmitis, including:

- Diagnostic use of vitrectomy in uveitis
- Therapeutic indications of vitrectomy in uveitis
- Pars plana vitrectomy in the management of uveitis complications
- Role of vitrectomy in endophthalmitis treatment

Keywords: uveitis; endophthalmitis; vitrectomy

[Abstract:0464]**Comparison of aflibercept and bevacizumab analyzing central macular thickness on optical coherent tomography and best corrected visual acuity in patients with diabetic macular edema**

Emina Kujundzic Begovic, Amila Alikadic Husovic

Ese clinic Clinical center University of Sarajevo

Introduction: Diabetic macular edema (DME) is the most common cause of vision loss in patients with diabetic retinopathy (DR). Intravitreal injection of anti-vascular endothelial growth factor (VEGF) agents blocks vascular endothelial growth factor in forming of new vessels of retina and bleeding, slowing progression of a disease and improves visual acuity.

Purpose: We compared effect of two types of anti-VEGF injection: aflibercept and bevacizumab, and their impact on diabetic macular edema.

Material-Methods: Based on the inclusion criteria we included 100 patients in our study group. During the study period, 8 patients from the group aflibercept got lost during the follow up, and 4 patients from the bevacizumab group withdrawn from the study. Finally, we analyzed data from 88 patients: 42 patients who received aflibercept, and 46 patients who received bevacizumab. We compared central macular thickness (CMT) on optical coherence tomography (OCT) and best corrected visual acuity (BCVA) before and after three months of treatment.

Results: The use of aflibercept after three months of treatment showed a statistically significant improvement of BCVA ($p<0.0001$, $p<0.009$) and CMT on OCT. No statistical difference was noticed after the three months treatment with bevacizumab on BCVA ($p<0.179$, $p<0.859$) and CMT on OCT ($p<0.122$, $p<0.523$).

Conclusion: We consider that this research will help in choosing an effective anti-VEGF agent in treatment of diabetic macular edema.

Keywords: Aflibercept, bevacizumab, optical coherence tomography

[Abstract:0476]

Combined ocular signs leading to a diagnosis of rare systemic disease: Bilateral Angioid Streaks with Optic Nerve Head Drusen and abnormal retinal haemorrhage in a case of Pseudoxanthoma Elasticum (PXE)

Mahjabeen Choudhury¹, Mostafizur Rahman¹, Mohammad Malek¹, Harun Or Rashid²

¹Ispahani Islamia Eye Institute and Hospital

²Dhaka Medical College and Hospital

To report a rare case of retinal haemorrhage with bilateral angioid streaks with optic nerve head drusen in a Bangladeshi woman who later was diagnosed as a case of Pseudoxanthoma Elasticum or Grönblad- Strandberg syndrome. The retinal haemorrhage was confirmed not to be a CNV and was only closely monitored. The patient was found to be myopic with early nuclear sclerosis and was treated with myopic correction. But due to progressive retinal changes, her BCVA were 20/30 in both eyes. The haemorrhage later resolved spontaneously and the patient was advised for long-term follow-up both under a retina and medicine specialist.

Method: A 60 years old Bangladeshi woman presented with a gradual loss of visual acuity in both eyes for the last 2 years. On examination, her BCVA in both eyes were 20/30 with -1.00 DSP correction for distance with +2.50 DSP for near with nuclear sclerosis (+), and IOP was 12 mm of mercury. Bilateral fundus examination revealed grey streaks radiating from optic nerve heads (ONH) in an irregular ring pattern, mottled peau d' orange fundus, ONH look raised, and patches of retinal haemorrhage in right eye temporal to macula not threatening VA. Our diagnosis was Bilateral Angioid Streaks

with Optic Nerve Head Drusen with retinal haemorrhage in the right eye (secondary to degeneration of elastic tissue of retinal arterioles). The diagnosis was confirmed with CFP, FFA, OCT, and B-scan of both eyes. On physical examination, there were small yellow papules, 1-5 mm in a linear pattern on the lateral part of the neck resembling Pseudoxanthoma Elasticum (PXE). The microscopic histopathology of the skin tag of the neck was confirmed as PXE. All relevant systemic examinations were normal. Her retinal haemorrhage resolved completely within one month. She was advised to be cautious about strenuous physical exercise and NSAIDs.

Keywords: PXE, ONH drusen, Angioid streaks

[Abstract:0483]

Gonioscopic and anterior segment optical coherence tomographic findings after low viscosity silicon oil removal

Çiğdem Bengi Güngör, Yasemin Ün, Yücel Öztürk, Nursal Melda Yenerel

University of Health Sciences, Haydarpaşa Numune Training and Research Hospital

Purpose: To analyze the gonioscopic and anterior-segment OCT (AS-OCT) findings of patients who underwent uneventful PPV surgeries and silicon oil (SO) removal after a healing period to determine if AS-OCT scans can detect the SO seen in gonioscopy.

Methods: All patients included in the study were scheduled for gonioscopic examination and AS-OCT imaging at postoperative second-month control visit. All gonioscopic procedures were held by the same glaucoma specialist and the presence of emulsified SO droplets in the angle was graded from 0-4 at 4 quadrants. (0:No SO at trabecular meshwork (TM), 1:Few SO droplets at TM, 2:Grouped SO allowing TM visualization, 3:SO not allowing TM visualization, 4:Reverse hypopyon). AS-OCT scans were taken by another blinded ophthalmologist to investigate the iridotrabecular angle and any sign of SO presence was noted.

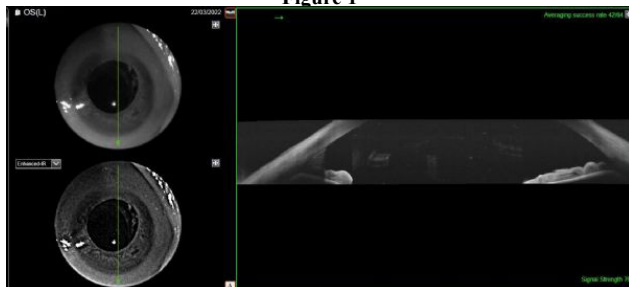
Results: 18 eyes of 18 patients who underwent PPV for retinal detachment were included in the study. At least grade 1 SO particles were detected by gonioscopy in 16/18(88.8%) patients. Gonioscopic findings at the superior angle were as follows: 1/18(5.5%) were grade 1; 6/18(33.3%) were grade 2; 8/18(44.4%) were grade 3; and 1/18(5.5%) were grade 4. No SO was detected in 2 eyes(11.1%). AS-OCT scans detected hyper-reflection at the superior angle in 14(77.7%) eyes. 2 eyes that SO was detected gonioscopically were negative in AS-OCT (11.1%)($p<0.05$). The eyes that were gonioscopically negative for SO were also negative in AS-OCT. Gonioscopy for SO at nasal and temporal quadrants was positive in 4 (22.2%) eyes whereas none were positive in AS-OCT.

Conclusion: After low-viscosity SO removal, SO droplets were detected at the superior angle in 88.8% of eyes on gonioscopy. AS-OCT detected SO particles in 77.7% of

eyes. Despite AS-OCT being an important imaging tool for an ophthalmologist, the gonioscopic examination is the better choice to investigate the TM to detect SO particles.

Keywords: silicon oil, anterior segment optical coherence tomography, gonioscopy

Figure 1



AS-OCT image of a patient after uneventful SO removal showing hyper-reflective substance in the superior quadrant of iridocorneal angle.

[Abstract:0491]

Vascular Occlusion in young patients

Kshitij Raizada

Dr. Raizada Eye Centre, Bareilly, India

Retinal Vascular Occlusions are some of the most commonly seen causes of Acute Painless Diminution of Vision. Vascular Occlusions are usually seen in the 5th & 6th decade onwards, with Diabetes Mellitus, Hypertension, Hypercholesterolemia being the most common culprits. But of late, we have been witnessing a surge in the number of cases of Retinal Vascular Occlusions in young patients (3rd & 4th decades). The surge is notably seen ever since the incidence of COVID Pandemic.

Vascular Occlusions are detrimental to the lifestyle of patients, especially in the younger age group. Such cases need to be thoroughly scrutinised so as to pick up the causative factor at the earliest, thereby preventing further incidences in the same eye as well as the other eye, or any other part of the body.

With this presentation, we intend to discuss this newly developing scenario, throwing light on the possible causative factors, pathogenesis, clinical features, diagnosis and treatment of Vascular Occlusion in young patients.

Keywords: Vascular Occlusion, Painless loss of vision, young patients

[Abstract:0500]

The epidemiology of open globe injuries: A ten-year retrospective analysis at a tertiary care center in Istanbul, Turkey

Merve Beyza Yıldız¹, Ece Turan Vural¹, Nursal Melda Yenerel¹, Nadir Koçkar¹, Yücel Öztürk²

¹Haydarpaşa Numune Training and Research Hospital, Department of Ophthalmology, Istanbul

²Altunizade Dünyagöz Hospital, Department of Ophthalmology, Istanbul

Purpose: The aim of our study was to review the epidemiology of open globe injuries (OGI) presenting to a tertiary referral eye hospital in Istanbul.

Methods: The medical records of patients diagnosed as OGI between 2013 and 2023 were reviewed retrospectively and 212 of the 255 patients were included in the study. The Birmingham Eye Trauma Terminology (BETT) system was used to classify injuries as globe ruptures, penetrating eye injuries (PEIs), intraocular foreign bodies (IOFBs) or perforating injuries. Demographic data, mechanism of trauma, wound location, ophthalmic presentations, and managements were recorded.

Results: The mean age of the patients was 39 ± 22 years (range, 1-95). Fifty four of them were female and 158 were male. The 212 OGIs included 55 globe ruptures, 116 PEIs, 36 IOFBs and five perforating injuries. Wound localization was ranged in order; corneal injuries (47.2%), scleral (30.7%) and corneascleral injuries (22.2%). PEIs were mostly caused by sharp objects (41.4% metal objects and 12.9% broken glass). IOFBs were mostly caused by high-velocity metallic objects (66.7%). Workplace accidents in young adults were the most common cause of injury for PEIs and IOFBs. The most frequent mechanism of injury for globe rupture was a fall (41.8%). Patients with a globe rupture were older than the other BETT classification groups. Rupture occurred at the corneal donor-host interface in 12 patients who underwent penetrating keratoplasty. Perforating injuries were mostly caused by firearm (80%). Fifty-two eyes (25.5%) required pars plana vitrectomy. Four eyes (1.9%) underwent enucleation/visceralization.

Conclusion: The most common causes of OGIs were workplace accidents in young adults and falls in elderly patients. The epidemiological factors in OGIs are important for effective protective measures. The most important step is to increase protective measures to avoid OGIs.

Keywords: Open globe injury, Epidemiology, Ocular trauma

[Abstract:0516]**How to Avoid and Manage PVR?**

Nur Acar Gocgil¹, Gökhan Gureli², Mahmoud Soliman³, Özgür Artunay⁴

¹Nur ACAR GOCGİL, Prof, FEBO, Neoretina Eye Clinic, Istanbul, Turkey

²Gökhan GURELİK, Prof, Gazi University, School of Medicine, Department of Ophthalmology, Ankara, Turkey

³Mahmoud SOLIMAN, Prof, Cairo University, School of Medicine, Department of Ophthalmology, Cairo, Egypt

⁴Özgür ARTUNAY, Prof, Beyoğlu Eye Training and Research Hospital, Istanbul, Turkey

PVR is still a major complication of retinal detachment surgery, and the most common reason for a reoperation.

In this course important steps in vitreoretinal surgery to minimise its development as well as surgical approaches and techniques to deal with PVR when it is already formed will be discussed regarding clinical cases, and updated literature.

Additionally new pharmacotherapies and techniques to prevent PVR formation will be discussed.

A time for discussion is planned at the end of the session.

Keywords: proliferative vitreoretinopathy, retinal detachment, surgery

[Abstract:0523]**Lamellar macular holes: Which ones to touch**

Hany Hamza

Kasr alainy School of Medicine Cairo University

Vitreoretinal surgeons have long grappled with the challenge of predicting visual outcomes following vitrectomy for lamellar macular holes (LMH). This particular pathology encompasses two distinct subtypes, namely tractional and degenerative LMH. It is the latter that presents with a distinct feature, namely, lamellar hole epiretinal proliferation.

Given the clinical significance of LMH, this topic has garnered considerable attention from the medical community. As such, we aim to provide insights into the critical factors that determine the success of vitrectomy for LMH. In particular, we will explore the predictive value of distinguishing between the two subtypes of LMH when it comes to visual outcomes.

Keywords: Lamellar, macular, holes

[Abstract:0542]**Examining the Correlation of Lymphangiogenesis Biomarkers with Clinical Condition in Age-Related Macular Degeneration (AMD)**

Bağım Ayçin Çakır Ince, Murat Küçükevcilioğlu, Ali Hakan Durukan

Department of Ophthalmology, Gülhane Faculty of Medicine, Ankara, Turkey

Purpose: Lymphatics contribute to ocular homeostasis and that ocular lymphangiogenesis may influence eye disorders. Also, AMD is associated with inflammatory reactions resulted from the etiopathogenesis of the disease and the biochemical structure of drusen. The objective of this study is to evaluate the relationship between AMD and lymphangiogenesis; by quantitatively analyzing the biomarkers of lymphangiogenesis in serum, vitreous and aqueous eye fluids of patients with and without AMD; and to emphasize the relationship of these markers with the pathogenesis of the disease in AMD.

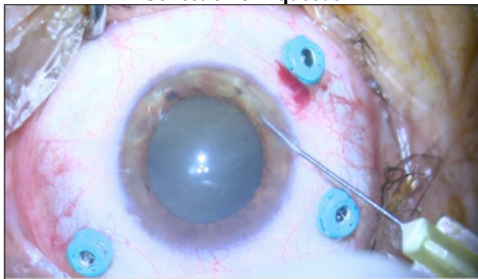
Participants: Patient group: 11 patients with subretinal hemorrhage (neovascular AMD) and cataract; 19 patients with dry AMD and ERM, macular hole, retinal detachment and cataract (30 in total which all going to have the vitreoretinal and phacoemulsification surgery). Control group: 27 patients without AMD who will undergo same surgery due to same retinal pathology and cataract.

Methods: The prospective, clinical trial of patients with neovascular AMD who were naive or had not received anti-VEGF for ≥ 6 months is conducted. Patients with systemic and autoimmune diseases, uveitis, degenerative myopia, glaucoma, globe injury are excluded. Lymphangiogenesis biomarkers (LYVE-1, Podoplanin, VEGF-C, VEGFR-2, VEGFR-3) are measured in the serum, vitreous and aqueous of the patients.


Results: LYVE-1 and PDPLN were shown to be present in the vitreous of patients with n-AMD and their values were lower than the control group. Therefore, we consider that the weakening of lymphangiogenesis in n-AMD patients may alter the pathophysiology of the disease. In our study, vitreous VEGF-C values are statistically significantly higher, especially in n-AMD. Yet the increase in levels of VEGF-C-binding receptors (VEGFR-2, VEGFR-3) were not high enough to compensate VEGF-C. The lack of an increase in VEGFR-3 in AMD patients, which is especially necessary for lymphangiogenesis, also suggests that lymphangiogenesis production is suppressed or cannot be performed. It seems possible that VEGF-C overexpression, especially in the vitreous of n-AMD patients, affects ocular angiogenesis alongside VEGF-A.

Keywords: AMD, Lymphangiogenesis, VEGF-C

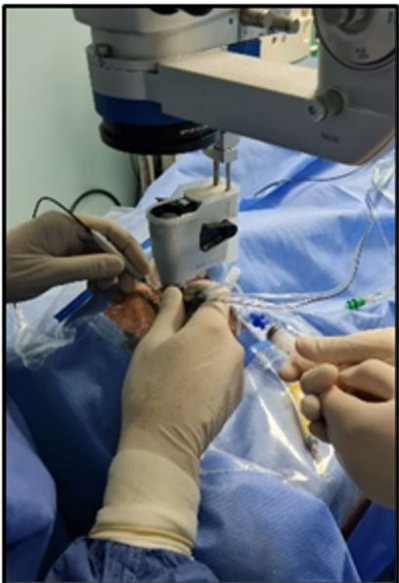Collection of Aqueous



Collection of samples in eppendorf tubes



Collection of Vitreous



VIDEO PRESENTATIONS

[Abstract:0097]**Surprise: Not Just the Vitreous Hemorrhage!**Mustafa Doğan, Mehmet Cem SabanerAfyonkarahisar Health Sciences University, Faculty of Medicine,
Department of Ophthalmology, Turkey

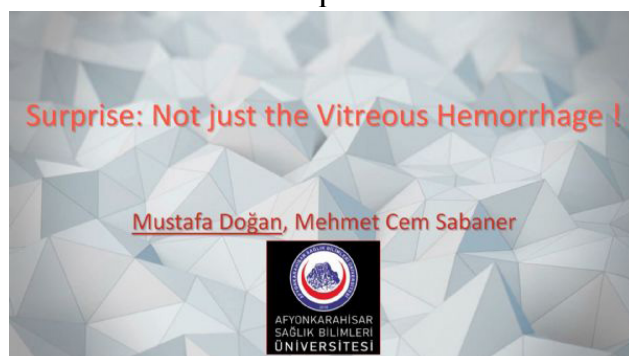Combined cataract and vitreoretinal surgery procedure was planned in a 65-year-old PDR patient who was admitted to our retina clinic with vitreous hemorrhage (VH).

In surgical procedure, when the macula was visualized after clearing the hemorrhage, a surprised full-thickness macular hole was appeared, which was often unexpected in PDR patients. Therefore additional macular hole procedure was performed successfully.

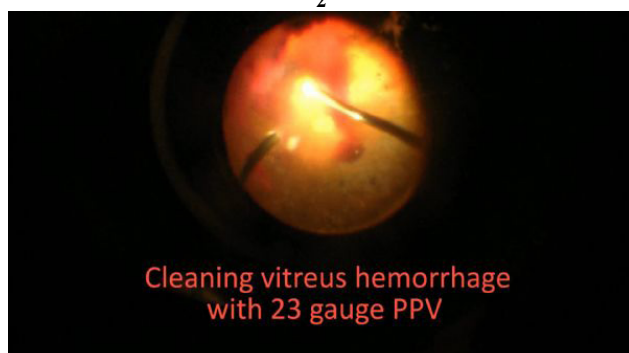Conclusion: In vitreoretinal surgery, it is almost always necessary to be prepared for surprises, and this is perhaps the exciting part of the job.

Keywords: surprise, PDR, vitreous hemorrhage


1



2



3

**[Abstract:0123]****Dialysis of The 300 Degree Zonule In A Vitrectomized Eye**Yasin Sakir Goker

Goker Eye and Retina Center, Ankara, Turkey

Purpose: To present the dialysis of the 300 degree zonule in a vitrectomized eye, which develops as a result of the air entering the tubing system in the i/a stage.

Case: A phacoemulsification was started for a cataract that developed in a patient who underwent vitrectomy 1 year ago for a macular hole. Everything was going well until the i/a stage. After phacoemulsification of the cataract the handpiece was switched to i/a. Unfortunately the foot pedal was not pressed outside the eye firstly. When the i/a started, dialysis of the 300 degree zonule occurred as a result of the air entering to the eye with pressure from the tubing system. The video was started from this point. Conjunctiva was opened superiorly and inferiorly. A type 2-L cionni ring was prepared to stabilize the capsular bag. A 10-0 looped polypropylene suture was used for both sides of the cionni ring and fixated outside the eye. Then the suture tip was entered the eye from temporal corneal incision (main incision) and exited from the sclera above the anterior capsule and 1.5 mm away from the limbus both inferiorly and superiorly. Ring was inserted to eye but the curvature of the anterior curvilinear capsulorhexis was disorganized. Cortex was totally aspirated by the support of the cionni ring. While manipulation of the cionni ring for fixation, the ring was escaped from the bag. Ring was explanted from the eye and re-implanted to the bag and escaped again. Cionni ring was explanted second time and a 12 mm capsular tension ring was implanted in the bag for equatorial support and cionni ring was implanted over it. Scleral Z suture technique was used for the fixation of cionni. An IOL was implanted in the bag and the case was finished after removal of the OVD.

Keywords: Cionni ring, vitrectomized eye, zonule dialysis

[Abstract:0124]**25 G Sutureless Pars Plana Vitrectomy and ILM Peeling Without Laser Treatment for Optic Disc Pit Maculopathy**Yasin Sakir Goker*Goker Eye and Retina Center, Ankara, Turkey*

Case: A 47-year-old female patient, who was followed up for optic neuropathy and retinopathy for three years, applied to our clinic for a second opinion after intraocular injection recommendation. BCVA was 20/20 and 20/200 in the right and the left eye respectively. Biomicroscopic evaluation was unremarkable and IOP was normal in both eyes. Fundus examination revealed optic disc pit and subretinal fluid. SD-OCT of the disc showed optic disc pit with subretinal and intraretinal fluid. The patient was diagnosed with optic disc pit maculopathy and offered 25 G sutureless pars plana vitrectomy and internal limiting membrane (ILM) peeling.

Surgery was started with 25 G corvitrectomy. Posterior hyaloid was very adherent to the optic disc. Kenalog assisted posterior hyaloid detachment was performed with the help of serrated microforceps. The ILM was peeled at 5 optic disc diameters up to the optic nerve. Fluid-air exchange and air-perfluoropropane exchange was performed. Argon laser treatment was not applied.

The intaretinal fluid was decreased at 3rd month follow-up and totally resolved at 9th month follow-up postoperatively. BCVA was 20/63 and no cataract was observed biomicroscopically.

Conclusion: 25 G sutureless pars plana vitrectomy and ILM peeling without laser treatment is effective for the treatment of optic disc pit.

Keywords: Internal limiting membrane, optic disc pit maculopathy, pars plana vitrectomy

[Abstract:0125]**Three Hand Method In Yamane Scleral Fixation In Patients With Aphakia**Yasin Sakir Goker*Goker Eye and Retina Center, Ankara, Turkey*

Purpose: To demonstrate my own surgical method in Yamane scleral fixation in patients with aphakia.

Surgical Technique: 25 G infusion canula was inserted inferotemporally and two side port incisions were made at 2 o'clock and 10 o'clock. A wide anterior vitrectomy was performed. The axis were marked at limbus for the optic position and after that haptic positions were marked 2 mm away from the limbus. Main incision was performed at 11 o'clock. The IOL implanted into the anterior chamber but the trailing haptic was left outside the eye. The injector was entered the sclera at the marked point and advanced intrasclerally until

the bevel is invisible and rotated to the eye with the left hand and forceps was entered from side port with the right hand. The superior haptic was taken into the ajutage and left inside the eye and the ajutage of the injector then removed. Both the hands were unemployed. Now the second injector entered the sclera samely and the injector was given to asistant when it was inside the eye. Both the hands were unemployed again while the asistant was holding the injector. The surgeon then entered the eye with the forceps from the side port incision with the left hand. The trailing haptic was holded 3mm away from the tip of the haptic outside the eye and brought into the eye from the main incision with the right hand and was given to left hand at that position inside the eye. The right hand took back the injector from the asistant outside the eye and the inferior haptic was taken into the ajutage with the left hand inside the eye. Both haptics were taken out of the eye simultaneously while controlling the axis of the optic. Low temperature cautery was used for haptic fixation.

Keywords: Aphakia, Yamane scleral fixation

[Abstract:0133]**The Dancing Delight**Manisha Agarwal*Dr Shroff's Charity Eye Hospital*

A 30 year old male patient presented with sudden diminution of vision in the left eye to 6/60,N36 for last one week. No history of any systemic illness or any other relevant history. Fundus examination, OCT and ultrasound B scan all confirmed sub retinal cysticercus cyst in the macular area.

Pars plana vitrectomy was done with induction of PVD followed by macular detachment using subretinal fluid injection and the cyst was then guided to the opening using a perfluorocarbon liquid bubble and extruded using passive suction. This technique helped to get the cyst out with minimal damage to the retina and the patient recovered a vision of 6/12,N9

Keywords: cysticercus cyst, PFCL, macular detachment

[Abstract:0142]**Zero Cost Sclerotomy-anchored self-retaining Vitrectomy Contact Lens Holder for MIVS**Sangeet Mittal¹, Nishikant Jaywant Borse²¹Thind Eye Hospital, Jalandhar, India²Insight Eye Clinic, Mumbai, India

Vitrectomy requires high quality fundus visualisation provided by different viewing systems. These are divided in contact and non-contact systems. With advent of non-contact wide angle viewing systems for VR surgery, use of contact lenses is decreasing. Though wide angle non-contact system has advantage of wider field of view, it compromises on resolution and stereopsis. Contact lens is needed for precise surgical manoeuvres in macula and myopic eyes. Contact lens is portable and independent of microscope. Major reason of growing unpopularity of contact lens system is use of sutures to anchor lenses to sclera. We present a new home-made self-retaining ring to hold contact lenses during vitrectomy. 3 strips of sterilised micropore tape are cut to size of 1.5*0.4 cm. Strips are wound around metallic ring which comes with Landers lens system to resemble flanges of ring. Strips are arranged 60 degrees apart from each other. Ring is placed over cornea in such a manner that paper flanges are aligned in meridians where sclerotomies are to be made. While creating sclerotomies trocar passes through paper flanges and cannula is left behind. 3 cannulas placed supero-temporal, supero-nasal and infero-temporal quadrant anchor ring properly in a triangular fashion and provides extreme stability during surgery. Currently available self-retaining contact lenses are highly unstable and requires recurrent repositioning. Flanges in available contact lenses are rigid and don't adjust to ocular surface in all eyes. If eye moves during surgery, contact lenses dislocate and are to be held by assistant. Our ring is anchored to three sclerotomies and provides extreme stability and immobility to contact lenses during vitrectomy. It is easy to use and no additional steps are needed to anchor it. Switch between contact and non-contact system can be done effortlessly. Ring can also hold methylcellulose for longer time during surgery with non-contact system.

Keywords: Vitrectomy, Contact Lenses**[Abstract:0149]****What will you do in a different type of posteriorly dislocated IOL that you did not see before? Rescue or Exchange**

Utku Limon

University of Health Sciences Umraniye Training and Research Hospital Eye Clinic Istanbul/Turkey

Purpose: To discuss whether intraocular lens (IOL) exchange or IOL rescue is more advantageous in a posteriorly dislocated IOL.

Methods: A 71-year-old male patient applied to our clinic due to decreased vision in his right eye. His right eye vision level

was counting fingers from 1 meter. He had cataract surgery 15 years ago. In the anterior segment examination, the patient was aphakic. Intraocular pressure was 15 mmHg in the right eye. The IOL-bag complex was on the macula in the right eye fundus examination. Axial length was 30mm and IOL calculation was 8 diopters in the right eye.

Results: We decided to rescue the patient's IOL by suturing it to the sclera. After subtenon anesthesia 23 gauge cannula entries were made. Iris hooks were used for pupil dilatation. After anterior and core vitrectomy triamcinolone was used for posterior hyaloid visualization. Peripheral vitrectomy was completed after the posterior hyaloid was seen to be separated. Then, the IOL on the macula was floated with decalin to the iris plane. The IOL was sutured with 9 /0 prolene sutures using the loops in the IOL edges to the sclera at 4 quadrants without opening the conjunctiva. The fibrotic lens capsule was removed with vitreous cutter and micro scissors. Loop-shaped suture nodes were twisted and embedded into the sclera. In the first month postoperatively, the patient's visual acuity was 0.1 decimal and his IOL was centralized and stabilized. The surface of the sutures, in which knots were embedded in the sclera without opening the conjunctiva, was then spontaneously closed with the conjunctiva.

Conclusions: Centralized and stabilized IOL can be achieved by suturing the IOL-bag complex to the sclera from 4 points without opening the conjunctiva. Complications related to sutures are avoided by turning and embedding the suture knot into the sclera.

Keywords: Posteriorly dislocated IOL, IOL Exchange, IOL rescue

[Abstract:0154]**The Hidden Ghost ! Techniques of PVD Induction**

Manisha Agarwal

Manisha Agarwal

Induction of posterior vitreous detachment (PVD) is a task impossible in certain patients however it forms the backbone of every vitreoretinal surgery. Many a times we may think that we have induced the PVD but when we finally do it we realize that it was a hidden ghost which came out now after much chasing. This video highlights the various techniques which can be used to induce the PVD and provide tips and tricks for the same thereby helping the beginners in ensuring a complete PVD

Keywords: posterior vitreous detachment

[Abstract:0156] Sewing the Cleft

Manisha Agarwal

Dr Shroff's Charity Eye Hospital

A 14 year old boy with diminution of vision in the right eye to 6/24,N24 following an injury with a badminton racket 4 months back. The applanation tonometry recorded an IOP of 2 mm of Hg in the right eye. There was a subluxated lens with an evidence of 360 degree cyclodialysis cleft on gonioscopy. There was hypotonus maculopathy with a hyperemic swollen disc. The boy underwent pars plana lensectomy and anterior vitrectomy and intraoperative gonioscopy to confirm the extent of the cyclodialysis cleft. This was followed by the sewing machine technique of repairing the cyclodialysis cleft using a 26 gauge needle, 30 gauge needle and 10-0 prolene suture.

Follow up at 12 weeks the IOP was 18 mm of Hg and the best corrected visual acuity was 6/9,N6 with +11 D sphere correction.

This video shows the novel Sewing machine technique of “Cyclodialysis cleft repair”

Keywords: cyclodialysis cleft

[Abstract:0166] Management of a large metal intraocular foreign body

Meriem Abdellaoui, Hassan Moutei, Ahmed Bennis, Idriss Andaloussi Benatiya

University Hospital Hassan II, Ophthalmology department, Faculty Of Medicine Of Pharmacy And Dental Medicine, Fez Morocco

Purpose: Intraocular foreign body (IOFB) removal becomes tricky if its large and impacted in the ocular coats. When confronted with such a combination, the vitreoretinal surgeon will need to modify the surgical plan. This surgical video demonstrates one of such situation encountered during removal of a long IOFB impacted in the ocular coats.

Case: A 40-year-old presented man with sudden vision loss and pain in the right eye because of ocular trauma while cutting metal. The best corrected visual acuity (BCVA) of the right eye was hand motion. A slit lamp examination revealed an oblique linear full-thickness scleral laceration with microhyphema. Fundus details was obscured by a dense vitreous haze with a suspected IOFB in the upper quadrant. The presence of an IOFB with a localised retinal detachment was confirmed by ultrasonography.

The patient initially benefited from a scleral suture. In a second step, a simultaneous extraction of the lens and a vitrectomy were performed 72 hours after the trauma. The IOFB turned out to be an extremely long steel wire (18 mm), which makes extraction difficult.

Extraction with an IOFB forceps pulled the IOFB into the vitreous cavity. The IOFB was pushed to the opposite region of the pars plana to avoid injury valuable ocular structures. Given its size, the IOFB was removed through a corneal incision. An endolaser was applied for retinal tears. C3F8 gas tamponade was performed.

The BCVA at the last follow-up visit was 1/10 with attached retina. Discussion The video depicts a scenario in which the surgeon becomes aware that injury to the ocular structure is unavoidable due to the inherent length of the IOFB.

Conclusion: Careful assessment of the situation where the IOFB is large helps the surgeon identify how he might minimize damage to the eye and not put vision at risk.

Keywords: IOFB, Trauma, retina

[Abstract:0167] How aggressive should we be in the treatment of post-injection endophthalmitis with pars plana vitrectomy?

Utku Limon

University of Health Sciences Umraniye Training and Research Hospital Eye Clinic Istanbul/Turkey

Purpose: To discuss whether we should treat post-injection endophthalmitis with aggressive pars plana vitrectomy (PPV) or not.

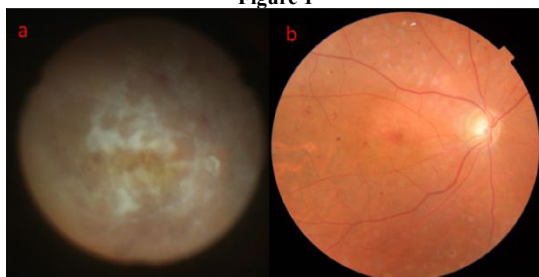
Methods: A sixty-three-year-old man was admitted to our clinic with blurred vision and pain in the right eye four days after an intravitreal aflibercept injection for diabetic macular edema. He had cataract surgery 15 years ago. His vision level was hand motions in the right eye. There was no swollen eyelid in the anterior segment examination. There was 0.5 mm hypopyon in the anterior chamber. Intraocular pressure was 15 mmHg in the right eye. The pupil was not dilated. The vitreous and fundus appearance was hazy.

Results: We treated the patient with immediate PPV. A transconjunctival three-port 23-gauge PPV was done. After 23-gauge cannulas insertion, we took a vitreous specimen without infusion. The hypopyon and fibrin in the anterior chamber were cleared. After anterior and core vitrectomy detached posterior hyaloid was removed. It was observed that there were diffuse hollow vessels in the retina and diffuse white membranes on the macula. All infectious and inflammatory debris in the vitreous and retinal surfaces were removed. The tractional bands and membranes formed on the retinal surface were cleaned. A complete peripheral vitrectomy was performed. Multiple air-fluid exchanges were done to clear all of the debris in the vitreous cavity. After the air-fluid exchange, 1,000 cSt silicone oil tamponade was used. At the end of the surgery, 1:4 diluted vancomycin (0.25 mg/0.1 ml) and ceftazidime (0.50 mg/0.1 ml) were given into the silicone oil.

Conclusion: Immediate PPV is still controversial in post-injection endophthalmitis treatment. Advances in surgical instruments and equipment have provided more successful results and safety in PPV surgery.

Keywords: Endophthalmitis, pars plana vitrectomy, intravitreal injection

Figure 1



Intraoperative [a] and postoperative month 8 [b] image of the patient.

[Abstract:0169]

Novel Technique to Manage Silicone Band Intrusion

Hussain Khaqan

PGMI,AMC,LGH,Lahore

Purpose: To remove the intruded silicone band and manage the complications

Methods: Total 4 cases, male, mean age 16+/-1 were included in this study, presented with silicone band intrusion after encircling buckle. Three eyes has associated retinal detachment. All eyes underwent 23 gauge PPV, cutting the band inside vitreous cavity, complete vitrectomy, air fluid oil exchange.

Results: All four eyes retina attached, in three eyes silicone oil was removed after 04 months. Silicone band internal part has no complications, mean follow up is 18 months.

Conclusion: Cutting the silicone band inside the vitreous cavity with horizontal cutting scissor is novel & safe technique in experts hands to prevent the further complications.

Keywords: Silicone, Band, Intrusion

[Abstract:0180]

Primary Subretinal Hydatid Cyst

Huseyin Baran Ozdemir¹, Sengul Ozdek¹, Kaan Ozkan¹, Nalan Akyurek²

¹Department of Ophthalmology, Gazi University Faculty of Medicine, Ankara, Türkiye

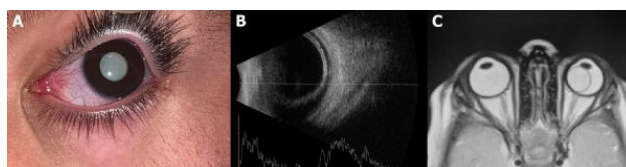
²Department of Pathology, Gazi University Faculty of Medicine, Ankara, Türkiye

This was a 2-year-old boy with leukocoria who was referred to our clinic for a cystic structure with very well-defined borders filling the left eyeball, which was obvious both in ultrasonography and MRI. A limbal lensectomy and

vitrectomy were performed. The cyst was under the retina and the base was attached strongly to the nasal choroid. The cyst fluid was first aspirated with a 41G cannula to make it smaller and it was dissected from the overlying retina and underlying choroid from the attachment site in the nasal quadrant and it could be extracted as a whole without damaging the cyst wall from a limbal incision with the help of a cryo-probe. The retina was reattached, lasered and tamponaded with silicone oil. The retina stayed attached after removal of silicone oil and the child has ambulatory vision with that eye.

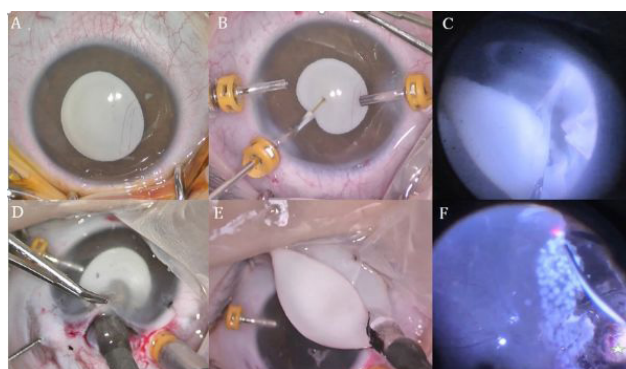
Keywords: cyst hydatid, vitrectomy, subretinal

Figure 1



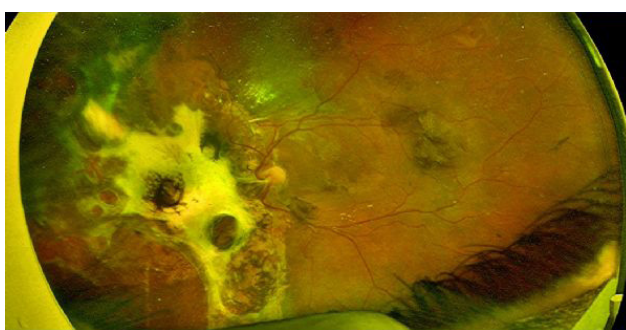
A) An external photo of the child with leukocoria. B) B-scan ocular USG image shows a large well-defined anechoic cystic lesion. C) T2-weighted MRI confirms the cystic lesion with the same intensity as the vitreous, which is located nasally.

Figure 2



(Preoperative appearance of the hydatid cyst causing leukocoria. B) Aspiration of the hydatid fluid using a 39-gauge needle. C) Dissection of the cyst from the nasal choroidal attachment site. D - E) Removal of the hydatid cyst using a cryoprobe through the limbus. F) Application of the barrier laser photocoagulation at the edge of the retinectomy.

Figure 3



Wide-field fundus image 18 months after the silicone oil removal. Note that there is no recurrence of PVR with totally attached retina

[Abstract:0181] Retinal Icicles

Manisha Agarwal
Dr Shroff's Charity Eye Hospital

A 17-year-old boy ambulatory till 5th standard and now with a vision of PR inaccurate in the right eye with a complicated cataract and chronic retinal detachment with advanced proliferative vitreoretinopathy (PVR) changes following an injury with a brick. The left eye was no perception of light with a closed funnel retinal detachment. An informed consent was taken and guarded visual prognosis explained.

He underwent pars plana lensectomy followed by total vitrectomy and 360 relaxing retinectomy due to anterior PVR. On eversion of the retina there were multiple crystalline deposits of calcium oxalate resembling “icicles” which were sent for biochemistry evaluation. Finally PFCL-silicone oil exchange was done to settle the retina.

Post-operatively he gained a vision of 5/60 and again became ambulatory.

This video highlights the formation of retinal icicles which are calcium oxalate crystals which deposit due to a change in pH in chronic retinal detachment and retinal degeneration.

Keywords: PVR, RD

[Abstract:0182] Spinning the web

Manisha Agarwal
Dr Shroff's Charity Eye Hospital

A 11 year old one eyed boy with vision of 1/60 in the left eye, aniridia, subluxated lens and rhegmatogenous retinal detachment with PVR and vitreous hemorrhage. A history of glaucoma with gross cupping of ONH.

A pars plana lensectomy was done followed by total vitrectomy and this was followed by silicone oil retension sutures by rail road technique to keep the silicone oil away from the anterior chamber thereby protecting from increase in intraocular pressure and decompensating the cornea. Silicone oil was injected subsequently.

Silicone oil removal was done and the child gained a vision of 6/60, N36 making him ambulatory again

This video highlights the technique of silicone oil retension sutures in such aniridic patients thereby helping in avoiding a decompensation of the cornea and visual rehabilitation.

Keywords: oil retension sutures

[Abstract:0183] Double Trouble

Manisha Agarwal
Dr Shroff's Charity Eye Hospital

A 40-year-old gentleman with a history of wooden stick injury in the only seeing eye and a vision of projection of rays inaccurate. He sustained a corneal perforation with a uveal tissue prolapse in the right eye which was managed with corneal tear repair. There was double trouble in the form of a corneal opacity and a closed funnel retinal detachment (RD) on ultrasound B scan.

He underwent removal of the corneal button with fixation of a temporary keratoprosthesis (KP). There was RD with severe PVR and pars plana vitrectomy was done with membrane peeling. A small foreign body was delivered out leading to leakage from the holes of the KP and glue was used to stop the leakage. Membranes from the undersurface of the retina were peeled and perfluorocarbon liquid was injected and then exchanged with silicone oil leading to attachment of the retina and corneal transplant was done. Follow up at 6 months patient had a vision of 6/36, N36.

Keywords: combined surgery, RD, PK

[Abstract:0184] Internal Drainage of the Choroid

Manisha Agarwal
Dr Shroff's Charity Eye Hospital

A 65 years old male patient with a history of cataract surgery done elsewhere done 4 days back and a vision of counting fingers close to face in the left eye. Ultrasound B Scan showed retinal detachment with choroidal detachment and vitreous hemorrhage. A possibility of globe perforation during peribulbar block could not be ruled out.

He underwent pars plana vitrectomy, membrane peeling and perfluorocarbon liquid injection. There was a huge choroidal mound involving the macular area with a possible site of iatrogenic trauma with a needle during the block causing a perforation inferiorly. An internal drainage of the choroidal mound was done using diathermy followed by fluid air exchange and finally silicone oil was injected. At 3 months the vision improved to 6/36, N18 with a well attached retina.

Keywords: choroidal detachment, drainage

[Abstract:0218]**Diabetic total tractional retinal detachment**Yurdacan Demir¹, Melih Kurt²¹*Ozel Hayat Hastanesi, Bursa, Turkey*²*Göz Nurunu Koruma Vakfı, Bursa, Turkey*

42 year old male. diabetic. There is diabetic total tractional retinal detachment in the left eye. visual level light sensation. phaco was performed first in the phakic patient. In 25 g vitrectomy, all tractions were removed from the retinal surface with forceps, scissors and cutter. The central retina was attached with the help of a dkline. Peripheral vitreous was cleaned. After laser, silicone tanponad was placed.

After 3 months, the silicone was removed. The membranes on the inferior temporal arch were peeled off.

In the next 2 months, the vision was 0.2, the retina was attached.

Keywords: tractional retinal detachment

[Abstract:0224]**Pvr after diabetic vitrectomy**Yurdacan Demir¹, Melih Kurt²¹*Ozel Hayat Hastanesi, Bursa, Turkey*²*Göz Nurunu Koruma Vakfı, Bursa, Turkey*

58 years old diabetic male.monocular patient. vision light sensation.

He had diabetic vitrectomy surgery in another clinic 3 months ago.

PVR is present in all four quadrants of the posterior pole retina. The macula is in a detached state.

First, triban blue staining and PVR membranes were peeled off at the posterior pole.

Adhesion to the posterior pole was achieved with dkline fluid. It was observed that vitreous cleaning was done less in the periphery.

As much as possible some of the vitreous was cleared. then all the pvr membranes in the posterior pole were peeled from the retinal surface

It was observed that the.ilm membrane was peeled in the previous surgery.

The entire retina was attached and laser applied.

Silicone oil was given as tanponad.

The postoperative retina was attached.

After 3 months, the silicone was removed.

Vision was counting fingers from 3 meters

Keywords: pvr, diabetic, vitrectomy

[Abstract:0228]**Severe Mixed PFV: See The Light At The End Of The Funnel**Ece Özdemir Zeydanlı¹, Şengül Özdek²¹*Ankara Retina Clinic, Ankara, Turkey*²*Ophthalmology Department, Gazi University School of Medicine, Ankara, Turkey*

Purpose: To present the role of vitreoretinal surgery in a case of severe persistent fetal vasculature (PFV) with retinal dysplasia, a rare PFV phenotype that has been mostly considered inoperable and has no visual potential to date.

Method: Video presentation.

Case: A 2-month-old boy with bilateral severe closed-funnel mixed type PFV underwent limbal lensectomy-vitrectomy. The pupil was leukocoric with synechiae. A wide opening of the funnel was possible with painstaking dissection of membranes. The dysplastic retina remained detached but receded and became shallow over time. The patient achieved light perception vision in both eyes.

Conclusion: Vitreoretinal surgery can provide light perception and a cosmetically acceptable globe in the most severe forms of PFV, where no treatment has historically been recommended.

Keywords: Persistent fetal vasculature; persistent hyperplastic primary vitreous; tractional retinal detachment

[Abstract:0240]**Pars plana vitrectomy for fungal endogenous endophthalmitis in a patient receiving chemotherapy after operation for malign pancreas neoplasm**

Dilek Güven

Acibadem Maslak Hospital, İstanbul, Türkiye

A 66 years old Caucasian female patient who had been diagnosed as malign pancreatic neoplasm and operated was under chemotherapy through subcutaneous catheter. After surgery she complained due to a decrease of visual acuity and redness attacks on her left eye. She had had multiple previous hospitalisations due to nausea and lethargy. Ophthalmology consultation on postoperative(PO) 2 months, revealed visual acuity of 10/10 OD and light perception OS, conjunctival hyperemia, +3 anterior chamber cells, thin pupillary membrane at the pupil edge, minimal nuclear sclerosis and vitreous condensation on the left eye. The right eye showed normal findings. Serum inflammation markers were also increased and she was suspected to have an endogenous endophthalmitis. Blood, urine, aqueous and vitreous samples were taken for culture. Systemic fluconazole and antibiotic treatment, and topical fortified antifungal and antibacterial treatment were initiated. Blood, urine, aqueous and vitreous cultures were negative for aerobic, anaerobic bacteria and fungus. Aqueous tab and anterior chamber lavage with synechiolysis was made, and twice intravitreal antibiotic and antifungal injections

were applied with 3 day-interval. Ultrasonography revealed vitreous condensation and subretinal opacity. One day after the last injection, visual acuity was light perception, there was 0.5-1mm hypopyon, and posterior vitreous detachment with focal optic disc attachment. Under general anesthesia cataract extraction, pars plana vitrectomy and silicone oil injection was performed. Postoperatively, she received topical and systemic antifungal therapy for 6 weeks. Three months after the operation last visit revealed best corrected visual acuity of 6/10 OS. She was aphakic with open peripheral iridectomy, clear anterior chamber, attached retina and silicone oil without emulsification. There was no inflammatory findings and the optic nerve was pale. There was no retinobulbar scarring.

In this video, the approach for an endogenous endophthalmitis is demonstrated.

Keywords: endogenous endophthalmitis, PPV, fungal

[Abstract:0249] Congenital cataract vs PFV

Omer Othman Abdullah
Ibinsina Modern Eye and Retina Center

The aim of the video is to demonstrate how to manage the anterior PFV. And ways to differentiate it from the congenital cataract.

Keywords: PFV, Congenital cataract, Pediatric

[Abstract:0250] Every case deserves a chance, a chronic suprachoroidal hemorrhage from no light perception to counting finger of one meter

Omer Othman Abdullah
Ibinsina Modern Eye and Retina Center

A 68-year-old male was referred for his suprachoroidal hemorrhage after a sharp trauma in his left eye. Three times surgical intervention performed elsewhere in 6 weeks, the retina was folded in the anterior chamber and his visual acuity was no light perception.

The aim of operation was to preserve the shape of the eyeball and preventing more hypotony.

The suprachoroidal components drained via sclerotomy and anterior chamber maintainer, followed by bimanual meticulous and cautious dissections of the fibrous tissue to unfold the retina. A 360-degree retinectomy performed to flatten the retina, followed by a injection of silicone oil 5000.

In the first post-operative the visual acuity was light perception/ hand movement?!. After one month became counting finger one meter

Keywords: Chronic supra-choroidal hemorrhage, pars-plana vitrectomy

[Abstract:0259] Perplexing case of initially presumed dropped nucleus 15 years after perforating trauma

Assem Mejaddam
Uppsala University Hospital

This is a case of a 40-year-old male patient who had undergone scleral suturing and core vitrectomy due to a zone 2 open globe trauma from a nail 15 years ago. He had good visual function until recently. During preoperative examination a white lens fragment could be seen in front of a clearly visibly posterior lens capsule. The anterior lens capsule, however, could not be clearly visualized while the space around the single lens fragment was entirely clear. I present here the surgical procedure, including Yamane technique IOL fixation, of this very perplexing case which to my knowledge is unique in its kind.

Keywords: Yamane scleral fixation, trauma, cataract

[Abstract:0280] Tackling an evasive sub-foveal Cyst

Jayanto Shekhar Guha
SRF Eye Hospital, New Delhi, India

The video shows bimanual technique of removal of sub-foveal cysticercus cyst. After PVD induction using IVTA and vitrectomy, macula was detached using 40G cannula to create space for the cyst. Instantaneously cyst creates a macular hole, tries to escape. When we tried to take it out using a soft tip the cyst retracts back. Using 2 Tano scrapers cyst is moved towards retinotomy. With the Tano scraper stabilising, the cyst was coaxed out of the retinotomy passively and eaten up with the cutter. Next ILM peeling was done under PFCL followed by fluid air exchange and SF6 gas injection.

Keywords: sub-foveal cyst, 40G canula

[Abstract:0295] 10 years after Blunt Trauma... Dehydrated Amniotic Membrane Graft for the Rescue of a 1300 microns Macular Hole

Yassine Malek, Shamil Louaya
Ophthalmology Department Agadir Military Hospital, Souss Massa
University Hospital, Ibn Zhor University, Agadir, Morocco

Introduction: We describe in this Video, the use of a Thin Dehydrated Amniotic Membrane Graft (AMG) for the management of a long-standing (10 years) post traumatic, Macular Hole, with peripapillary atrophy in a pseudophakic 48-year-old man with Best corrected Visual acuity (BCVA) of 1/30.

Material: We conducted a 23G, 4 ports Pars Plana Vitrectomy, with a venturi Pump Machine (Stellaris PC, Bausch&Lomb), and the use of a 100 microns Dehydrated Amniotic Membrane Graft (AmnioTek®-C, ISP Surgical).

Steps of the Surgery:

- Subtenon Block with 4 cc of Lidocaine
- 3 Sclerotomies at 3,5 mm Behind the Limbus (Pseudophakic patient)
- Core Vitrectomy
- Peripheral Vitrectomy
- Brilliant Blue G staining Under Air
- Extensive Internal Limiting Membrane Peeling with Fibroglial Tissue peeling around the hole borders
- Insertion of a 4th port for the chandelier Light
- Sizing the AMG with a 2mm dermatologic Punch
- Introducing The AMG through the Trocar
- Failure of the first Attempt to Bimanually mobilize the AMG
- Perfluoro Carbon Liquid (PFCL) injection after lowering the Infusion pressure
- Mobilizing the AMG with 2 Forceps under PFCL
- AMG placed under the border of the Macular Hole, delicately.
- AIR against Fluid Exchange
- Nasal Retinal Detachment developed
- Peripheral Indentation and visualization of a iatrogenic brake under the Superior Temporal Trocar
- Laser Retinopexy with 3 rows around the peripheral tear
- Completion of - AIR against Fluid Exchange
- AIR against PFCL Exchange
- Air against C3F8 (14% nonexpansile) Exchange
- Suture of leaking Sclerotomies

Outcomes: Swept Source OCT B-Scan at Day 7 demonstrated Hyperreflective material within the macular hole, representing the AMG, while Results at 2 months showed type 2A closure. BCVA at 3 months improved to 6/30.

Conclusion: This case Highlights the peroperative difficulties of mobilizing AMG

Keywords: Amniotic Membrane Graft, large Macular Hole, Posterior Pole

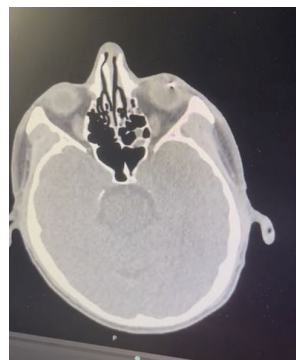[Abstract:0334] Hidden Metallic Foreign Body At Ora Serrata Behind Dense Vitreous

Mahmut Oğuz Ulusoy
Ophthalmology Department, Bursa Yüksek İhtisas Research Hospital,
Bursa, Turkey

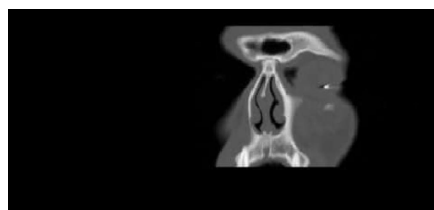40 years old male patient with intraocular metallic foreign body (fb) history (ten days) was undergone vitrectomy. The entrance of fb was seen on superior iris and cornea. He has traumatic cataract and fundus was not seen clearly. On computed tomography scan there is a metallic fb image at inferotemporal section. During vitrectomy, we could not find the fb after complete indentation and checked posterior chamber. After that we checked the CT scan again and with indentation of peripheral inferotemporally, we found the 0,6 mm metallic fb, buried at ora serrata behind the dense vitreous.

Keywords: metallic foreign body, pars plana vitrectomy, ora serrata

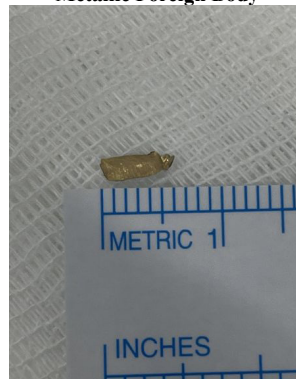CT scan of Foreign Body



CT scan of Foreign Body2



Metallic Foreign Body



[Abstract:0341] Posterior Vitreous Detachment in Old pediatric retinal detachment PFC assisted (mytricks)

Ahmed Mamdouh El Shafei
Research institute of ophthalmology (R.I.O) EGYPT

Traumatic pediatric retinal detachment present in most of the cases late, with PVR ranging from grade B to C. Buckle PPV is one of the most effective ways to treat such cases. One of the most difficult steps is posterior vitreous detachment (PVD), a complete PVD is very important and its success has a great effect on the success and the final visual acuity and the need of further surgeries in such cases. PFC assisted PVD is one of my ways to tackle such difficult step, in this video i demonstrate my tricks to induce PVD using PFC.

Keywords: Pediatric Retinal Detachment, PFC, PVD

[Abstract:0352] TRD Different strategies..!

Sara Ahmed Tawfik
Al-Ferdaws Eye Hospital, Egypt

Video demonstrating traction retinal detachment in proliferative diabetic case with different attack strategies including uni, bi, and trimanual maneuvers.

Keywords: TRD different strategies

[Abstract:0358] Reper artificial iris and intraocular lens complex: a novel approach to traumatic aniridia

Gil Calvão Santos, Keissy Sousa, Petra Gouveia
Hospital de Braga

Traumatic injury can lead to severe iris damage, cataract formation and aphakia. Aniridia or fixed mydriasis leads to glare, photophobia and cosmetic discomfort. The ReperTM artificial iris (Ophtec, Netherlands) is an acrylic-based foldable device with promising functional and cosmetic results to treat large iris defects and fixed mydriasis. It provides good iris detail with satisfying cosmetic appearance and may be embedded with an intraocular lens to correct aphakia through microincisions. This video reports the outcomes of two eyes submitted to ReperTM device implantation. Patient 1 underwent sulcus implantation of the ReperTM with no refractive power in a piggyback configuration after a subluxated, corticonuclear traumatic cataract but complaints of severe photophobia after the first surgery. Patient 2 was implanted with the ReperTM targeted for emmetropia transscleral fixation after a scleral perforation, posterior lens luxation and retinal detachment. After surgeries, anterior segment examination and funduscopy were unremarkable in both patients, with no signs of intraocular inflammation. No

postoperative ocular hypertension was observed. The ReperTM device was properly centered and both patients conveyed high cosmetic satisfaction. The ReperTM intraocular lens/artificial iris complex is a safe and effective novel approach to simultaneously treat aniridia and aphakia. It improves visual acuity and photophobia in patients with extensive iris defects and allows for an excellent cosmetic effect achieved through individual color tailoring.

Keywords: secondary iol, aniridia, artificial iris

[Abstract:0363] The use of Carlevalle IOL as a new simple idea

Keissy Sousa, Nuno Gomes, Gil Calvão Santos
Hospital de Braga

The idea behind the Carlevalle IOL technique is to externalize the anchors of this single-piece IOL through the sclera using either a flap or pocket approach and to cover the IOL haptics with the sclera. In this video we present 3 cases when we use this IOL. Patient 1 is an aphakic patient that was referred for a secondary implantation. Patient 2 was a luxated single-piece IOL that was replaced by this new one. Patient 3 was a traumatic luxated lens with hemovitreous and pupil alteration and all the three combined surgeries were performed at the same time. Anatomic and functional results are quite satisfactory. Some advantages are seen using this IOL instead of other techniques used previously.

Keywords: carlevalle iol, aphakia, scleral fixation

[Abstract:0367] Scleral Fixation with Four Flanged Double Needle Technique

Gamze Dereli Can, Busra Yorulmaz
Department of Ophthalmology, Bursa City Hospital, Bursa, Türkiye

Aim: To present a case of scleral fixation with four flanged double needle technique.

Case: 75 year-old male presented with a history of cataract surgery 2 years ago. Ophthalmological examination revealed that corrected distance visual acuity was CF 2m in the right eye. One piece intraocular lens was subluxated to inferonasal quadrant. The anterior chamber was quite and the fundus evaluation was normal. In his surgery, the subluxated one piece IOL was divided with scissors and removed from the main incision. 6-0 polypropylene suture was cauterized with a thermal cautery pen and compressed with forceps. A hole was made with suture's own needle to create a space for IOL haptic. The same procedure was done with another suture for the other haptic of the IOL. 2mm back from the limbus at 6 and 12 o'clock, an intrascleral tunnel was made with 26 g needle. The suture which has a hole, was passed through this needle's lumen and externalized from corneal incision and another end from the scleral tunnel. The same maneuver was done at the opposite of first sclerotomy. The first haptic of

the IOL was passed from the hole of suture which positioned at first scleral tunnel and was cauterized to create 1st flange. Next, the IOL was placed in the cartridge and implanted from the main incision. The second haptic of the IOL was excluded from the corneal incision and maneuver was repeated to create the 2nd flange. After correct centralization, sutures were cut 2 mm from the basis and cauterized to create the 3th and the 4th flanges.

Conclusion: Secondary IOL implantation using scleral fixation techniques are more complex surgeries and the surgeon should master a steeper learning curve. So, the technical simplicity of the Canabrava's technique may be a reason for preference for new surgeons.

Keywords: Scleral fixation, double-needle four-flanged technique, intraocular lens subluxation

[Abstract:0384]

Surgical treatment of globe ruptures

Paolo Chelini

Hospital of Lucca -Italy


It is a 7 minutes video in which 8 cases of ocular globe ruptures are presented.

The author perform a combined multi-procedure to address anterior and posterior damages within a single surgical and reconstructive step: it allows a reduced number of subsequent surgeries, a lower incidence of complications and then less psychological and physiological stress for the patient.

The author shows the surgical steps: 1) initial assessment of the structural damage suffered by the ocular globe; 2) expose the wound; 3) repositioning of expelled material or, if impossible, excision 4) closing of the wound 5) re-establish intraocular pressure 6) perform a combined multi-procedure of anterior and posterior segments 7) tamponade with silicon oil.

Keywords: globe ruptures

Case Number 6: Air Bag Globe Rupture



Cornea is trasformed in a whitish mush and retina turned into two slips joined together.

[Abstract:0397]

Case of an intraocular foreign body removal with combined phacoemulsification+pars plana vitrectomy

Mehmet Erol Can, Eda Nur Gönültaş Özkan

Department of Ophthalmology, Bursa City Hospital, Bursa, Türkiye

A 51-year-old male patient has a history of metallic foreign body hitting his right eye while working 1 day ago.

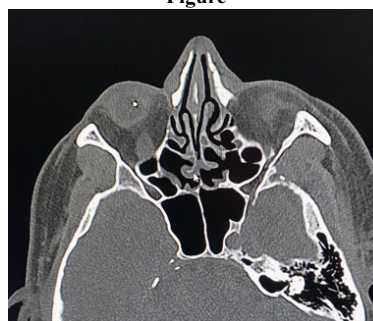The corrected distance visual acuity is hand motion in the right eye. Intraocular pressures (IOPs) measure 15 mm Hg in the right. On slitlamp examination, Corneal perforation, traumatic cataract in right eye. Fundus examination revealed intraocular foreign body (IOFB) in the peripheral retina at 6 o'clock in right eye. Axial CT scan of the patient shows the hyperdense foreign body (Figure)

Surgery was performed under retrobulbar anesthesia. At first, trans-scleral 25-G three ports were placed around 3.5 mm from the corneal limbus. Anterior capsule has been stained with trepane blue and hydrodelantion was done in surgery. Phaco was completed with viscoelastic material support. Posterior capsule break was seen in the end of phacoemulsification. Vitreous was cleared from the anterior chamber and pars plana with a vitrector cannula. When we proceed to the core vitrectomy, foreign body was localized at 6 o'clock peripheral retina and surrounding vitrectomy was done as a standard procedure. Meanwhile the foreign body was released and settled on the macula. Intraoperative perfluorocarbon liquid (PFCL) was applied to protect the macula during IOFB removal. Foreign body was held carefully with the vitrector and brought to the anterior chamber. A 20-gauge microforceps was inserted through the main incision and foreign body was grasped along its longest dimension and removed through the main incision. The peripheral vitreous and PFCL was removed completely. The entire retina was scanned to find any foreign body, breaks, holes, tears.

After ensuring adequate anterior capsule support, the 3-piece IOL was carefully implanted in the sulcus. Fluid air exchange was made. C3F8 gas was then prepared in a %12 concentration was injected. Finally, the trocars are removed and checked about air leakage

Keywords: intraocular foreign body, traumatic cataract, corneal perforation

Figure



Axial CT scan of the patient shows the hyperdense foreign body (long white arrows) in the vitreous cavity and intraocular air

[Abstract:0402]**Utilization of Intraoperative Optical Coherence Tomography in the Diagnosis of a Choroidal Tumor**

Cem Kesim, Umit Yasar Guleser, Murat Hasanreisoglu
Department of Ophthalmology, Koç University School of Medicine

Purpose: To discuss the use of intraoperative optical coherence tomography (OCT) in the evaluation of a possible choroidal tumor in a case presentation.

Case: A 68 year-old female patient previously diagnosed with primary peritoneal carcinoma admitted with low vision on the left eye. On fundoscopic examination, an exudative hemorrhagic lesion and a shallow retinal detachment on the upper retinal quadrant was revealed on the right eye, while the left eye had vitreous hemorrhage (VH) including a 9x5x2.5 mm mass lesion with irregular surface detected with ocular ultrasonography. A pars plana vitrectomy and retinal biopsy procedure was planned for the left eye. Following the removal of VH, the intraoperative OCT revealed a large pigment epithelium detachment (PED) temporal to the macula with absence of intraretinal and subretinal fluid. The intraoperative findings were found consistent with the diagnosis of peripheral exudative hemorrhagic choroidoretinopathy (PEHCR), and the surgery was completed without performing retinal biopsy.

Conclusion: Intraoperative OCT is a useful tool for differential diagnosis of retinochoroidal lesions and can provide valuable guidance for further management of patients.

Keywords: intraoperative optical coherence tomography, choroidal tumor, peripheral exudative hemorrhagic choroidoretinopathy

[Abstract:0405]**Bimanual Surgery for PDR and Table-top TRD - Its time for the ARROW**

Sangeet Mittal
Thind Eye Hospital, Jalandhar

Proliferative Diabetic Retinopathy with extensive fibrovascular proliferation and table top tractional retinal detachment is most difficult to manage. Most of the eyes go blind despite multiple surgeries and using best instrumentation. In this video, we present a new tool, Arrow, to manage these difficult cases. Arrow is a disposable cannulated MVR like instrument. It is shaped like a spear in front with a pointed tip and sharp lateral edges. This is used to dissect membranes in PDR and Retinal detachment. The shaft is long and curved to conform to the shape of globe. This aids in peripheral dissection without damaging the lens or retina. There is a small opening behind its sharp tip. It can be connected to the extrusion pump using a re-useable handle. This helps to remove excessive bleeding during dissection and to perform hydro/visco dissection. The dissection is done using simple to and fro motion and can be

performed with non-dominant hand also. The video shows multiple surgeries in difficult situations using Arrow.

Keywords: PDR, TRD, Bimanual Vitrectomy

[Abstract:0415]**Last hope: into the darkness and beyond**

Ahmed Mansour
Ophthalmology department, Ain Shams University, Cairo, Egypt

This video will show a tough case of diabetic vitrectomy in single eyed patient who underwent a successful bimanual surgery then unusual severe Hemorrhage happened under silicon this video will show the management and the post operative follow up of this patient

Keywords: Diabetic, Bimanual, Bleeding

[Abstract:0416]**Stage 5 rop: 4 hands technique taming the monster**

Ahmed Mansour
Ophthalmology, Ain Shams University, Cairo, Egypt

Video will show a case of stage 5 ROP Where we introduce our novel 4 hands technique in details and strategy of attack together with pre & post operative picture of the case

Keywords: Rop, Stage5, 4Hands

[Abstract:0417]**Fungal endophthalmitis.... the great mimicker**

Ahmed Mansour
Ophthalmology, Ain Shams University, Cairo, Egypt

A case of Fungal Endophthalmitis that has been delayed in diagnosis and lead to complicated tractional retinal detachment and Fibrovascular proliferation... in this video will show the way of dealing with surgery in such difficult case and the post operative outcome

Keywords: Fungal, Endo, Fvp

[Abstract:0418]**Buphthalmous... big eye think bigger**Ahmed Mansour*Ophthalmology department, Ain Shams University, Cairo, Egypt*

in this video will show a case of rhegmatogenous retinal detachment in a 10 yrs old child with Buphthalmous.... the case show one of the challenges in retinal detachment which is sticky post hyaloid in children together with abnormal post insertion of vitreous base and how to deal with such challenges in surgery together with the case follow up

Keywords: Buphthalmous, detachment, hyaloid

[Abstract:0420]**Behcet Uveitis: Boggie under the bed**Ahmed Mansour*Ophthalmology department, Ain Shams University, Cairo, Egypt*

A case of BEHCET UVEITIS Complicated by bilateral Detachment, this video will show the surgery for open funnel RD together with PVR-C in cinematic mode showing the challenges you can face in such case as sticky hyaloid and retinal shortening and how to deal with these challenges

Keywords: Behcet, Boggie, Pvr

[Abstract:0421]**Submacular Hge: From A-Z**Ahmed Mansour*Ophthalmology department, Ain Shams University, Cairo, Egypt*

In this video will show the whole management step by step from start till the end in a case of Submacular hemorrhage together with post operative follow up of the patient

Keywords: SMH, TPA, Vitrectomy

[Abstract:0422]**Chandelier Assisted Phaco: Same Technique different indications**Ahmed Mansour*Ophthalmology, Ain Shams University, Cairo, Egypt*

in this video will show the advantage of chandelier assisted Phaco in cases with different pathologies like corneal opacity, dense vitreous hemorrhage or even combined cases, how to deal with difficulties and how it will improvise ur efficacy

Keywords: Chandelier, Phaco

[Abstract:0424]**Sub ILM hge: Unusual LASER Pen complication**Ahmed Mansour*ophthalmology department, Ain Shams University, Cairo, Egypt*

A case of 10 y old boy that has been hit by LASER Pen in his eye from v,near distance and came with diminution of vision and Sub ILM hge, in this video will show this unusual complication, its management & follow up

Keywords: Subilm, LASER, Macula

[Abstract:0426]**A New Method for Removal of Subfoveal Perfluorocarbon Liquid (Bubble): Internal Limiting Membrane Peeling and Direct Aspiration**Mehmet Citirik, Mehmet Yasin Teke*University of Health Sciences, Ankara Etlik City Hospital*

Perfluorocarbon liquids (PFCL) are an effective temporary tamponade used in vitreoretinal surgery for retinal diseases such as retinal detachment, recurrent retinal detachment, tractional retinal detachment, giant retinal tear, and proliferative vitreoretinopathy.

However, one of the most important postoperative complications of PFCL is the presence of PFCL in the subretinal area, which is seen in 7.8%.

This location can be in the subfoveal, parafoveal, or extrafoveal region.

Subfoveal location causes serious visual problems and it is known to be toxic to the photoreceptor cell and retina pigment epithelium.

There are some procedures for removal of subfoveal PFCL such as performing a retinotomy near to the macula and PFCL extractions using various microcannulas. In addition, although various procedures such as submacular injection of balanced salt solution (BSS) have been suggested. But retinal damage caused by high pressure in these procedures is a serious problem.

In this video, we present the surgery in patients with subfoveal PFCL, which we practice as a surgical technique that has been used for a long time in our clinic, trying to minimize retinal damage without retinotomy.

Technique

- Inner limiting membrane (ILM) peeling
- Directly aspirating subfoveal PCFL with a 25/27 G silicone-tipped flute cannula
- Then perfluoropropane (C3F8) gas tamponade
- 5 days prone position

Keywords: Vitreoretinal Surgery, Perfluorocarbon liquid, Subfoveal

[Abstract:0433]**Small incision four-point fixation IOL suture**

Ma Del Socorro Esmeralda Melendez Ledesma¹,
Efraín Romo García²

¹Retina Department, Hospital Civil de Culiacán, Universidad Autónoma de Sinaloa, Culiacan, Sinaloa, Mexico

²Retina Department, Hospital Civil de Culiacán, Universidad Autónoma de Sinaloa, Culiacan, Sinaloa, Mexico; Hospital Oftalmológico de Sinaloa, Culiacan, Sinaloa, México

This is a surgical procedure for scleral fixation of an Akreos IOL using GoreTex sutures. This patient had a three piece IOL luxation. First, a partial conjunctival peritomy was created in temporal and nasal areas 180° apart from each other, a regular pars plana vitrectomy was made to explore the retina and remove the luxated IOL. A 2.8mm port was made in cornea and tree-piece IOL was removed with a pacman technique. After that, using a Mendez ring, we marked the 0° and 180°, and then a 2mm point from the limbus was marked in each side. Then, two more points 2mm away superior and inferior were marked in both nasal and temporal sides, a 27G trocar was placed in each of them. Outside the eye, two pieces of CV-8 Gore Tex sutures were passed into the haptics of each side of an Akreos adapt IOL (Bausch and Lomb), and one of the sides was stained with blue to be differentiated from the other. Then, IOL was placed into an Envista Bausch and Lomb IOL BLIS injector avoiding crossing the sutures. The IOL was injected through the main port and each of the suture parts were passed through each of the four trocars taking care to place the correct side of the suture in the corresponding trocar and not crisscross them. The IOL was centralized and trocars were removed, sutures were tied in a 3-1-1 knot. After this, knots are rotated and buried into the sclera. The eye was left with a partial air-fluid tamponade, the remaining trocars were removed. Finally, conjunctiva was replaced and sutured with Vycril 7-0.

Keywords: IOL suture, small incision, four point fixation IOL

[Abstract:0435]**Large sized melanoma with extra ocular extension: Is there a way to conserve??**

Ihab Saad Othman¹, Ihab Saad Othman²

¹Faculty of Medicine, Cairo University, Cairo, Egypt

²EyeWorld Hospital, Giza, Egypt

Introduction: Management of large sized uveal melanoma includes enucleation, lamellar resection, iodine plaque brachytherapy and charged particle irradiation. The presence of extra-scleral extension limits management to enucleation. Conservative surgery is complicated

Methods: Two cases presented with an extra-large uveal melanoma and refused enucleation. A planned I partial lamellar scleo-uveal (PLSU) resection was planned under severe hypotensive anesthesia. An unexpected extra-scleral extension (ESE) was found during surgery imposing a surgical challenge. A partial lamellar resection was performed and was

changed to a full thickness scleral resection at the site of ESE. After tumor excision, the scleral flap was repositioned with a scleral patch closing the scleral defect. A plaque brachytherapy was used as adjuvant therapy in one patient and transpupillary thermotherapy was used for the second one

Results: The uveal melanoma could be safely and totally resected using this technique. Postoperatively, vitrectomy was necessary in one patient. Ocular salvage with tumor control could be achieved over 5 years follow up.

Conclusion: Uveal melanoma with extraocular extension pause a special challenge to surgeons performing partial lamellar uveal tumor resection. Improvising to remove the tumor en bloc proves successful in such cases.

Keywords: Melanoma extraocular extension

[Abstract:0453]**The Mystery of the Missing Retinal Hole**

Nishikant Jaywant Borse

Insight Eye Clinic, Mumbai, India

Locating and treating a retinal hole or tear is a key step in a Retinal Detachment surgery.

Unfortunately the retinal break cannot be localised in about 5% of cases of Rhegmatogenous Retinal Detachment. This incidence is much more in pseudophakics and in eyes with hazy media.

This video demonstrates a technique whereby the BBG dye is injected after vitrectomy, in the subretinal space in cases of Retinal Detachment with non localisation of the retinal break. PFCL is then injected into the vitreous cavity. The PFCL increases the hydrostatic pressure of the sub retinal space there by leading to egress of the BBG stained dye from the retinal breaks. This helps in locating the retinal break and subsequently towards a successful surgery

Keywords: Retinal Detachment, Subretinal BBG

[Abstract:0462]**Use of RGP lens as Temporary Keratoprosthesis in Open-Sky Technique for Heterotopic Keratoplasty**

Allurie Pulanco Ume¹, Richmond Ramirez Siazon¹, Maria Fideliz Dalisay De La Paz²

¹Department of Ophthalmology, Ilocos Training Regional and Medical Center, San Fernando City, La Union, Philippines

²Barraquer Ophthalmology Center, Barcelona, Spain

Purpose: To present a case of a combined procedure of heterotopic autokeratoplasty and ECCE with posterior chamber intraocular lens (IOL) implantation, and to demonstrate the novel use of an RGP lens as a safe, cost-effective alternative to temporary keratoprosthesis.

Report of Case: A 65/F presented with blindness, OS from glaucoma but with a clear cornea, and corneal decompensation with cataract in OD with good visual potential.

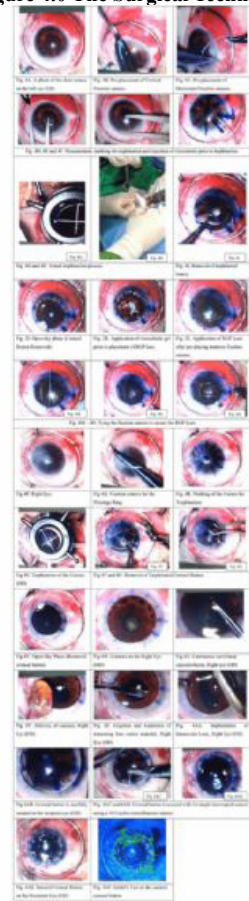
Heterotopic autokeratoplasty was performed due to the scarcity of corneal allografts and the high-risk nature of the case, with ECCE and IOL implantation in OD due to lens opacity. Temporary keratoprosthesis (TKP) was substituted for RGP due to lower cost and high availability. Pre-placement of two polyglactin perpendicular mattress sutures in the episclera at the horizontal and vertical positions was done and left untied. Next, left corneal trephination was performed using an 8-mm vacuum trephine, followed by the instillation of OVD and placement of a 10-mm diameter RGP lens over the left open globe, secured in place by tying the pre-placed overlying cross sutures. Then, right corneal trephination using a similar-sized trephine proceeded. Cataract was extracted in open-sky technique with IOL in the bag implantation. The clear left corneal button was then transplanted to OD and vice-versa.

Postoperatively, VA improved from hand motions to 10/200 (Day 1). The graft remained clear 4 weeks post-op with further improvement in VA. IOP was maintained below 15 mmHg.

Conclusion: Heterotopic autokeratoplasty is a valid option for unilateral cornea blind patients who have clear corneas in the fellow eye with no visual potential. This is useful in countries where corneal transplantation is costly, especially during time of pandemic when corneal allografts are scarce. In our experience, it can be safely performed using an RGP lens as a safe and cost-effective alternative to temporary keratoprosthesis.

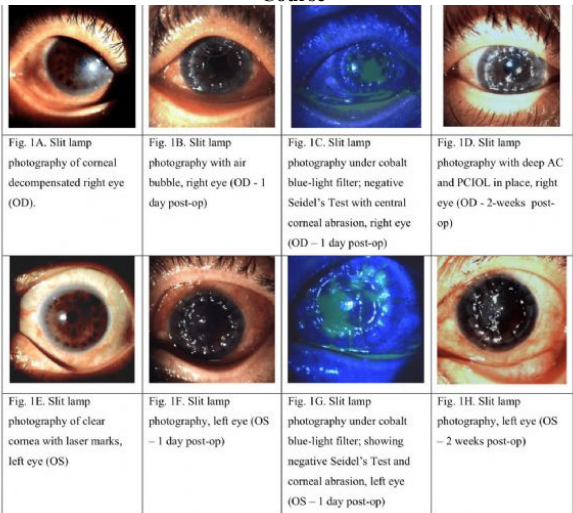
Keywords: RGP Lens, Temporary Keratoprosthesis, Heterotopic Autokeratoplasty

Figure 4.0 The Surgical Technique



This is a step-by-step procedure outlining how heterotopic autokeratoplasty and ECCE were performed with the insertion of posterior chamber IOL using a novel technique involving the use of an RGP lens as a temporary keratoprosthesis.

Figure 5. Clinical Slit lamp photography illustrating the Clinical Course



Clinical Course of Right eye (OD) and Left (OS) eye, before and after the procedure.

[Abstract:0478]**Nuances in management of Pediatric retinal detachments- A tale of 2 cases**

Neeraj Sanduja, Charu Malik, Arnoev Sanduja
Viaan Eye and Retina Centre Gurgaon India

Pediatric retinal detachment (RD) unlike RDs in adults tend to have a chronic duration, worse presenting visual acuity, macula involvement, and proliferative vitreoretinopathy (PVR) development at presentation. Surgical repair of RD in pediatric patients is a challenge for the vitreoretinal surgeon, especially due to sticky vitreous, difficulty in inducing PVD and also high risk of recurrence. Our videos shows unique presentation of pediatric retinal detachment with giant retinal tear in absence of posterior vitreous detachment and its successful repair with vitrectomy, PVD induction with intraocular forceps, laser with silicon oil injection.

Keywords: Pediatric Retinal detachment, Giant retinal tear

[Abstract:0485]**Bilateral Terson Syndrome with Sub-ILM Hemorrhage and Rare Finding of Hemorrhage Liquefaction and Taut ILM: A Case Report**

Sadık Altan Oza, Ece Oza, Serhat Ermis, Murat Karapapak, Yusuf Cem Yılmaz, Serife Ciloglu Hayat, Hakan Baybora
Department of Ophthalmology, Basaksehir Cam and Sakura City Hospital, Istanbul, Türkiye

purpose: We present a case of bilateral Terson Syndrome with sub-internal limiting membrane (ILM) hemorrhage, which demonstrated a rare finding of hemorrhage liquefaction and taut ILM.

Methods: A 32-year-old female with aneurysmal subarachnoid hemorrhage and bilateral Terson syndrome presented to the Ophthalmology department with blurred vision. Due to the patient's poor general condition, pars plana vitrectomy surgery was performed on her right eye six weeks later, as the left eye had a history of amblyopia. Core vitrectomy, hyaloid detachment, ILM puncture, aspiration of the liquefied material, and peeling of the ILM were performed. During ILM peeling, we observed that the sub-ILM hemorrhage liquefied, causing the ILM to become taut, similar to the liquefaction observed in the cortex of white cataracts.

Results: Despite a massive sub-ILM hemorrhage, the postoperative outcome was favorable, with a final best-corrected visual acuity of 20/20 in the right eye.

Conclusion: As the intervention time for sub-ILM hemorrhages prolongs, the hemorrhage can liquefy and cause the ILM to become taut. In such cases, an ILM puncture and aspiration of the liquefied material may facilitate the peeling of the ILM.

Keywords: Terson Syndrome, Sub-internal limiting

membrane hemorrhage, Pars plana vitrectomy

[Abstract:0488]**When the retina falls apart: Retinal detachment in Acute Retinal Necrosis**

Katarzyna Chwiejczak
Sheffield Teaching Hospitals NHS Foundation Trust, University of Sydney

Aim: To present surgical technique of retinal detachment (RD) repair in treated acute retinal necrosis (ARN)

Case Presentation: Seventy four -year old male patient with history of ARN, diagnosed at the end of November 2022, treated with intravitreal injection of gancyclovir, systemic acyclovir and oral and topical prednisolone who presented with macula on RD about 6 weeks later. At that point there was no active inflammation. The RD was secondary to extensive retinal atrophic areas. Vitrectomy with meticulous laser around all atrophic areas and cryotherapy was performed. Densiron oil was used as a tamponading agent.

Conclusions: In treatment of retinal detachment associated with ARN care needs to be taken to treat all areas of friable retina. Silicone should be considered as a tamponading agent, especially if areas of necrosis are extensive.

Keywords: Acute Retinal Necrosis, ARN, retinal detachment

[Abstract:0490]**“The Abyss & What Lies Beneath!” – challenges in surgical management of Optic Disc Pit Maculopathy**

Saurabh Luthra¹, Shrutanjoy M Das¹, Shweta Parakh¹, Vaibhav Bhatt¹, Abhijaat Chaturvedi¹, Neeraj Sanduja², Nishikant Jaywant Borse³, Sangeet Mittal⁴
¹Department of Vitreoretina and Uvea, Drishti Eye Institute, Dehradun, India

²Department of Retina, Viaan Eye Centre, Gurgaon, India

³Department of Retina, Insight Eye Clinic, Mumbai, India

⁴Department of Retina, Thind Eye Hospital, Jalandhar, India

A 20 year old girl with optic disc pit maculopathy and gross neurosensory detachment, retinoschisis with foveal thinning underwent fovea-sparing ILM peeling, juxtapapillary temporal ILM Flap apposition over pit, air fluid exchange with C3F8 gas tamponade. At 18 months follow-up, the macular NSD had resolved completely, retinoschisis almost resolved and vision improved from 3/60 to 6/9p. She underwent focal laser to temporal juxtapapillary retina. At 2 years follow-up, the macular NSD and retinoschisis resolved but there was persistent SRF inferotemporal to the optic disc not in continuation with the pit. She underwent ILM peeling from the disc inferior pole with apposition onto the pit, endolaser to temporal juxtapapillary retina and extended ILM peeling over the SRF and fovea with C3F8 gas tamponade. 5 weeks post re-surgery, vision improved to 6/6p, and there was reduction in persistent SRF. Patient is on follow-up.

A 17 year old boy with ODP maculopathy and gross NSD underwent 25G vitrectomy. During PVD induction, initially there was poor staining of preretinal cortical vitreous at posterior pole. During subsequent restaining with IVTA, there was inadvertent submacular triamcinolone injection. Majority of the submacular IVTA was successfully aspirated out of the pit with soft tip extrusion. Post AFX, part of the residual submacular IVTA was gently massaged out through the pit into the optic cup with 25G loop. Juxtapapillary ILM was peeled after staining with BBG dye and apposed onto the pit. At 10 weeks follow-up, BCVA improved to 6/36, optic pit was closed with resolved macular NSD, shallow SRF temporally. At 2 years follow-up, SRF had resolved completely with BCVA improved to 6/24. In certain anomalous variants of optic disc pit maculopathy, one may preempt the complication of submacular migration of IVTA, this may warrant cautious limited induction of PVD, leaving some vitreous attached over the optic pit.

Keywords: optic disc pit maculopathy, retinoschisis, submacular triamcinolone

[Abstract:0497]

Treatment of a Giant Macular Tear with Amniotic Membrane in a Case of Shaken-Baby Syndrome with RRD Associated with Dialysis and Giant Retinal Break

Huseyin Baran Ozdemir, Sengul Ozdek, Merve Nur Yilmaz
Department of Ophthalmology, Gazi University Faculty of Medicine,
Ankara, Türkiye

This video includes a series of surgeries for the treatment of retinal detachment associated with a temporal retinal dialysis plus giant retinal tear (GRT) and a giant macular tear (GMT) in a premature baby traumatized by her parents at 35 weeks of gestational age. After the first surgery, although GRT was closed under silicone oil (SO) tamponade, the GMT persisted. Human amniotic membrane was used at the second surgery, which ended up with closure of GMT. Retina stayed attached after SO removal.

Keywords: shaken baby syndrome, macular tear, vitreoretinal surgery

[Abstract:0504]

Combined internal limiting membrane and polypropylene monofilament plug for recurrent optic pit maculopathy

Berkant Kaderli
Nev Health Group FSM Hospital

A sixteen-year-old girl presented with decrease of visual acuity (VA) for 2 months in her left eye. Her VA was 2/10 and she was diagnosed with optic pit related macular detachment. The surgery consisted of 23-gauge pars plana vitrectomy with macular internal limiting membrane (ILM) peeling, overlying the ILM on the optic pit and fluid gas exchange. Although the macula reattached and VA improved postoperatively, macular detachment recurred on the fifth postoperative week. Reoperation consisted of insertion of combined ILM and 3 mm-long polypropylene monofilament plug (a part of iris retractor) into the optic pit and fluid gas exchange. The macula reattached and no recurrence was observed during the follow-up period of 6 months. Visual acuity increased to 7/10. No complications were observed.

Conclusion: Combined internal limiting membrane and polypropylene monofilament plug insertion into the optic pit may be an effective intervention for recurrent optic pit maculopathy.

Keywords: Optic pit maculopathy, vitrectomy

[Abstract:0510]

Techniques of lens implantation in the absence of capsular support

Maria Cristina Soare, Karina Spiess, Mostafa A Elgohary
Kingston Hospital NHS Foundation Trust

Intraocular lens implantation in the absence of capsular support can be quite challenging and mastering the different techniques involves a long learning curve.

In this video, we will present examples of the different techniques that we have used over the past 10 years of implanting lenses in cases of primary capsular damage or secondary capsular or zonular damage, i.e. lens subluxation and dislocation. We will present examples of anterior chamber lens implantation, including angle-supported and iris-clipped (Artisan) lenses, scleral suturing and transcleral (Yamané) lens fixation.

We will highlight the main steps, the modifications and tips we found particularly useful, some of the complications and how to avoid them and finally tips for those wishing to learn those techniques.

Keywords: lens implantation, capsular bag, vitrectomy

[Abstract:0515] Macular dragging relief

Filipe Henriques, Luis Bernardes, Telma Machado,
Rosa Pinheiro
Centro Hospitalar e Universitario de Coimbra

Introduction: Familial exudative vitreoretinopathy (FEVR) is a rare genetic disorder which usually manifests during infancy, with variable penetrance and progression across patients. It can be inherited in an autosomal dominant, autosomal recessive, or X-linked recessive. This disease is characterized by abnormal retinal angiogenesis leading to incomplete vascularization of the retina with subsequent ischemia and neovascularization, vitreoretinal traction with distortion of macular architecture, hemorrhages, subretinal exudation and membranes formation. FEVR is also associated with tractional or exudative retinal detachment. Treatment for early stages includes observation and pan-retinal photocoagulation while vitrectomy is reserved for advanced cases.

Methods: We report a case of an 8-year-old child with past medical history of sensorineural hearing loss and unremarkable family history. She was diagnosed with FEVR during neonatal period, which was confirmed by genetic testing (mutation c.175 C>G with homozygous of the TSPAN1 gene) and had funnel retinal detachment in the right eye since infancy, with no light perception. The child presented to emergency department with acute vision loss of the left eye (best corrected visual acuity of 1/10). Fundus examination showed a dense fibrovascular macular proliferation with consequent distortion of retinal architecture in the presence of attached retina.

Results: Pars plana vitrectomy 25 gauge was performed with mechanical detachment of the posterior hyaloid, delamination and peeling of fibrovascular proliferation in posterior pole under perfluorocarbon liquid. Diathermy of bleeding retinal vessels and 360-degree endolaser were also used, followed by fluid-air exchange and sclerotomies closure with absorbable sutures.

At one-month postoperative follow-up, visual acuity was maintained (1/10) with substantial improvement of macular anatomy. No complications were recorded.

Conclusion: Pars plana vitrectomy with mechanical peeling of membranes and areas of proliferation could be a valuable therapeutic approach in cases of FEVR.

Keywords: macular dragging, familial exudative vitreoretinopathy

[Abstract:0519] Chandelier-Assisted Scleral Buckling with Illuminated Endolaser Retinopexy-A Different Option

Nur Acar Gocgil
NUR ACAR GOCGİL, Prof, FEBO, Neoretina Eye Clinic, Istanbul, Turkey

The scleral buckling (SB) technique, can be an ideal treatment for younger and phakic patients with rhegmatogenous retinal detachment (RRD). However, the use of SB has been decreasing throughout decades possibly due to the inconvenience of utilizing the indirect ophthalmoscope throughout the procedure, the inability to share findings with people in the operating room, and the increasing popularity of pars plana vitrectomy (PPV).

SB has significantly lower costs, and is effective in young, phakic eyes with RRD. The SB technique preserves the vitreous body, avoids cataract development compared to PPV. However, it has a steep learning curve, and rates of complications can increase with decreased experience of the technique.

There have been increasing efforts to make SB a more convenient procedure, with most of the innovations focusing on easier and better visualization of the retina with the use of wide-angle fundus viewing system in combination with a chandelier illumination during SB surgery. This way upright, panoramic, detailed view of the retina with wide-angle viewing system is achieved during SB, making it a more visual, and controlled technique for the surgeon. Better imaging for fellows, nurses, observers in the OR is very essential for teaching of the technique.

In this video, 2 CASB surgeries in young, phakic eyes with RRD are shown to reattach the retina.

As a different approach for retinopexy, the curved illuminated endolaser is used which enabled direct and easy viewing of all retinal pathologies, and treating all retinal tears and degenerations directly as in PPV with self indentation of the surgeon in a controlled way. the movement inside the vitreous is very slow, the sclerotomy must be cleared from all vitreous and sutured. Retinas remained attached during 1 year follow-up without any complication.

Keywords: rhegmatogenous retinal detachment, scleral buckle, illuminated endolaser photocoagulation

[Abstract:0525]**Temporary PFCL tamponade for for endoresection of choroidal melanoma**Hany Hamza*Kasr Al Any School of Medicine Cairo University Egypt*

The endoresection of choroidal melanoma, a vital surgical technique for select cases unsuitable for brachytherapy, must not be taken lightly. Following Gamma knife irradiation of the tumor, a PFCL/air exchange is contraindicated due to the risk of fatal air embolism. During surgery, a critical step involves a direct exchange of PFCL/silicone oil, which can prove difficult due to hypotony and bleeding. Furthermore, blood in the area of resection increases the likelihood of PVR.

To mitigate these risks, it is crucial to emphasize the importance of temporary PFCL tamponade. By leaving PFCL in the eye for three days, any blood in the surgical bed can be kept at bay, enabling a safe fluid/air exchange to take place. At this point, the choroidal vessels will have closed in the surgical bed, paving the way for safe silicone oil injection. Thus, temporary PFCL tamponade can be a key component of this surgical technique.

Keywords: Endoresection, Melanoma, PFCL

[Abstract:0557]**Drop It Like It's Hot**Matteo Forlini*Department of Ophthalmology, San Marino State Hospital, Republic of San Marino*

In this challenging case, two IOLs dropped in the vitreous chamber (one-piece-foldable-IOL and a ICL too), so after difficult maneuvers to remove the two IOLs from vitreous chamber through anterior chamber, Iris-Claw IOL was finally implanted with retropupillary enclavation.

Keywords: Two Dropped IOLs, Posterior IOLs Luxation, Secondary IOL Implantation

[Abstract:0558]**Autologous retina transplant for a huge traumatic macular hole**Jayanto Shekhar Guha*SRF Eye Hospital, New Delhi, India*

A young female patient aged 12 years presented to us with a huge chronic traumatic macular hole with hand movement vision.

Autologous retina transplant is one of the options for repair of a huge macular hole which usually does not respond to conventional approaches. In this video I have described a technique in which a free flap of autologous neuro-sensory retina is harvested and positioned over the macular hole (more than 1800 μ) to serve as a plug and scaffold for glial cell proliferation.

Among the innovative techniques shown in this video such as, extent of ILM staining, I have also used Healon and tucking as one of the adjunctive steps to ensure stability of the transplant.

At approximately 10 months of follow-up the hole is closed and 2 lines of visual gain has been observed.

Keywords: autologous retina transplant, 40G subretinal cannula

[Abstract:0578]**Amnion Membrane Transplantation: An Impossible Case**Şengül Özdek*Gazi University, Ankara Turkey*

Transplantation of human amniotic membrane (hAM) has been gaining popularity for the repair of recurrent macular holes or posterior pole breaks where other measures fail, such as in eyes with pathological myopia. In this case of pathological myopia, the patient had schizophrenia and lost light perception in the fellow eye after multiple operations. The patient presented with retinal detachment associated with a large macular hole and four large retinal breaks at the posterior pole. The axial length was 35 mm. A pars plana vitrectomy combined with phacoemulsification was applied and two hAM grafts were placed over the hole and breaks and tamponaded with silicone oil. Two years after silicone oil removal, the retina remained attached and the vision at the level of hand movements could be preserved.

Keywords: Amnion Membrane Transplantation

POSTER PRESENTATIONS

[Abstract:0105]**Role of autologous platelet rich plasma in patients of retinitis pigmentosa**

Muhammad Irfan Karamat¹, Muhammad Shahzad Anwar²,
Muhammad Zaigham Abbas², Muhammad Asim Mahboob³
¹ibrahim eye center

²iffa anwar hospital

³armed forces institute of ophthalmology

Purpose: The aim of this study is to determine SAFETY and EFFICACY of PLATLET RICH PLASMA administered through sub-tenon space on visual functions in retinitis pigmentosa patients by reactivating the degenerated photoreceptors in dormant phase.

Methods: A pilot study was designed in order to determine safety and efficacy of autologous PLATLET RICH PLASMA in patients of Retinitis Pigmentosa. 20 patients including 17 male and 3 female included in the study. Base line Visual acuity, Oct for macular thickness on OCT and Visual Field was performed. Patients were given aPRP (platelet rich plasma) in sub tenon space three times with a gap of 15 days. A follow up of 6 weeks, 12 weeks and 24 weeks was planned.

Results: Initial results are encouraging. There is improvement in VISUAL ACUITY AND VISUAL FIELDS and macular thickness. No adverse effects, short term complications or adverse patients symptoms were documented during the procedure. We are still collecting data and will comprise the final results in few months.

Conclusion: Stem cell therapy is safe and its short term effects are encouraging, however we should further plan trials in order to prove its efficacy in retinal degenerative conditions.

Keywords: autologous platelet rich plasma, retinitis pigmentosa, sub tenon

[Abstract:0112]**Role of the Brain-Sparing Effect in Retinopathy of Prematurity in Growth Restricted Fetuses**

Osman Ahmet Polat¹, Mehmet Meter Kırılancı³, Erdem Şahin²,
Yusuf Madendağ², Cagatay Karaca¹, Fatih Horozoglu¹
¹Erciyes University, Faculty of Medicine, Department of Ophthalmology, Kayseri/TURKEY

²Erciyes University, Faculty of Medicine, Department of Obstetrics and Gynecology, Kayseri/TURKEY

³Kartal Dr. Lutfi Kırdar City Hospital, Department of Obstetrics and Gynecology, Istanbul, Turkey

Purpose: This study aimed to appreciate the role of the brain-sparing effect (BSE) in fetal growth restriction (FGR) on retinopathy of prematurity (ROP).

Methods: In this retrospective single-center study, 127 pregnant women were divided into two groups considering the cerebroplacental ratio (CPR): the early FGR with abnormal CPR group (n=74) and the appropriate for gestational age with normal Doppler group (n=53). CPR was computed using the

pulsatility index (PI) and resistance index (RI) to quantitate the waveforms [middle cerebral artery (MCA) PI/umbilical artery (UA) PI and MCA RI/UA RI: a result <1 was taken into account as abnormal]. ROP screening results of newborns were recorded from electronic files.

Results: After adjusting for co-variants, BES was not related to ROP (adjusted odds ratio [aOR], 1.06; 95% confidence interval [CI], 0.23–4.95). Gestational age at delivery <30 weeks (aOR, 2.55; 95% CI, 1.04–6.93) and birth weight <1500 g (aOR, 5.15; 95% CI, 1.15–25.2) were independently associated with ROP. The existence of preeclampsia (aOR, 1.28; 95% CI, 0.47–2.37), emergency cesarean section birth (aOR, 1.09; 95% CI, 0.43–2.80), or forty-eight hours completion after the first steroid administration (aOR, 3.80; 95% CI, 0.96–14.9) were not associated with ROP.

Conclusion: The BES in FGR was not a significant independent risk factor for ROP. Gestational age at delivery <30 weeks and birth weight <1500 g were independent risk factors for ROP. The presence of preeclampsia, emergency cesarean delivery, vaginal delivery, or forty-eight hours completion after the first steroid administration were not independent risk factors.

Keywords: Brain-sparing effect, Cerebroplacental ratio, Retinopathy of prematurity

[Abstract:0121]**Deep orbital infantile hemangioma diagnosed during follow-up for retinopathy of prematurity**

Tülin Öğreden, Akasya Şaipii, Faruk Kaya
Medipol University Hospital, Istanbul

The case who was born at 25 gestational weeks (GW) and 600 grams was followed for retinopathy of prematurity (ROP). Aggressive ROP diagnosed at 39th GW. Bilateral intravitreal anti-VGF injection was administered at 40 weeks. It was noticed that the right eyelid space narrowing in this period (figure 1).

Initially, transient ptosis or hematoma caused by eyelid speculum was considered. Moderate right ptosis and grey-purple, palpable lumpy deep mass were detected in the superonasal orbital area, which gradually increased after 41 weeks. B-mode ultrasound was revealed a high peak lesion with hyperechoic and irregular vascular flow.

Axial length was 18.32 on right and 17.24 mm on left. The central cornea was thicker in the right eye (561.6 vs 518 micron).

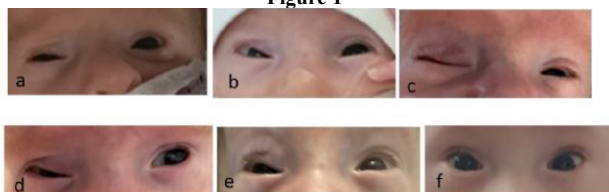
The orbital MRI was consistent with hemangioma. A soft tissue mass was detected on intraorbital extraconal region with smooth borders, slightly lobulated, hyperintense on T2W and hypointense on T1W images. Homogeneous signal void areas of vascular structures were observed. Dimensions were 6x11 mm on axial plane and 8 mm on craniocaudal (figure 2 and 3). Oral 1 mg/kg/day propranolol was started and continued at

0.5mg/kg/day. With the treatment started at 43rd GW, almost complete recovery was achieved at 61th weeks (figure 1).

Infantile hemangioma is the most common periocular tumor of childhood. Although most hemangiomas spontaneously regress, treatment is indicated on risk to organ development and function. Propranolol, a non-selective β -adrenergic receptor blocker, is first-line therapy. One of the mechanisms of action of propranolol is the blockade of vascular endothelial growth factor receptor 2 (VEGF-2) and has therefore been studied in the preventive treatment of ROP. Orbital deep hemangiomas may be discovered incidentally during screening for ROP, may be confused with a complication associated with the examination, and there may be delays in diagnosis. Its treatment with systemic beta-blockers is compatible with ROP treatment, and it is an effective treatment when used in the appropriate dose and duration.

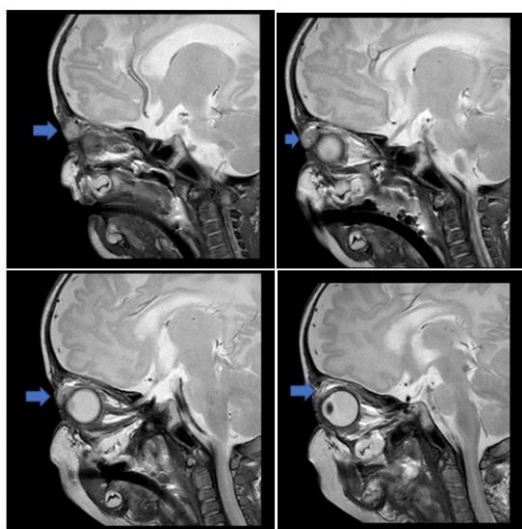
Keywords: Infantile hemangioma, retinopathy of prematurity, systemic propranolol therapy

Figure 1



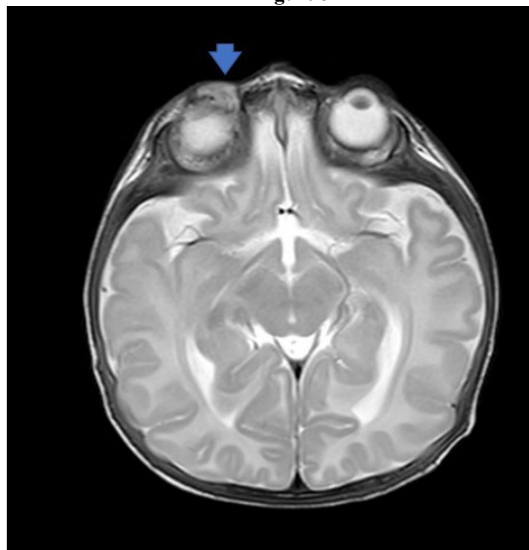
Eyelids appearance before propranolol therapy at a-39th GW, b-40th GW, c-42nd GW. Eyelids appearance during propranolol therapy at d- 48th GW, e-50th GW, f-61st GW

Figure 2



Sequential sagittal orbital MRI images, blue arrows indicate the location and extent of the mass.

Figure 3



In the axial orbital MRI section the blue arrow shows the location and extent of the mass.

[Abstract:0131]

Case report: self - regression of local retinal detachment in Aggressive retinopathy of prematurity

Dinara Saukenova, Alfiya Gabaidulina, Zhansaya Baigabyl
Corporate Fund «University Medical Center» National Research Center
for Maternal and Child Health, Astana, Kazakhstan.

Introduction: Retinopathy of Prematurity (ROP) is one of the leading, yet largely preventable causes of childhood blindness in the worldwide.

In Kazakhstan more than 21,000 premature babies are born per year, including 19% of children weighing up to 1,000 grams. On average, 2,000 premature babies are born in Astana, of which 22% are children weighing less than 1,500 grams. According to statistics 38 % of premature babies develop ROP in Kazakhstan.

Case Report: The child was born in Kazakhstan, gestational age 29 weeks, weight 1100 g, the second of twins, Apgar score 5-6/7 points. IVF-induced pregnancy.

At 32-33 weeks postconceptual age, the child was diagnosed with Aggressive retinopathy of prematurity. The child received Anti-VEGF therapy with ranibizumab 0.2 mg. After intravitreal administration of angiogenesis inhibitors, vascular activity decreased, but vascularization was only within 1 zone. (photo 1) After 6 weeks (at 39 weeks of postconceptual age), the child was diagnosed reactivation of ROP. In the fundus, there is pronounced tortuosity of vessels in all 4 quadrants, multiple arteriovenous shunts and retinal hemorrhages, a demarcation ridge with pronounced proliferation. (photo 2) Re-introduction of Anti-VEGF therapy (ranibizumab) was carried out, but there was no complete regression. 10 days after Anti-VEGF therapy, lasercoagulation of the retina was performed. On examination

the next day revealed a local retinal detachment in the form of a bubble on the border with laser coagulation from the temporal half.(photo 3)

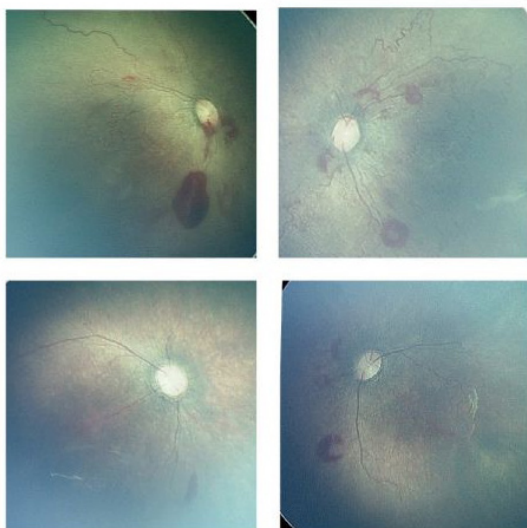
However, the child's hemodynamic disturbances are growing against the background of an open aortic duct of large diameter, and a decision was made to clip the open aortic duct (the child was transferred for surgical treatment on the heart). When examining the eyes on the 10th day after laser coagulation, there is no local detachment, coagulates are pigmented, and vascular activity in dynamics has significantly decreased. (photo 3)

After clipping of the aortic duct, oxygen dependence disappeared, and the general condition of the child improved.

After 1 month, the dynamics are stable, the retina is not detached throughout

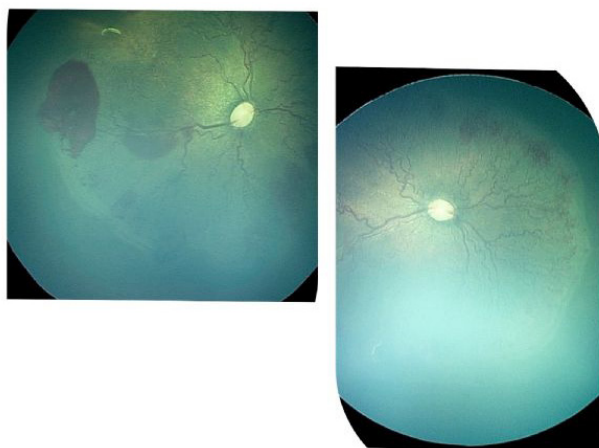
Keywords: ROP, local retinal detachment

Photo 1




condition before/after the first use of Anti-VEGF therapy

Photo 2



ROP reactivation 6 weeks after Anti-VEGF therapy

Photo 3



local retinal detachment on the 1st day after the operation / no retinal detachment on the 10th day after the operation

[Abstract:0136]

A case of immediate resolution of pigment epithelial detachment with one injection of faricimab-svoa

Yigit C Akduman, Niloofar Piri

Department of Ophthalmology, Saint Louis University School of Medicine, Saint Louis, USA

Purpose: To present a case of immediate resolution of pigment epithelial detachment (PED) secondary to exudative age-related macular degeneration (AMD) with one injection of faricimab-svoa.

Methods: 84-year-old patient with exudative AMD presented with a PED/choroidal neovascular membrane (CNVM) complex in his right eye. Because the efficacy of anti-vascular endothelial growth factor (anti-VEGF) alone is known to be limited on PEDs, we elected to use intravitreal faricimab-svoa, a recently FDA approved combined anti-VEGF and angiopoietin-2 (Ang-2) inhibitor agent as initial treatment. The fundus photograph and OCT prior to faricimab-svoa and at four weeks follow up are presented.

Results: The eye had best corrected visual acuity (BCVA) of 20/80 but a large PED had caused hyperopic shift decreasing the visual acuity to 20/200 with current glasses at initial presentation. Figure 1a and figure 1b show the color photo and OCT respectively prior to faricimab-svoa injection. The BCVA improved to 20/50 at four weeks with current glasses after faricimab-svoa with near total collapse and resolution of the PED with mild subretinal fluid still present subfoveally (Figure 2). Hyperopic shift was resolved.

Conclusion: PEDs are notoriously resistant to intravitreal injections of anti-VEGF agents at least partly due to

injected agents not being able to penetrate through the relatively intact nature of the retinal pigment epithelium (RPE)/Bruch's membrane in PEDs to regress the CNVM or choroidal polypoidal vasculopathy (CPV) lesions located in deeper layers. The immediate collapse/regression of the PED/CNVM complex seen in this case was remarkable and seems to justify further investigation of faricimab-svoa on exudative AMD cases with PED/CNVM complex or in those with CPV lesions. One possible explanation for the observed prompt effect of faricimab-svoa could be better efficacy of the angiopoietin-2 inhibitor on the PED/CNVM complex. This needs to be studied further in future prospective studies with larger number of cases.

Keywords: age-related macular degeneration (AMD), pigment epithelial detachment (PED), faricimab-svoa

Figure 1a

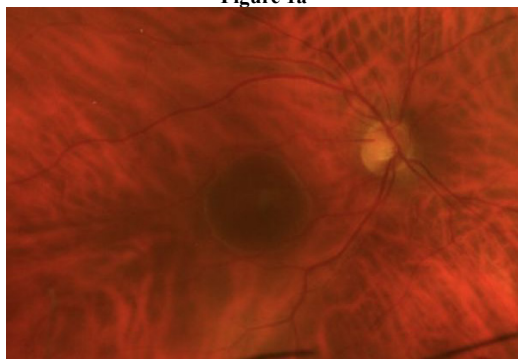

Figure 1a. Color fundus photograph showing the area of the PED.

Figure 1b

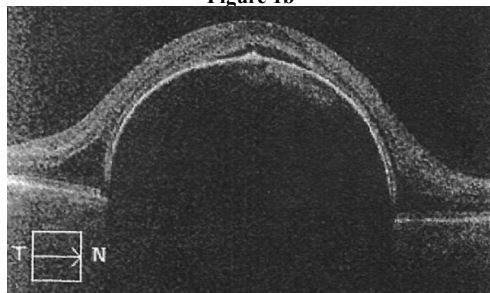


Figure 1b. OCT scan showing a remarkably large PED associated with exudative age-related macular degeneration.

Figure 2

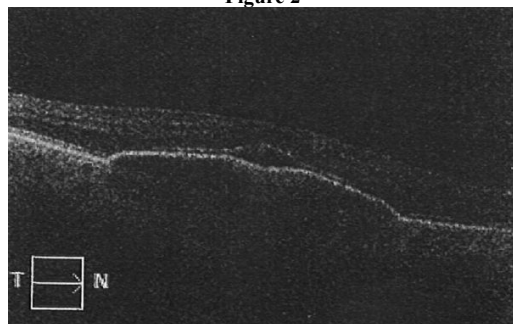


Figure 2. The OCT scan four weeks after the faricimab-svoa injection shows a surprisingly noticeable collapse and regression of the PED. Small amount of subretinal fluid still present subfoveally.

[Abstract:0155]

Association of Serum Apolipoprotein with Changes in Central Retinal Thickness, Fovea Avascular Zone, Vessel Density, and Perfusion Density of the Retina in Patients with Diabetic Macular Edema

Soefiandi Soedarman¹, Madarina Julia³,
Tjahjono D Gondhowiardjo¹, Albertus Donny Budi Prasetya¹,
King Hans Kurnia¹, Muhammad Bayu Sasongko²

¹JEC Eye Hospitals & Clinics, Jakarta, Indonesia

²Department of Ophthalmology, Faculty of Medicine, Public Health, and Nursing, Universitas Gadjah Mada, Yogyakarta, Indonesia

³Department of Paediatrics and Child Health, Faculty of Medicine, Public Health, and Nursing, Universitas Gadjah Mada, Yogyakarta, Indonesia

Purpose: This study aimed to investigate the associations between serum apolipoprotein A1 (ApoA1) and B (ApoB) levels with changes in the retina and its vessels through optical coherence tomography (OCT) and OCT angiography at the 6-month follow-up in patients with diabetic macular edema.

Design: A prospective cohort study Subjects, Participants, and/or Controls: Two treatment-naïve eyes of 38 patients with diabetic retinopathy, aged ≥ 30 years.

Methods: The presence and progressivity of DME were assessed. Clinical eye examination, color fundus photography, spectral-domain OCT, and OCT angiography, as well as blood chemistry sampling (including ApoA1, ApoB, and serum cholesterol levels) were evaluated at baseline and 6-months follow-up. Study participants received therapy as indicated.

Main Outcome Measures: Through OCT and OCT angiography, the associations between serum levels of Apo with the changes in central retinal thickness (CRT), fovea avascular zone (FAZ), vessel density, and perfusion density of the retina in patients with DME were evaluated.

Results: A significant association was found between ApoB > 122.5 mg/dL with increased CRT, FAZ expansion, and decreased perfusion density in patients with DME ($p = 0.026$, 0.046 , and 0.025 respectively) at the 6-month follow-up. However, the association between ApoB > 122.5 mg/dL and changes in vessel density was only marginally significant ($p = 0.076$). In patients with DME, the Apo B/A1 ratio of > 0.85 was also significantly related to decreased perfusion density ($p = 0.011$), but only had a marginal significance with vessel density ($p = 0.09$).

Conclusion: High ApoB levels and Apo B/A1 ratio may be negative predictor markers of macular and retinal vascularization changes in patients with DME, such as increased CRT, FAZ expansion, decreased perfusion density, and decreased vessel density, which indicates worsening of macular ischemia in progressive DME. ApoB is closely related to retinal vascular parameters.

Keywords: Diabetic macular edema, serum apolipoprotein, Optical coherence tomography

[Abstract:0164]**Endogenous Klebsiella pneumoniae Panophthalmitis with Perinephric and Psoas Abscesses in a 42-year-old Diabetic Female**

Charmaine Grace Malabanan Cabebe,

Maria Angelica Villano Torres

Department of Ophthalmology, Southern Philippines Medical Center, Davao City, Philippines

Purpose: To present a rare case of Endogenous Panophthalmitis with K. pneumoniae bacteremia, associated with perinephric and psoas abscesses in a patient with uncontrolled diabetes mellitus type 2.

Case: An adult diabetic female with a 2-week history of sudden onset blurring of vision of the right eye associated with left flank pain, no history of trauma, sought consult in our institution. On presentation, visual acuity was no light perception. Examination revealed an edematous, erythematous, proptotic right eye with severely restricted extraocular movements. Anterior segment exam revealed diffuse conjunctival injection, mucoid discharge, diffuse corneal edema, and extensive fibrin in the anterior chamber. Dilated exam was limited due to the anterior segment findings. Intraocular pressure was elevated to 42 mmHg. Ophthalmic ultrasonography revealed vitritis with choroidal thickening.

Vitreous tap with intravitreal injection of antibiotics were done. Intravenous and topical antibiotics with oral acetazolamide were given. Pars plana vitrectomy was deferred due to the fulminant course of the disease.

Vitreous cultures revealed growth of Klebsiella pneumoniae while urine culture showed growth of Klebsiella pneumoniae and Staphylococcus.

Imaging revealed bilateral pyelonephritis with left perinephric and psoas abscesses having an approximate volume of 73 ml. Percutaneous drainage was done with marked decrease in abscess on repeat scan. Patient was discharged with resolution of eye pain and swelling. Left eye was phthisical with no light perception.

Conclusion: Endogenous endophthalmitis is a rare condition which can result to blinding complications. Hence patients with immunocompromising conditions and bacteremia should be clinically monitored for hematogenous spread. This implies that a good clinical eye with high index of suspicion and prompt intervention would result in good visual prognosis and better quality of life.

Keywords: Endogenous, Endophthalmitis, Diabetes

[Abstract:0168]**Amniotic membrane graft for the large refractory macular hole**

Hussain Khaqan

PGMI, AMC, LGH, Lahore

Purpose: Study off-label human amniotic membrane (hAM) use outcomes for giant refractory macular hole closure.

Methods: The study was performed at Lahore General Hospital, Lahore, over 52 months on patients who had undergone standard MHs surgical procedures for treatment, but the hole failed to close. Refractory MHs dimensions ranged from 824 µm to 1568 µm. Before surgery, patients underwent slit-lamp examination, fundus photography, and OCT for macular scan. AMG used in surgery was harvested from a human placenta 24 hours prior. Before AMG application, enough internal limiting membrane peeling was done to ensure perfect fitting and recovery. All holes were plugged with AMG and SF6 gas tamponade.

Results: 29 patients, 20 male and 9 female, were included in this study. Mean age of patients was 58±6. Patients had refractory holes of average 1237.48±151.25 µm. Post-op, 100% MH closure was achieved in all patients. Type 1 closure was found in patients (37.93%) who underwent AMG surgery within 3 months after primary surgical failure. Type 2 closure was found in patients (62.07%) who were operated on 3 months after primary surgical failure.

Conclusion: Refractory MHs treated by AMG with SF6 gas tamponade achieve anatomical type 1 closure if performed within 3 months of primary surgical repair.

Keywords: Amniotic Membrane Graft, Refractory Macular Hole

[Abstract:0176]**Treat-and-Extend–Based Personalized Treatment Interval (PTI) Dynamics in the YOSEMITE/RHINE Trials of Faricimab in DME**Sibel Demirel¹, Glenn J. Jaffe², Bianca S. Gerendas³, Francis Abreu⁴, Nitin Jain⁵¹Department of Ophthalmology, Ankara University School of Medicine, Ankara, Türkiye²Duke Reading Center, Duke University, Durham, NC³Vienna Reading Center, Medical University of Vienna, Vienna, Austria⁴Genentech, Inc., South San Francisco, CA⁵Roche Products Ltd., Welwyn Garden City, UK

Purpose: To test the durability of faricimab (FAR) in diabetic macular edema (DME) using a treat-and-extend–based PTI dosing regimen. The treat-and-extend–based PTI regimen in the phase 3 YOSEMITE/RHINE trials was designed to evaluate the durability of FAR in patients with DME. Data from the FAR PTI arms showed that most patients were able to achieve and maintain extended dosing intervals of up to Q16W

over 2 years. Case studies and images show that PTI dosing was effectively used to optimize FAR treatment intervals according to the heterogeneous needs of patients with DME

Methods: In the phase 3 YOSEMITE/RHINE trials (NCT03622580/NCT03622593), patients were randomized to FAR 6.0 mg every 8 weeks (Q8W), FAR 6.0 mg per PTI (Q4W up to Q16W based on CST and BCVA criteria), or aflibercept (AFL) 2.0 mg Q8W through week 100 (pooled N = 1891).

Results: In the FAR PTI arm, 62% of patients achieved Q16W dosing and 78% achieved \geq Q12W dosing at week 96, while also maintaining comparable vision gains and anatomic improvements versus AFL. Most patients who achieved \geq Q12W dosing at week 52 (79%) maintained \geq Q12W dosing without an interval reduction below Q12W through week 96, while a minority (8.6%) remained on \leq Q8W dosing throughout the 2-year trials. PTI case studies and images will be presented.

Conclusion: Treat-and-extend-based PTI dosing supports the extended durability of dual angiopoietin-2/VEGF-A inhibition with FAR in DME.

Keywords: faricimab, YOSEMITE/RHINE, PTI Dynamics

[Abstract:0201]

Impact of Valsalva Maneuver on Choroidal Vascularity Index, Central Choroid and Central Macula

Mustafa Berhuni, Gizem Gürbostan Soysal, Nesime Setge Tiskaoğlu, Zeynep Özer Özcan
Dr Ersin Arslan Eğitim ve Araştırma Hastanesi, Göz Hastalıkları Kliniği, Gaziantep

Background: Evaluation of the effects of the Valsalva maneuver on choroidal vascularity index, central choroid and the central macula.

Methods: Eighty-four eyes of 42 healthy volunteers were evaluated in this prospective study. The central macular layer was assessed using the retinal map mode of the spectral domain OCT (Optovue RTVue XR, Optovue Inc., Fremont, CA), OCT images taken in the Enhanced Deep Imaging mode were transferred to the Image J program and the choroidal vascularity index and subfoveal choroidal thickness measurements were calculated.

Results: The mean age of volunteers was 35.4 ± 7.2 years. Choroidal vascularity index, subfoveal choroidal thickness, central macular thickness and intraocular pressure measurements in the resting position were $67.99 \pm 2.1\%$, $337.73 \pm 12.8 \mu\text{m}$, $232.04 \pm 8.4 \mu\text{m}$, $14.04 \pm 2.5 \text{ mmHg}$ respectively, during Valsalva maneuver were $69.44 \pm 2.1\%$, $351.15 \pm 12.2 \mu\text{m}$, $238.84 \pm 8.1 \mu\text{m}$, $19.4 \pm 5.4 \text{ mmHg}$ respectively. There was a statistically significant increase during valsalva maneuver.

Conclusion: The valsalva maneuver may cause temporary changes in choroidal vascularity index, subfoveal choroidal

thickness, central macular thickness and intraocular pressure. These measurements may be misinterpreted in situations where patients breath-hold inadvertently causing the Valsalva maneuver

Keywords: valsalva maneuver, choroidal vascularity index, choroidal thickness

[Abstract:0205]

The Effect of Early Vitrectomy Surgery on Visual and Anatomical Success in a Case with Intraocular Rusty Metallic Foreign Body

Semra Tiryaki Demir, Turgay Uçak, Mehmet Egemen Karataş, Fatih Kerem Dedeli
Department of Ophthalmology, Sisli Hamidiye Etfal Training and Research Hospital, University of Health Sciences, Istanbul, Turkey

Purpose: To report the effect of early vitrectomy surgery on visual and anatomical success in a case with a large rusty metallic foreign body (FB) in the eye.

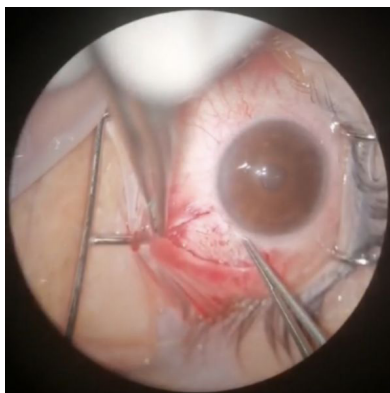
Methods: A 38-year-old male patient was admitted to our clinic at the weekend with the complaint of metallic FB in the left eye as a result of a work accident a few hours ago. The patient's left eye visual acuity was 20/20. Intraocular pressure was 21 mmHg in the left eye. Biomicroscopic examination revealed a Zone 2 penetrating injury in the left eye, a linear scleral incision starting from 1 mm to the limbus at 5 o'clock and extending to 3 mm, and a 1+ reaction in the anterior chamber. Fundus examination revealed a long metallic FB attached to the retina in the temporal quadrant of the left eye, retinal/subretinal hemorrhage around the FB and condensation in the vitreous. In orbital CT, high-density FB of approximately 13 mm in length was detected in the left eye.

Results: The patient underwent left eye lens-protected vitrectomy, removal of intraocular metallic rusty FB, laser photocoagulation, silicone oil injection, intravitreal injection of vancomycin and ceftazidime 1 day later. In the ophthalmic examination performed 3 months after the first surgery; His left eye visual acuity was 20/50, and slit-lamp examination revealed a traumatic cataract in the left eye. The patient underwent left eye cataract surgery and silicone oil removal operation. In the 6th month post-traumatic follow-up examination of the patient; left eye visual acuity of 20/20, left IOP 15 mmHg, left pseudophakia in biomicroscopic examination, and retinal attachment in the left eye were observed in fundus examination.

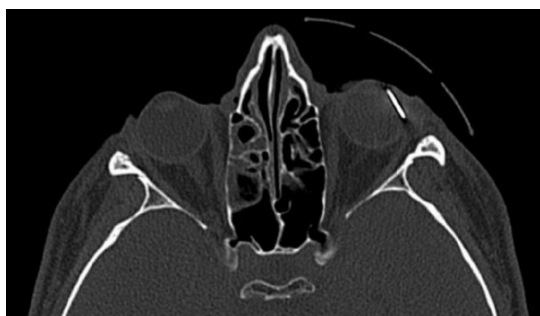Conclusion: Early vitrectomy surgery before endophthalmitis may have a high contribution to visual and anatomical success in cases with large, rusty, metallic intraocular FB.

Keywords: Intraocular metallic foreign body, early vitrectomy, ocular trauma

Anterior segment photograph of the patient. Zone 2 penetrating eye injury in the left eye.



The presence of a high-density intraocular foreign body 13 mm in length in the left eye of the patient on orbital CT imaging.



[Abstract:0210]

Solitary Choroidal Granuloma with Central Serous Chorioretinopathy

Şerife Çiloğlu Hayat, Yusuf Cem Yılmaz, Serhat Ermiş, Murat Karapapak, Ece Özal, Hakan Baybora, Sadık Altan Özal
Basaksehir Cam ve Sakura City Hospital, Ophthalmology, Istanbul, Turkey

A 34-year-old male patient presented with blurred vision in the left eye. He had been suffering from sarcoidosis for three years, however, the treatment had not started. The best corrected visual acuity (BCVA) was 1.0 and 0.2 in the right and left eyes, respectively. Bilateral anterior segment examination was normal. Intraocular pressure was normal. On fundus examination, there was an orange elevating mass located in the posterior pole and accompanying subretinal fluid in the left eye. The right fundus was normal. Optical coherence tomography (OCT) of the patient's left eye showed subretinal fluid in the left eye, and a choroidal solitary mass in enhanced depth imaging optical coherence tomography (EDI-OCT). Fundus fluorescein angiography of the left eye revealed hyperfluorescent leaking foci within the fovea and inferior temporal vascular arch in the left eye, and solitary hypocyaneosence localized in the posterior pole in indocyanine green angiography. The patient was diagnosed with choroidal granuloma due to sarcoidosis with the initial findings. The patient was started on Methotrexate 15 mg/

week/subcutaneously (sc), methylprednisolone 32 mg and lansoprazole. Although the patient's left visual acuity increased to 0.5 in two weeks, subretinal fluid consistent with central serous chorioretinopathy was found in the right eye. Steroid treatment was discontinued. Adalimumab 40mg/2 weeks/sc treatment was added to his treatment. Three months after admission, the patient's visual acuities were 1.0/1.0 in his both eyes. Choroidal granuloma in the left eye completely regressed with treatment, and there was no evidence of active central serous chorioretinopathy in the right and left eyes.

Keywords: Choroidal granuloma, Sarcoidosis, CSCR

[Abstract:0223]

Bilateral internal limiting membrane detachment and papilledema as a complication of brain metastasis secondary to Wilm's tumor

Dilek Güven, Özgül Altıntaş
Acibadem Maslak Hospital, Department of Ophthalmology, Istanbul, Türkiye

Case: A seven-year-old African female patient who had received tumor resection, chemotherapy(CT) and radiotherapy(RT) for Ewing sarcoma of left thigh encountered a hemorrhagic stroke. She had left facial paralysis, pupil anisocoria and strabismus. Cranial MR revealed a metastatic lesion with hemorrhage causing pressure on mesencephalon, shift and uncal herniation. Tumor excision from right parietooccipital area was performed, after which she received CT, steroid treatment and RT for the tumor cavity in the brain.

Ophthalmological consultation on the postoperative(PO) first week revealed; visual acuity of 0.5 OD, light perception/projection OS, afferent pupillary defect OS, binocular restriction of horizontal eye movement and right hypotropia. Fundus examination disclosed Grade 4 papilledema, engorgement of vessels, macular ILM detachment extending towards the optic disc with inferior limited sub-ILM hemorrhage and stress lines around the macula. OCT showed bilateral flat foveal contour, ILM detachment surrounded with a ring-shaped retinal elevation and intraretinal hyperreflective dots consistent with hard exudates. On the left eye due to the traction there was subretinal fluid(SRF) under the retinal folds. There was no vitreous traction or posterior hyaloid detachment. The findings were exaggerated on the left side with a greater area and height.

On PO-3 weeks visual acuity was 0.5-0.6 OD and no light perception OS, with afferent pupillary defect. Left eye was deviated to nasal and superior position. On PO-9 weeks, visual acuity was 0.4 OD and 0.05 OS. There was pallor of the optic discs with resolution of papilledema. OCT showed a decrease of ILM detachment height, partial resolution of sub-ILM hemorrhage and SRF with hyperreflective sub-ILM deposits.

Here we represented initial and follow-up findings of a different case of ILM detachment and sub-ILM hemorrhage other than reported causes as Valsalva maneuver, stent-assisted

coil embolisation, shaken baby syndrome, Terson syndrome, ruptured macroaneurysm and severe anemia.

Keywords: ILM detachment, papilledema, OCT

[Abstract:0232]

Retinochoroidal Morphological Alterations in Rheumatoid Arthritis: An Optical Coherence Tomography Angiography Analysis

Muberra Akdogan¹, Mustafa Dogan¹, Hamidu Hamisi Gobeka¹, Merve Simsek², Mehmet Cem Sabaner³, Ozgur Eroglu¹, Adem Erturk⁴

¹Afyonkarahisar Health Sciences University, Faculty of Medicine, Department of Ophthalmology, Afyonkarahisar/TURKEY

²Muğla Sıtkı Kocman University, Department Faculty of Medicine Department of Ophthalmology, Mugla/TURKEY

³Bafra State Hospital Eye Clinic, Bafra, Samsun/Turkey

⁴Afyonkarahisar Health Sciences University, Faculty of Medicine, Department of Internal Medicine Rheumatology Clinic, Afyonkarahisar/TURKEY

Purpose: To investigate retinochoroidal morphological alterations in patients with rheumatoid arthritis (RA) using optical coherence tomography angiography (OCTA)

Methods: This prospective cross-sectional analysis included 32 eyes of 32 RA patients and 22 eyes of 22 average subjects. Following a comprehensive ophthalmologic examination, retinal microvascular parameters including; deep vascular plexus vessel density, foveal avascular zone (FAZ) area, FAZ perimeter (PERIM) and 300 µm FAZ width (FD-300) were measured using OCTA.

Results: Deep vascular plexus vessel density in the foveal region and FD-300 was statistically significantly lower in RA patients relative to normal subjects (P: 0.002 and P: 0.001, respectively). However, RA patients were associated with significantly higher FAZ and PERIM relative to normal subjects (P: 0.019 and P: 0.007, respectively). No statistically significant variations were observed in the other OCTA parameters.

Conclusion: Alterations in morphology of both retinal and choroid have been demonstrated in RA patients. This finding could be attributed to the systemic involvement of RA in various microvascular systems, including ocular microcirculatory system. OCTA can therefore be used not only in the diagnosis but also in the monitoring of this disease, especially in terms of ocular posterior segment involvement.

Keywords: Optical Coherence Tomography Angiography; Retinochoroidal Morphology; Rheumatoid Arthritis

[Abstract:0233]

Effects of Type 1 Diabetes Mellitus on Inner Retinal Layers and Choroidal Thickness Analyzed by Spectral Domain Optical Coherence Tomography

Gökhan Kaya

Bağcılar Eğitim ve Araştırma Hastanesi, Göz Kliniği, İstanbul

Purpose: To assess the changes in inner retinal layers and choroidal thickness in diabetic patients using spectral domain optical coherence tomography (SD-OCT).

Methods: We examined 50 eyes of 35 diabetic patients with diabetic retinopathy (as Group 1), 60 eyes of 40 diabetic patients without diabetic retinopathy (as Group 2) and 50 eyes of 30 age and sex matched individuals without diabetes (as control group). The thickness of retinal nerve fiber layer (RNFL), ganglion cell layer (GCL), inner plexiform layer (IPL) and choroid measured by SD-OCT.

Results: In Group 1 patients, thickness of RNFL were found to be significantly thinner than other groups in central subfield (p=0.007, p=0.015). In Group 1, thickness of GCL were found to be significantly thinner than Group 2 in all inner fields (p=0.005, p=0.010, p=0.001, p=0.020). In Group 1, thickness of GCL were found to be significantly thinner than control group in central subfield, inner nasal, temporal and superior fields (p=0.015, p=0.001, p=0.015, p=0.015). In Group 1, thickness of IPL were found to be significantly thinner than other groups in inner nasal, temporal and superior fields (p=0.005, p=0.001, p=0.001 and p=0.010, p=0.001, p=0.005). No significant difference was found between groups in terms of choroidal thickness (p>0.05).

Conclusion: In diabetic patients, it was observed that the thickness of the ganglion cell and internal plexiform layer decreased as a result of microvascular and neurodegenerative changes. Although there were no statistically significant differences between the groups, the choroidal thickness tend to be thicker in diabetic patients.

Keywords: Choroidal thickness, diabetes mellitus, retinal thickness

[Abstract:0235]

Evaluation of our clinical results in patients with central retinal artery occlusion

Erdinc Aydin¹, Seda Gurakar Ozcift², Levent Kazancı²

¹Department of Ophthalmology, Izmir Katip Celebi University, Izmir, Turkey

²Eye Clinic, Atatürk Training and Research Hospital, Izmir, Turkey

Purpose: To investigate the results of medical therapy and hyperbaric oxygen therapy in patients with central retinal occlusion (CRAO).

Methods: Twenty-two CRAO cases were reviewed retrospectively. Massage, topical and systemic oral hypotensive treatments, and acetylsalicylic acid were applied to all cases. Eighteen of the cases had received 20 sessions of Hyperbaric Oxygen (HBO) therapy. The mean follow-up period was 15.8 months (4-33). Visual prognosis and complications of the cases were evaluated before and after treatment.

Results: The mean age of the patients was 65 (26-83), the M/F ratio was 6/16, and the right/left eye ratio was 14/8. Homocystinuria was detected in one case (26 years old) under 45 years of age. When the time elapsed between the onset of symptoms and the time of admission in cases with the significant visual increase was examined, it was determined that the application period of 10 cases was within 24 hours, except for 1 case (36 hours). Visual improvement was observed in 11 (61%) of 18 patients who received HBO therapy.

Discussion and Conclusion: Ganglion cell infarction occurs within 15 minutes in full CRAO. The applied medical treatment modalities are not based on conclusive evidence, and HBO therapy is supportive until retinal reperfusion. HBO treatment can be effective in the early period in preventing vision loss in cases with partial obstruction.

Keywords: Central retinal arterial occlusion, hyperbaric oxygen therapy, visual loss

[Abstract:0252]

An acute posterior multifocal placoid pigment epitheliopathy with presumed systemic lupus erythematosus etiology

Omer Othman Abdullah

Ibinsina Modern Eye and Retina Center

In this case report, we describe a patient with acute posterior multifocal placoid pigment epitheliopathy, presumed to be the initial manifestation of systemic lupus erythematosus, who responded to oral immunotherapy. The clinical, hematological, serological, and imaging examinations were carried out on the 28-year-old female who presented with bilateral multifocal central creamy lesions. The imaging modalities' findings and the overall visual improvement led us to diagnose APPMPE. Several distinct ocular symptoms of SLE exist. This is the second time SLE has been presented as APPMPE. immunosuppressive medication greatly ameliorated the disease. Before declaring APPMPE to be idiopathic, we must investigate thoroughly.

Keywords: APPMPE, systemic lupus erythematosus, case report

Figure 1. Colored fundus image showing creamy colored indistinct edged central lesions between arcades (A and). Hypopigmented lesion on FAF (C and D). OCT showed loss of outer retinal layer (E and F).

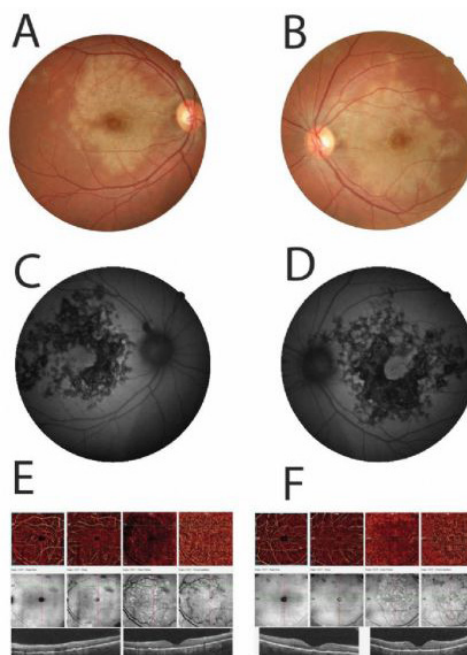
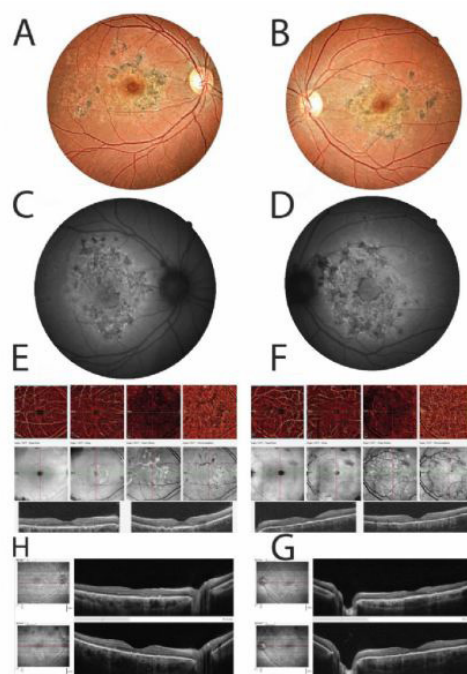


Figure 1. Colored fundus image showing replacing of the old lesion by the hyperpigmentation (A and B). Hyperpigmented lesion on FAF (C and D). OCT showed recovery of outer retinal layer in the macular layer (E and F). Comparison between the old and new lesions (G and H).



[Abstract:0258]

Microvascular and structural analysis for the applicability of idiopathic epiretinal membrane staging system in diabetic epiretinal membrane cases

Umay Güvenç, Güner Üney, Nurten Ünlü, Özlem Candan, Gözde Orman
Sağlık Bilimleri Üniversitesi Ankara SUAM; Göz Hastalıkları Ana Bilim Dalı, Ankara

Purpose: Evaluation of optical coherence tomography(OCT) and OCT-angiography(OCTA) features in diabetic epiretinal membrane(dERM) cases compared with idiopathic ERM(iERM) cases and control group to assess OCT-based staging of dERM patients.

Methods: A total of 136 eyes of diabetic(34), idiopathic(46) ERM patients and controls(60) were analysed. Staging was based on the regularity of foveal contour, presence of ectopic inner foveal layer(EIFL), thickening and layer irregularity of outer retinal layers(ORL). The groups were compared in terms of visual acuity(VA), central foveal thickness(CFT), presence of disorganisation of inner retinal layers(DRILL) and EIFL, thickness of retinal layers, vascular density(VD) and foveal avascular zone(FAZ).

Results: The membrane stages, VA and CFT in both ERM groups were similar ($p=0.23$, $p=0.18$, $p=0.33$) CFT was 342.3, 343 and 228 μm in groups 1, 2 and 3, respectively. The retinal thicknesses(RT) were similar in group 1 and 2 and higher than in group 3. There was no difference between the 2 groups in terms of superficial and deep VD and they are similar in terms of DRILL and EIFL presence($p=0.98$, $p=0.72$)Choriocapillaris flow area was significantly lower in the dERM group compared to the other groups ($p=0.003$, $p=0.00$).In the dERM group, a positive correlation was observed between foveal VD(FVD) and ORT, whereas a positive correlation was seen between superficial FVD and inner RT(IRT) in iERM group.

Discussion: In our study, OCT-based staging developed for iERMs was found to be applicable to dERM cases without retinopathy. Mechanical traction in iERM primarily affects the inner retinal layers and retinal blood flow. In diabetes, choriocapillaris blood flow is reduced and the importance of retinal circulation for the outer retinal layers is increased; therefore, dERM primarily affect the outer layers. In conclusion, although there are changes detectable by OCTA between ERM groups, OCT-based staging system is also valid for dERM cases.

Keywords: Diabetic epiretinal membrane, epiretinal membrane staging, optical coherence tomography

Figure 1

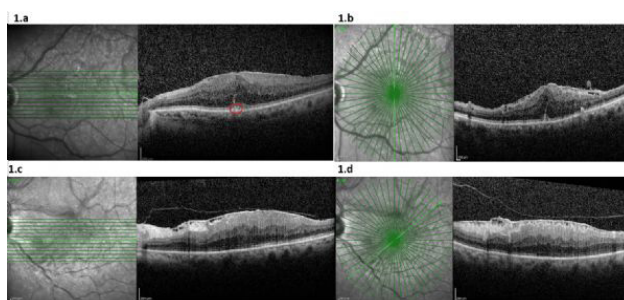


Figure 1: 1.a. Macular OCT section through the foveal centre of the left eye of a patient with idiopathic ERM: diffuse retinal thickening and cottonball (red circle) with loss of the foveal depression, 1.b. Radial section of the same patient, 1.c. Macular OCT section through the foveal centre of the left eye of a patient with diabetic ERM: diffuse retinal thickening with loss of the foveal depression and the presence of DRILL. 1.d. Radial section of the same patient

Figure 2

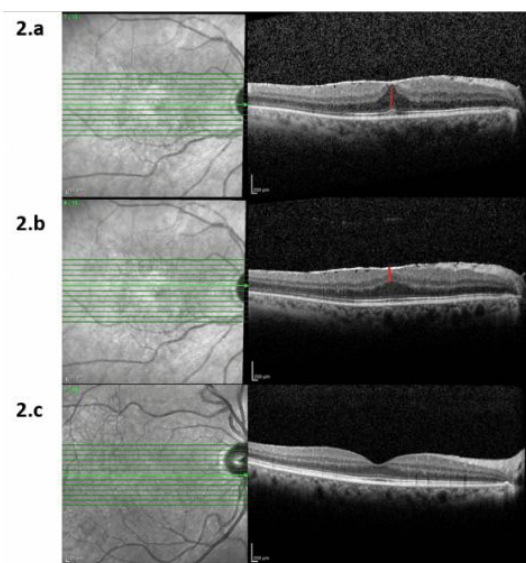


Figure 2: OCT sections through the foveal centre of the right eye, 2.a. Marked thickening of the outer nuclear layer, 2.b. Ectopic inner foveal layer, 2.c. Normal macula with foveal depression

Figure 3

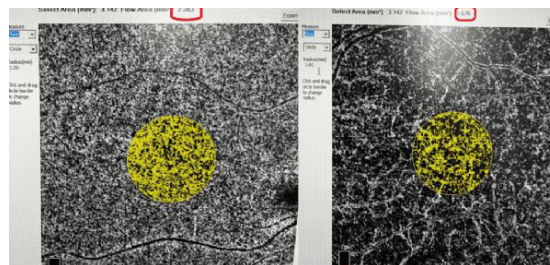

Figure 3. OCTA choriocapillaris flow area measurements: first picture is of an idiopathic ERM patient, second picture is of a diabetic ERM patient.

[Abstract:0266]**Central retinal artery and vein occlusion after COVID-19 vaccination (mRNA): 2 cases**

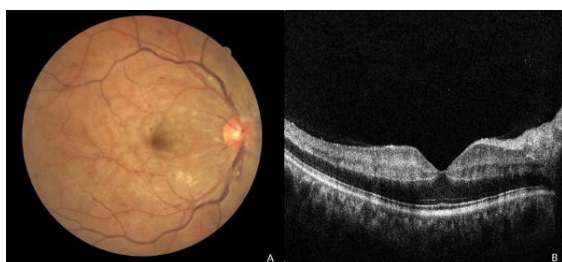Murat Karapapak, Ece Özal, Serhat Ermiş, Yusuf Cem Yılmaz, Şerife Hayat Çiloğlu, Hakan Baybora, Serkan Güler, Sadık Altan Özal

University of Health Science, Basaksehir Cam and Sakura City Hospital, Ophthalmology, Istanbul, Turkey

Combined central retinal artery occlusion (CRAO) and central retinal vein occlusion (CRVO) is a rare vaso-occlusive entity associated with multiple systemic conditions. Combined cases usually present with severe vision loss and poor visual prognosis. It is controversial which occlusion was the first event. However, in both cases, the causes of occlusion often include thromboembolic disorders with rheological factors, vascular inflammation or mechanical compression. Given the short time between onset of symptoms and vaccination, the combined CRAO and CRVO in this report present a causal relationship with the COVID-19 vaccine (mRNA-1273). It was suspected that thromboembolic events could occur in retinal vessels following COVID-19 vaccination. First, a 40-year-old male patient applied to us 7 days after receiving the first dose of the COVID-19 vaccine due to sudden severe vision loss in the right eye. (Figure) He had a history of diabetes mellitus. All systemic evaluation of the patient was unremarkable. The second patient applied to us with painless vision loss, similar to the first patient, on the 2nd day after vaccination. She had no known systemic disease. No feature was detected in the screening tests. After the diagnosis of both patients was confirmed by multiple imaging methods, hyperbaric oxygen therapy was performed. Due to the necessity of our country's insurance system, three doses of bevacizumab and then intravitreal dexamethasone were administered. At the last examination of the first patient, the best corrected visual acuity was counting fingers at 3 meters, and the second patient was counting fingers at 1 meter.

We report two cases of combined central retinal artery occlusion and central retinal vein occlusion, which occurred 1 week after the first patient was vaccinated and 2 days after the second patient was vaccinated. Clinicians should be alert that vision loss after vaccination may represent a possible ocular adverse event.

Keywords: Central retinal artery occlusion, central vein occlusion, COVID-19 vaccine

Figure

a) Color fundus photograph b) OCT image

[Abstract:0270]**internal limiting membrane peeling in a case of multiple Extrafoveal Macular Holes**

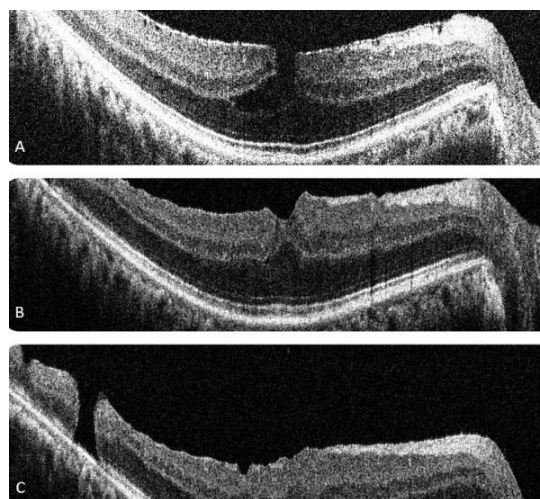
Serhat Ermiş, Şerife Çiloğlu Hayat, Ece Özal, Murat Karapapak, Yusuf Cem Yılmaz, Hakan Baybora, Sadık Altan Özal
Basaksehir Cam and Sakura City Hospital, Ophthalmology, Istanbul, Turkey

Postoperative retinal holes may be located centrally or extrafoveally and may be either full-thickness holes or lamellar hole. We describe a case of a case who had multiple eccentric macular holes (MH) occurring as a consequence of pars plana vitrectomy (PPV) surgery for lamellar MH with epiretinal membrane (ERM).

A 65-year-old man who presented to us with progressive right eye vision deficiency. Optical coherence tomography (OCT) examination revealed a lamellar MH with ERM in the right eye and normal in the left eye. We performed PPV surgery in the right eye with internal limiting membrane (ILM) peeling, with 20% sulphur hexafluoride gas endotamponade. At the postoperative second week follow-up, >20 holes MHs were observed in the temporal region of the macula on OCT imaging and wide-field fundus photography.

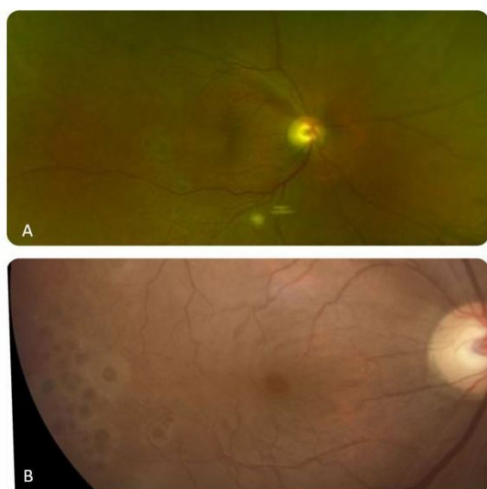
The pathogenesis of macular holes in this study is most consistent with contraction of the remaining edge of ILM.

Keywords: Eccentric macular hole; epiretinal membrane; lamellar macular hole; pars plana vitrectomy, internal limiting membrane peeling

Figure 1

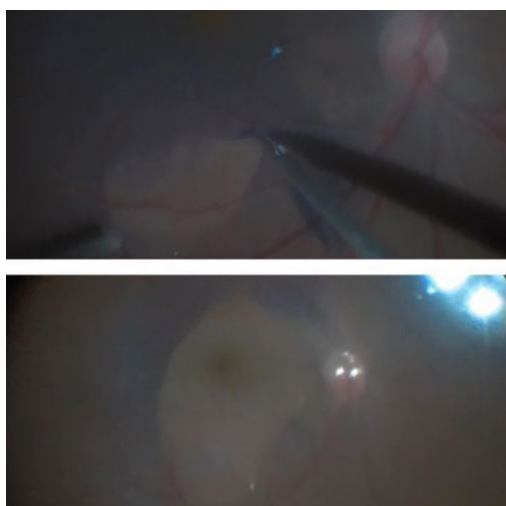
OCT demonstrating preoperative and postoperative findings. A. Preoperative erm and lamellar MH. B. Closed lamellar MH after ERM and ILM removal. C. One eccentric MH in OCT scan.

Figure 2



Fundus photograph of eccentric holes. A. Wide-field fundus photograph
B. Color fundus photograph.

Figure 3



Intraoperative images A. Starting point of pucker and ILM removal. B. ERM and ILM removal area and eccentric holes do not appear to be related

[Abstract:0286]

Evaluation of Systemic Immune-Inflammatory Index in Patients with Wet Age-Related Macular Degeneration

Betul Onal Gunay

Department of Ophthalmology, University of Health Sciences, Trabzon Kanuni Training and Research Hospital, Trabzon, Turkey

Purpose: The primary aim is to investigate the systemic immune-inflammatory (SII) index in wet-type age-related macular degeneration (AMD) patients. The secondary aim is to show the relationship between patients' best corrected visual

acuity (BCVA), central macular thickness (CMT), subfoveal choroidal thickness (SFCT) with SII, platelet-to-lymphocyte ratio (PLR) and neutrophil-to-lymphocyte ratio (NLR).

Methods: Retrospectively analyzed wet AMD patients between 2018 and 2022. Demographic data and peripheral complete blood cell count (CBC) were obtained from the electronic medical records system. The most recent BCVA, CMT, and SFCT values (within one month) to CBC were obtained from case sheets and the OCT digital image database. The SII, NLR and PLR were calculated. Age and sex-matched control group were generated.

Results: Thirty-three (23 men) wet AMD patients and 43 (24 men) control groups were included in the study. The groups were similar in terms of age and gender (78.0 ± 6.3 versus 75.6 ± 6.6 years $p=0.59$; $p=0.38$ for gender). The SII was greater in the wet AMD group (460.5 versus 440.4), but this difference did not reach statistical significance. When the correlation between SII, PLR, NLR values and BCVA (LogMAR), CMT, and SCFT was examined, there was only a moderate positive correlation between BCVA and PLR ($r=0.46$, $p=0.007$).

Conclusion: When wet AMD was compared with the control group, there was no difference in SII, NLR and PLR. There was a positive correlation between PLR and BCVA (logMAR). SII was higher in wet AMD patients than in the control group, but this difference did not reach statistical significance.

Keywords: age-related macular degeneration, systemic immune-inflammatory index, OCT

[Abstract:0297]

Experimental study on the application of negative pressure filtration device in eye surgery for patients with infectious respiratory diseases

Yang Xun, Du Shu, Sun Jian Di, Zha You You, Sun Yan Li, Xia Meng Meng, Hu Ben Li, Shao Zhen Hua, Gong Jing, Zhang Jing
Suzhou Lixiang Eye Hospital

Objective: To observe the efficacy of home-made negative pressure expiratory filtration device (the flow is 10 times of the theoretical tidal volume) in avoiding environmental pollution in the operating room and improving comfort level of patients with infectious respiratory diseases during eye surgery.

Method: Five volunteers wore masks and sterile drapes were whisked onto their face simulating the condition of ophthalmic surgery. The oxygen concentration and partial pressure of carbon dioxide at volunteers' snout, shoulder and the outlet of the device were measured every 5 minutes for 3 times in total when the negative pressure expiratory filtration device was on and off. The comfort degree was graded by number rating scale. And the data were statistically analyzed.

Results: 1. Pco₂: When the device was turned on, the inhaled Pco₂ at the snout was 1.97 ± 1.74 mmHg, the Pco₂ at the shoulder and the device outlet were 0.6 ± 0.507 mmHg and 3.83 ± 1.03 mmHg, respectively, LSD-t, $P < 0.05$. In the state of shutdown, co₂ partial pressure at the snout, shoulder, fan outlet were 7.5 ± 2.88 mmHg and 3.03 ± 3.07 mmHg and 1 ± 0 mmHg, LSD-t, $P < 0.05$. 2. Oxygen concentration: In state of power on, the inhaled oxygen concentration at snout was $29 \pm 7.01\%$, the shoulder, and device outlet oxygen concentration were $21 \pm 0\%$ and $22.7 \pm 1.29\%$, respectively, LSD-t, $P < 0.05$; In the power-off state, the oxygen concentration at snout, shoulder and device outlet were $29.9 \pm 7.29\%$, $23.5 \pm 3.39\%$ and $21 \pm 0\%$, respectively, LSD-t, $P < 0.05$. 3. Comfort degree: the comfort degree under power on and off state were 1.2 ± 1.1 and 6.0 ± 0.71 , respectively.

Conclusion: The new negative pressure expiratory filtration device can effectively remove and filter out pathogenic microorganisms from exhaled gas produced by subjects during eye surgery. It can significantly reduce environmental pollution in the operating room and the risk of infection for medical staff, also improve the subjects' comfort level.

Keywords: local anesthesia ocular operation, respiratory infectious disease, protective device

[Abstract:0311]

Bizarre tide of the vasculitide

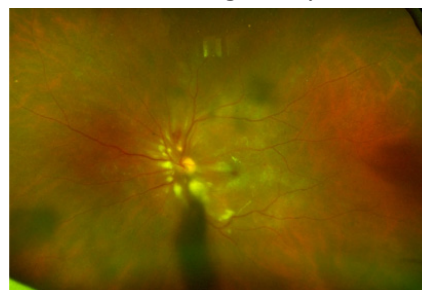
Monisha Apte, Manjula Shankar, Hemanth Murthy, Naveenam Muralidhar
Retina institute of Karnataka

A 55 year old gentleman presented with painless blurring of vision in left eye since 2 months. He was hospitalised for high-grade fever 1 month back. Laboratory investigations showed normal CBC, RFT, LFT, PBS & urine analysis, D dimer level, normal HRCT thorax & negative fever profile but positive RTPCR for COVID-19. After 3 weeks he presented to a local ophthalmologist with sudden painless blurring of vision in left eye with maculopapular skin rashes on dorsal surface of upper & lower limbs. Skin biopsy showed features of small vessel vasculitis negative for IgG & IgA on direct immunofluorescence & started on 60 mg/day of oral steroids. After 1 week follow-up, he complained of further drop in vision & referred to immunologist. He was given 2 cycles of pulse cyclophosphamide therapy & continued oral steroids. He was on Tofacitinib & oral steroids on presentation. BCVA RE was 6/9 & LE CF close to face on presentation. Anterior chamber was quiet with clear vitreous in both eyes. Fundus showed multifocal retinitis patches in both eyes with presence of macular edema, pale disc & presence of perifoveal retinal whitening in left eye & sclerosed vessels seen in both eyes, more in left eye. LE OCT macula showed inner layer hyper-reflectivity with macular edema. Right eye OCT was normal. FFA showed presence of normal FAZ in RE with hypofluorescence corresponding to retinitis patches. LE showed absence of perfusion of the posterior pole with severe macular ischemia. IgM and IgG for SARS CoV 2 were high. He

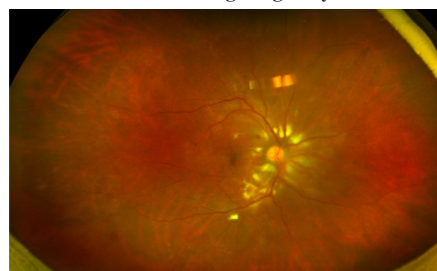was asked to continue systemic steroid therapy with addition of oral doxycycline 100 mg twice a day & stopped Tofacitinib after immunologist consultation. BCVA in RE was maintained at 6/9 at 2 months with left eye vision improving to FC3m

Keywords: microangiopathy

Fundus Image Left Eye



Fundus Image Right Eye



[Abstract:0312]

Connecting the dots

Monisha Apte, Hemanth Murthy, Manjula Shankar, Muralidhar Naveenam
Retina institute of karnataka

Purpose: To report a case of bilateral APMPE following COVID-19 vaccination

Methods: Interventional case report. Review of clinical and photographic records.

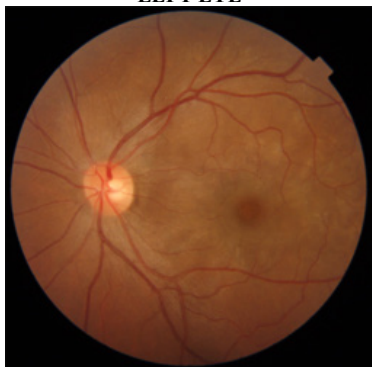Results: A 34 year old otherwise healthy female presented with diminution of vision in both eyes preceded by photopsia, a week following first dose of ChAdOx1 nCoV-19 Corona Virus Recombinant vaccine (COVISHIELD, Serum Institute of India, Pune, India). Vision was 3/60, N18 in both eyes. Fundus examination of both eyes revealed multiple discrete yellow-white placoid lesions at the level of deep retinal layers throughout the posterior pole. Swept source OCT showed presence of multiple loculated SRF and outer retinal changes with increased choroidal thickness with undulation in both eyes. Fundus autofluorescence showed numerous hyperautofluorescent lesions. Fundus fluorescein angiography showed presence of early hypofluorescence with late staining of lesions in both eyes. Indocyanine green angiography showed early hypofluorescence which persisted in late stages. Thus

diagnosis of bilateral APMPE was made and was started on oral prednisolone 1mg/kg/weight with slow tapering resulting in resolution of lesions within a month leading to improvement in visual acuity to 6/6, N6 in both eyes.

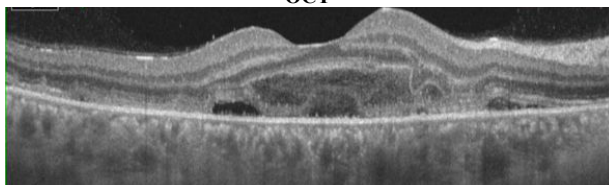
Conclusion: Previous COVID-19 vaccination should be kept in mind in the differential diagnosis of APMPE disease spectrum.

Keywords: vaccination, APMPE

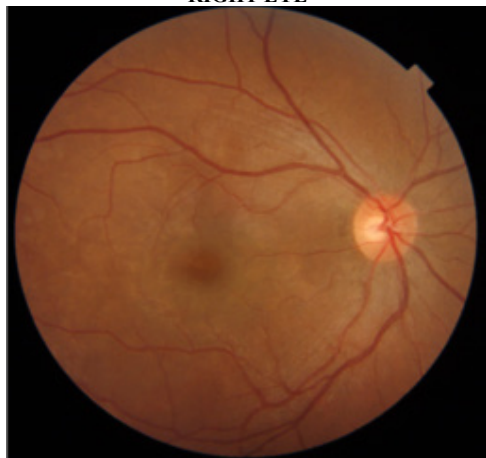LEFT EYE



OCT



RIGHT EYE



[Abstract:0314] Intraocular Angiopoietin-2 Levels in Diabetic Macular Edema

Umit U Inan¹, Sibel Inan², Jale Akgol³, Ali Arslan⁴, Onur Polat⁵

¹Department of Ophthalmology, Izmir Can Hospital, Izmir, Turkey

²Department of Ophthalmology, Health Sciences University, Bozyaka Training and Research Hospital, Izmir, Turkey

³Department of Medical Pharmacology, Afyonkarahisar Health Sciences University, School of Medicine, Afyonkarahisar, Turkey

⁴Department of Ophthalmology, ParkHayat Hospital, Afyonkarahisar, Turkey

⁵Department of Ophthalmology, Dunya Goz Hospital, Bursa, Turkey

Purpose: Angiopoietin-2 (Ang-2) is upregulated in hyperglycemia, oxidative stress and hypoxia conditions. It increases vascular permeability by interacting with Tie-2 receptors. Angiopoietin-2 is a new treatment target together with anti-VEGF therapy for retinal vascular diseases. We aimed to investigate intraocular ang-2 levels in patients who received anti-VEGF injection due to diabetic macular edema (DME).

Methods: Forty-three eyes diagnosed with DME were included in the study. Before intravitreal anti-VEGF injection, 0.1 cc of aqueous humor was withdrawn from the anterior chamber by paracentesis and stored for Ang-2 and VEGF detection. Twenty eyes with cataract without any systemic or ocular disease were included as control group and aqueous humor samples were taken at the beginning of cataract surgery. Ang-2 and VEGF levels were measured with the ELISA kit. The patients' best corrected visual acuity, central macular thickness (CMT), and change in macular thickness in response to treatment were recorded.

Results: The mean age of the patients was 59.5±5.9 years (DME), and 65.07±11.3 years (control). Mean CMT was 446.1±141.4 µm at baseline and 310.0±52.1 µm at 6-month. Mean aqueous VEGF levels were 828.8±881.3 pg/mL and 51.7±32.5 pg/mL in eyes with DME and control, respectively (p: 0.005). Mean aqueous Ang-2 levels were 502.2±245.1 pg/mL, and 46.8±20.8 pg/mL in eyes with DME and control, respectively (p: 0.001). A positive correlation was found between aqueous VEGF and Ang-2 levels and baseline CMT (p: 0.001 and p: 0.03, respectively). No correlation was found between aqueous VEGF and Ang-2 levels and changes in CMT.

Conclusion: In our study, we found that ANG-2 levels were increased along with the basal aqueous humor VEGF level in eyes with DME who would receive anti-VEGF injection. Our results appear to be consistent with targeting the Ang-2 pathway in new therapies for DME.

Keywords: Angiopoietin-2, Aqueous Humour, DME

[Abstract:0325]**Intraocular Angiopoietin-2 Levels in Neovascular Age-Related Macular Degeneration**Umit U Inan¹, Sibel Inan², Jale Akgöl³, Ali Arslan⁴, Onur Polat⁵¹Department of Ophthalmology, Izmir Can Hospital, Izmir, Turkey²Department of Ophthalmology, Health Sciences University, Bozaka Training and Research Hospital, Izmir, Turkey³Department of Medical Pharmacology, Afyonkarahisar Health Sciences University, School of Medicine, Afyonkarahisar, Turkey⁴Department of Ophthalmology, ParkHayat Hospital, Afyonkarahisar, Turkey⁵Department of Ophthalmology, Dunya Goz Hospital, Bursa, Turkey

Purpose: Angiopoietin-2 (Ang-2) is known to play a role in the disruption of the blood retinal barrier, pericyte loss and stimulation of neovascularization. It has become a new treatment target in retinal vascular diseases. We aimed to investigate intraocular Ang-2 levels in patients who received anti-VEGF injection due to choroidal neovascularization (CNV) secondary to age-related macular degeneration (n-AMD).

Methods: Thirty-three eyes with n-AMD were included in the study. Prior to intravitreal anti-VEGF injection, aqueous humor was withdrawn from the anterior chamber by paracentesis. Aqueous humor samples were stored for intraocular Ang-2 and VEGF detection. As a control group, 21 eyes of 21 patients with cataract without any systemic or ocular disease were included and aqueous humor samples were taken at the beginning of cataract surgery. VEGF and Ang-2 levels were measured with the ELISA kit. The patients' best corrected visual acuity, central macular thickness (CMT), and change in macular thickness in response to treatment were recorded.

Results: The mean age of the patients was 72.3±7.9 years (n-AMD), and 60.1±9.8 years (Control). Mean CMT was 406.3±124.3µm at baseline and 262.9±23.8µm at 6-month. The mean aqueous VEGF levels were 68.8±60.3 pg/mL and 50.3±29.7 pg/mL in the n-AMD and control groups, respectively (p>0.05). The mean aqueous Ang-2 levels were 51.0±20.9 pg/mL and 44.8±19.3 pg/mL in the n-AMD group and control group, respectively (p>0.05). There was no correlation between VEGF or Ang-2 levels and change in CMT or CMT.

Conclusion: The aqueous humor levels of Ang-2 and VEGF did not differ between eyes with n-AMD and the control group. The absence of a significant increase may be related to the choroidal origin of neovascular pathology in eyes with n-AMD. Thus, choroid-derived VEGF and Ang-2 may have insufficient access to aqueous humor. However, further studies are needed.

Keywords: n-AMD, Aqueous, Angiopoietin-2

[Abstract:0337]**Retinal sensitivity for ultraviolet radiation and its effects in vertebrate animal retina with UV sensitive vision will be a leading knowledge for human retina**

Kazim Hilmi Or

Private Office of Ophthalmology

Purpose: Humans don't have ultraviolet(UV)-sensitive vision, but most vertebrates do. New studies about some animals show the extent of barrier effect of the cornea and the lens to ultraviolet radiation.

Methods: Literature about vertebrate animals with UV sensitive vision are evaluated in properties of corneal properties.

Results: The majority of animals, including most vertebrates, can see ultraviolet (UV) light. For UV sensitive vision animals need UV-sensitive photoreceptors and UV-transmitting ocular media, including cornea, aqueous humour, lens and vitreous. Most birds are photosensitive to 355-426 nm with there SWS1 photoreceptors. Although UV radiation have similar effects on the skin and other tissues of the animals like in humans, the UV sensitive vision doesn't make the animals blind. The protecting mechanisms in animals against UV radiation should be evaluated.

Conclusion: In animals the barrier effect of cornea and lens against the UV radiation is relatively less than in humans, so that the UV can hit the retina and can be perceived as visual perception if there are photoreceptors for UV. The UV transmittance of the corneas and the protective effects in the retinas of the animals with UV sensitive vision should be evaluated for the use in lessening the UV related damages in human eyes.

Keywords: Ultraviolet sensitive vision, effect of UV on the retina

[Abstract:0338]**OCT retinal images for DICOM: Image processing problems**

Kazim Hilmi Or

Private Office of Ophthalmology

Background: With DICOM (Digital Imaging and Communications in Medicine), the images in OCT retinal exams must be processed before they can be shared and/or compared, as many instruments using the same technique have unique imaging processes. The problems of the different proportions or properties of the images for the same examination should be solved so that the digital evaluation of these images creates fewer problems.

Methods: DICOM is the international standard for medical images and associated metadata. It defines the formats for

medical images that can be exchanged with the data and quality required for clinical use. Unique imaging in each instrument of different brands using the same technique is a problem as they can alter and/or distort the image. The need for image processing and its possible negative effects are discussed.

Results: Images made in OCT and OCTA are mostly 2D and in pixels, others 3D and in voxels, which makes it difficult to compare different devices. In order to be able to compare the changes in images, they must have the same backlight, the same size of the image and the same size of the background and / or neighboring structures. Therefore, changes in contrast, illuminance and size (pixelization!) may be necessary, which may alter the information contained within.

Conclusion: To maintain DICOM standards in OCT retinal images from different devices for comparison, they should be similarly created in instruments using the same technique. Subsequent processing of the images can lead to disturbances that can complicate or falsify the digital evaluation and comparison.

Keywords: DICOM, OCT retina images

[Abstract:0356]

Analysis of a two-year independent screening effort for retinopathy of prematurity in rural Egypt

Sara Ahmed Tawfik, Ahmed Saied Mansour, Norhan Lotfy Selim, Ahmed Habib, Mariam Al Fekky, Mohammed Tawfik, Youssef Fouad
Al-Ferdaws Eye Hospital, Egypt

Background: The third epidemic of retinopathy of prematurity (ROP) has majorly involved middle income countries in which tailored screening and local guidelines require development. The data regarding ROP prevalence and cutoff numbers for screening in Egypt are lacking.

Methods: Retrospective analysis of an independent screening effort spanning 2 years (February 2019 to February 2021) and involving 32 neonatal care units within Sharkia governorate, Egypt. Infants of gestational age (GA) \leq 34 weeks and/or birth weight (BW) \leq 2000 g were included, as well as those with unstable clinical course. Two eyecare centers located in Sharkia and Cairo governorates served as referral centers for any required interventions.

Results: Of the 276 screened infants, 133 (48.2%) had some form of ROP that was bilateral in 127 (95.5%) of them. Aggressive posterior ROP (AP-ROP) was detected in both eyes of 24 infants (8.7%). The median (IQR) GA of infants with ROP was 32 (30–34) weeks, and the median (IQR) BW was 1600 (1350–2000) g. Sixty-three infants (47.4%) required treatment. Of the total 84 eyes that primarily were treated, 73 (86.9%) received intravitreal ranibizumab, 8 (9.5%) underwent laser ablation therapy, and 3 eyes (3.6%) underwent surgery. Recurrence rate was 16.7% (14 eyes). Final outcome was favorable in 83 eyes (98.8%). Applying the American Academy criteria would have led to the missing

of 36.8% of infants with ROP and 28.6% of those requiring treatment in our sample.

Conclusion: The incidence of both ROP and AP-ROP in the Egyptian rural setting appears to be in the high end of global reported rates. Prevention measures should urgently be planned and implemented.

Keywords: ROP

[Abstract:0373]

Angiopoietin-2 Signalling and Vascular Stability with Faricimab in Diabetic Macular Edema

Sengul Ozdek¹, Zdenka Haskova², Jeffrey R. Willis², Peter Westenskow³

¹*Department of Ophthalmology, Gazi University School of Medicine, Ankara, Türkiye*

²*Genentech, Inc., South San Francisco, CA, USA*

³*Roche Pharma Research and Early Development, Roche Innovation Center, F. Hoffmann-La Roche AG, Basel, Switzerland*

Purpose: To explore the impact of dual angiopoietin (Ang)-2/vascular endothelial growth factor (VEGF)-A inhibition on vascular stability (VS) in diabetic macular edema (DME) using pre-clinical and phase 2/3 data.

Methods: In JR5558 mice (spontaneous choroidal neovascularisation [CNV] model), effects of anti-Ang-2, anti-VEGF-A, both (VA2) or none/immunoglobulin G (IgG; control) on VS (neovascular leakage and subretinal inflammation [Iba1+, CD45+, CD11b+]) were evaluated at 1 week (W), 3W and 5W post-treatment. In phase 2 BOULEVARD (NCT02699450), the effect of faricimab, a bispecific Ang-2/VEGF-A neutralising antibody, on sustained retinal stability (SRS; achievement and maintenance [\leq 10% worsening] of central subfield thickness [CST] \leq 325 μ m to W24) was assessed. VS with faricimab was evaluated using anatomic outcomes in phase 3 YOSEMITE/RHINE (NCT03622580/NCT03622593).

Results: In JR5558 mice, CNV lesion leakage was reduced at 1W with anti-Ang-2, anti-VEGF-A and VA2 versus controls and maintained at 3/5W with anti-Ang-2 and VA2 only. VA2 treatment reduced Iba1+, CD45+ and CD11b+ cell infiltration at 1W versus IgG; at 5W, only anti-Ang-2 and VA2 reduced Iba1+ infiltration. In BOULEVARD, >50% of patients achieved SRS at W16/20 with faricimab and ranibizumab, respectively. In YOSEMITE/RHINE, reductions in CST, absence of DME (CST \leq 325 μ m) and absence of intraretinal fluid through W100 favoured faricimab every 8 weeks (Q8W) or personalised treatment interval (PTI) up to Q16W over aflibercept Q8W and were achieved with most PTI-treated patients on extended dosing.

Conclusions: Dual inhibition of Ang-2/VEGF-A improves VS and reduces inflammation, with greater anatomic outcomes and improved durability over anti-VEGF alone in patients with DME.

Keywords: Angiopoietin-2, Faricimab, Vascular stability

[Abstract:0387]

Two Cases of Multifocal Best's Disease

Pınar Kaya¹, Uğur Gürlevik², Yasemin Özdamar Erol¹¹Department of Ophthalmology, University of Health Sciences, Etilik City Hospital, Ankara²Department of Ophthalmology, Aksaray State Hospital, Aksaray

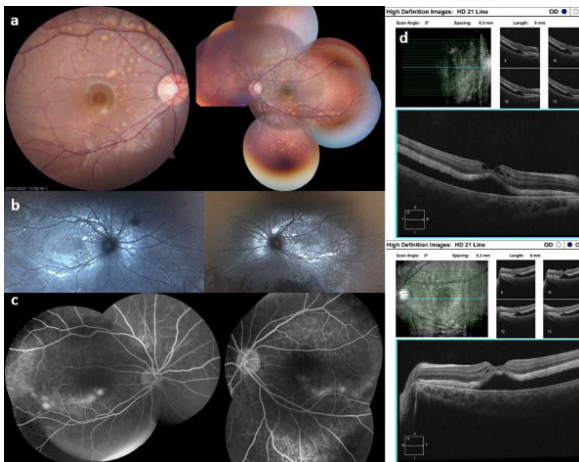
Purpose: To report the clinical features of two cases with multifocal Best's disease.

Case Presentation: First of our cases was a 10-year-old female who presented with progressive vision loss in both eyes for three years. The best corrected visual acuity (BCVA) with the Snellen chart was 0.6 in both eyes. The second case was a 22-year-old male patient with 0.9 BCVA in both eyes. Colour fundus photograph showed multiple small round yellow subretinal lesions on the posterior pole extending beyond the arcades in both cases. Multiple hyperautofluorescent lesions were detected in fundus autofluorescence imaging (Figure 1 and 2). Optical coherence tomography (OCT) scans through the fovea revealed thickened ellipsoid zone and separation from the retina pigment epithelium with an optically clear space and intraretinal cysts. Fundus fluorescein angiography showed no leak but pooling in lesion areas (Figures 1 and 2). Arden ratio was 115% in the right eye and 110% in the left eye of the first case.

Conclusion: This report of two cases showed a rare eye disease, multifocal Best's disease, which can help clinicians to differentiate it from similar lesions.

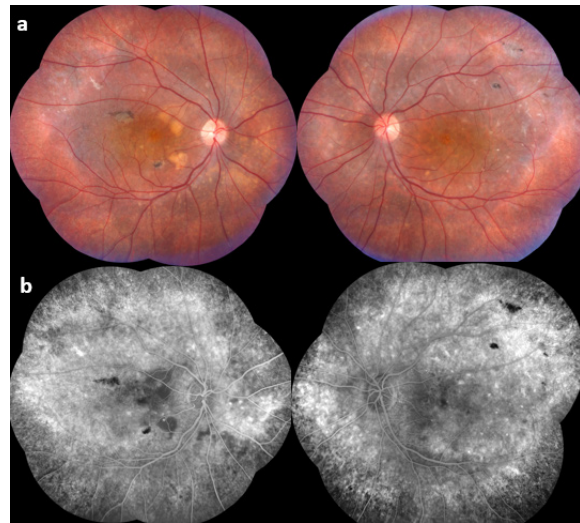
Keywords: Multifocal Best's disease, ocular imaging

Figure 1



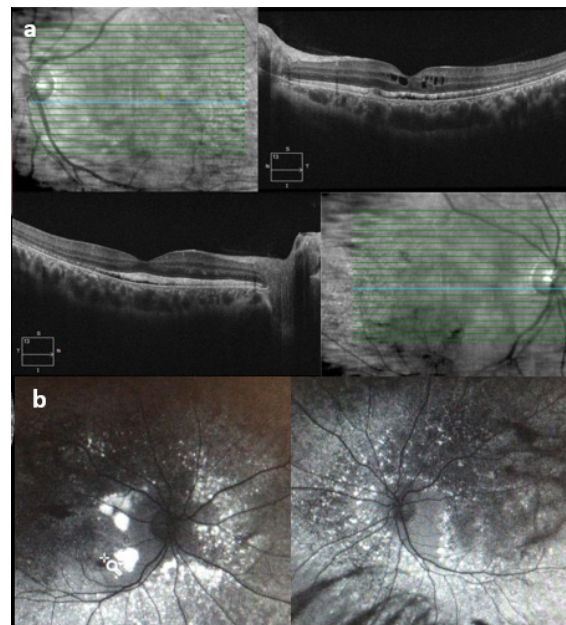
Multiple small round yellow subretinal lesions were seen on the posterior pole (a), multiple hyperautofluorescent lesions were detected in fundus autofluorescence (b), fluorescein pooling in lesion areas (c), thickened ellipsoid zone and separation from the retina pigment epithelium with an optically clear space and intraretinal cysts were determined in optical coherence tomography images (d) of the first case.

Figure 2



Multiple small round yellow subretinal lesions were seen on the posterior pole (a), and fluorescein pooling in lesion areas (b) were detected in fundus fluorescein angiography of the second case.

Figure 3



Thickened ellipsoid zone and separation from the retina pigment epithelium and intraretinal cysts were determined in optical coherence tomography images (a), and multiple hyperautofluorescent lesions were detected in fundus autofluorescence (b) of the second case.

[Abstract:0391]**Vitreous Base Avulsion Due to Penetrating Injury with Intraocular Foreign Body**

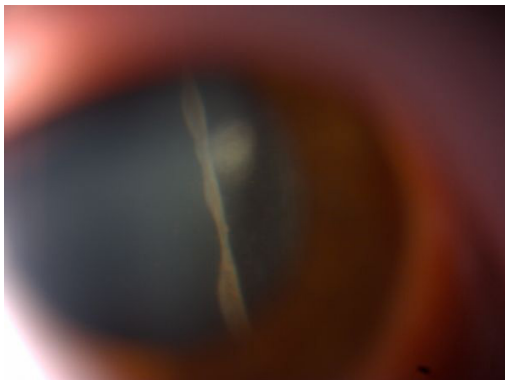
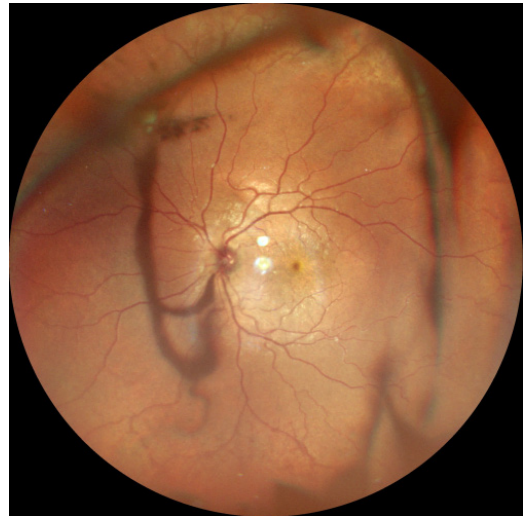
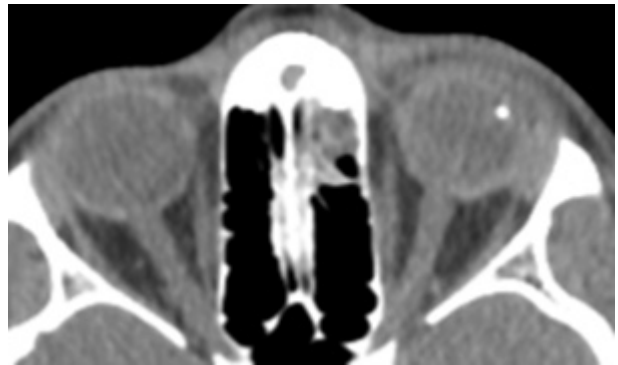Cumali Degirmenci, Seray Şahin, Filiz Afrashi, Cezmi Akkın
Ege University, Faculty of Medicine, Department of Ophthalmology,
Izmir, Turkey

Introduction: Vitreous base avulsion (VBA) is defined as the release of the vitreous base in the vitreous cavity due to ocular trauma. It is a condition that accompanies blunt ocular traumas in which the vitreous base is separated from the retina and pars plana. Although VBA is frequently seen clinically, it may be difficult to detect with conventional methods. In the case we aimed to present vitreous base avulsion in a patient with an intraocular foreign body due to penetrating eye injury.

Case Report: 13-year-old female patient was referred from the emergency department, who had an ocular penetrating injury due to pen sticking in her eye by her friend. At the initial examination, the patient's visual acuity was 20/20 and counting fingers from 3 meters in the right and left eyes, respectively. In the anterior segment examination, the right eye was normal. Scleral penetration area was observed at a distance 5 mm of from the limbus in the left eye superotemporal region. Anterior segment examination revealed VBA in the temporal quadrant of the left eye (Figure 1). In addition, VBA was imagined with ultra-widefield fundus photography (Figure 2). A hyperdense intraocular foreign body was observed on computed tomography (Figure 3). Retinal tear was not observed in the patient who underwent intraocular foreign body extraction, and visual acuity increased to 20/20 during follow-up.

Conclusion: Although VBA is a common condition, it is thought to be reported less frequently due to the difficulties in its detection. In addition, it has been reported that it is most commonly seen in open globe injury in the new classification. Open globe injury due to intraocular implantation of the pen tip is a rare trauma, and its cause of vitreous base avulsion has not been reported before to our knowledge.

Keywords: penetrating eye injury, trauma, vitreous base

Figure 1*Vitreous base avulsion with anterior segment imaging***Figure 2***Ultra-widefield fundus photography***Figure 3***Computed Tomography image, intraocular foreign body in the left eye***[Abstract:0404]****Comparison of Pro Re Nata Aflibercept, Ranibizumab and Bevacizumab Treatment in Pachychoroid Neovascularopathy**

Güner Üney, Dicle Hazirolan, Nurten Ünlü, Özlem Candan,
Gözde Orman
University of Health Sciences Ankara Training and Research Hospital

Purpose: To compare the efficacy of pro re nata (PRN) aflibercept, ranibizumab and bevacizumab treatment in pachychoroid neovascularopathy (PNV).

Methods: Cases treated with PRN aflibercept, ranibizumab and bevacizumab for PNV were evaluated. Demographic data, choroidal thickness, number of injections, central foveal thickness (CFT) and best corrected visual acuity (BCVA) at baseline, 3rd, 6th and 12th months were compared according to the type of anti-vascular endothelial growth factor agents.

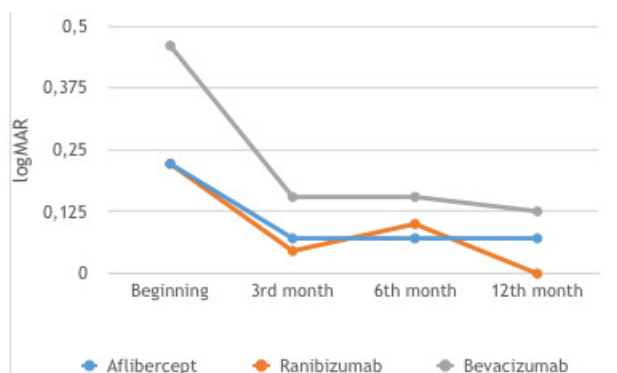
Results: Fourteen patients had aflibercept treatment, 14

patients received ranibizumab, and 6 patients received bevacizumab. There was no difference between the cases in terms of age, gender, choroidal thickness, and the number of injections. The beginning, 3rd, 6th and 12th month BCVA ($p=0.6, 0.7, 0.2, 0.4$) and CFT did not differ ($p=0.2, 0.3, 0.5, 0.3$) between groups. When BCVA was evaluated according to the follow-up period, the visual change was statistically significant in the aflibercept and ranibizumab groups ($p=0.006, 0.0001$), nevertheless the change of BCVA in the bevacizumab group was not significant ($p=0.4$). CFT was significantly decreased in all the three groups at the follow-up period ($p=0.03, 0.002, 0.2$).

Discussion: Pro re nata treatment of aflibercept, ranibizumab and bevacizumab for PNV have similar effects on BCVA and CFT. Less successful results were obtained with bevacizumab in terms of BCVA compared with the other two agents.

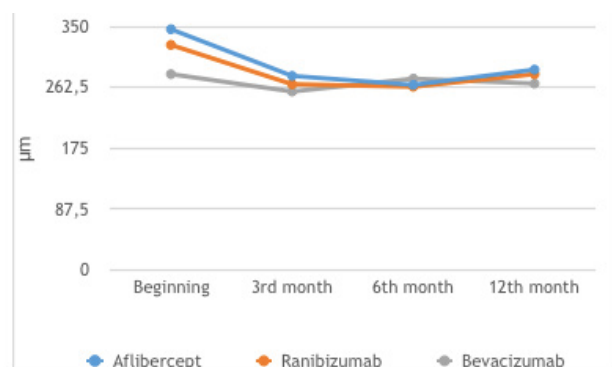
Keywords: Anti-vascular endothelial growth factor, pachychoroid neovasculopathy, pro re nata treatment

Figure 1



Best corrected visual acuity of aflibercept, ranibizumab and bevacizumab received groups in the follow-up period.

Figure 2



Central foveal thickness of aflibercept, ranibizumab and bevacizumab received groups in the follow-up period.

[Abstract:0407]

Real-Life Data of Patients With Exudative Age-Related Macular Degeneration Treated With Intravitreal Anti-Vascular Endothelial Growth Factor Injections

Mehmet Erol Can, Eda Nur Gönültaş Özkan

Department of Ophthalmology, Bursa City Hospital, Bursa, Türkiye

Purpose: To evaluate the real life experiments and clinical results of intravitreal anti-vascular endothelial growth factor injections in patients with exudative-type age-related macular degeneration (AMD).

Methods: A total of 250 eyes of 196 patients with exudative AMD treated with intravitreal anti-vascular endothelial growth factor therapy (anti-VEGF) injections (ranibizumab 0.3 mg/0.05 mL, aflibercept 2 mg/0.05 mL, bevacizumab 1.25 mg/0.05 mL) were included in the study. Patients were followed up for at least 12 months were evaluated retrospectively. Best-corrected visual acuity (BCVA) measured with the Snellen chart, and optical coherence tomography images were evaluated at the first visit and during the follow-up period.

Results: 88 of the patients were female (44.9%) and 108 were male (55.1%). The mean age was 73.74 ± 9.23 years. The mean number of patient visits were 7.19 in the first year, 4.58 in the second year, and 4.96 in the third year, and the mean number of injections was 5.03 in the first year, 2.43 in the second year, and 2.22 in the third year. The mean BCVA were 1.05 ± 0.59 logMar at baseline, 0.97 ± 0.57 logMar at first year, 1.06 ± 0.56 logMar at second year, and 1.02 ± 0.57 logMar at third year ($p<0.05$). The mean central macular thickness were 321.58 ± 92.52 μ m at baseline, 290.72 ± 71.38 μ m at first year, 291.36 ± 76.73 μ m at second year, and 279.83 ± 74.68 μ m at third year ($p<0.05$).

Conclusion: Although anatomical success is achieved with anti-VEGF therapy, baseline BCVA is the most important prognostic factor in exudative age-related macular degeneration.

Keywords: Exudative age-related macular degeneration, intravitreal injection, real-life data

[Abstract:0408]

Frosted Branch Angiitis

Anwara Mammel

Goyal Eye Institute, New Delhi, India

A 22-year-old male presented with fever, headache, and a diminution of vision in both eyes for 5 days. Visual acuity in the right eye was FC 5 meters while in the left eye vision was finger counting close to face with accurate projection of rays. Both eyes showed anterior and posterior segment inflammation with cells, flare and vitreous cells. Fundus showed both eye disc edema with macular edema with ERM in a macular star configuration. Severe vascular sheathing was present with hemorrhages and exudates surrounding vessels in

a frosted branch configuration.

Serum IgG for cytomegalovirus (CMV) was positive. Cerebrospinal fluid (CSF) also showed positive viral markers for CMV. Patient was started on IV acyclovir 500 mg thrice a day along with IV antibiotic coverage and IV dexamethasone 16 mg thrice a day. The patient showed improvement in terms of disc and macular edema along with fundus features and complete resolution by day 11, while vision improved to 6/60 and FC 5m in right and left eye respectively.

Keywords: Frosted branch angiitis, vascular sheathing

[Abstract:0412]

Postoperative Perfluorocarbon Liquid Tamponade versus Combined Pars Plana Vitrectomy and Scleral Buckle for Rhegmatogenous Retinal Detachment with Inferior Retinal Breaks and Proliferative Vitreoretinopathy: A Case-Control Study

Mehmet Citirik, Cagri Ilhan, Tugce Horozoglu Ceran, Mehmet Yasin Teke
University of Health Sciences, Ankara Etlik City Hospital, Ankara, Türkiye

Purpose: To compare the outcomes of pars plana vitrectomy with medium-term perfluorocarbon liquid tamponade (PPV-mPL) and combined pars plana vitrectomy and scleral buckle surgery (PPV-SB) for rhegmatogenous retinal detachment with inferior retinal breaks complicated by advanced proliferative vitreoretinopathy (iRRD-PVR).

Materials-Methods: Medical records of patients who underwent vitreoretinal surgery due to iRRD-PVR were investigated. Group 1 which included 48 eyes was constructed with patients who underwent PPV-mPL and Group 2 which included 36 eyes was constructed with patients who underwent PPV-SB (5000 cSt silicone oil tamponade). The anatomical and functional outcomes and the durations of the surgeries were compared.

Results: There was no significant difference in both demographic and baseline clinical characteristics between the groups ($p > 0.05$, for all). The mean duration of the first surgery was 42.82 ± 15.25 min (25-65) in Group 1 and 81.46 ± 37.48 min (45-115) in Group 2 ($p < 0.001$). The mean follow-up time after the final surgery was 14.39 ± 5.39 months (6-27) in Group 1 and 15.01 ± 6.89 months (6-30) in Group 2 ($p > 0.05$). At the end of the follow-up time, recurrent retinal detachment occurred in three cases (6.2%) in Group 1 and two (5.5%) in Group 2 ($p > 0.05$). The mean BCVA was 1.53 ± 0.60 logMAR (2.30-0.70) in Group 1 and 1.70 ± 0.41 logMAR (2.30-1.00) in Group 2 ($p > 0.05$).

Conclusion: When compared with the PPV-SB, PPV-mPL seems to be a more comfortable way to treat iRRD-PVR, with no sacrificing anatomical and functional results.

Keywords: Perfluorocarbon, proliferative vitreoretinopathy, vitreoretinal surgery

[Abstract:0413]

Branch Retinal Arterial Occlusion Caused Toxoplasmic Chorioretinitis in an Young Patient

Refref Yüksel
Department of Ophthalmology, Kocaeli University School of Medicine, Kocaeli, Türkiye

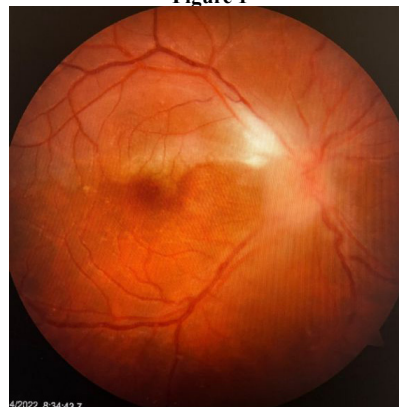
Introduction: Toxoplasmic chorioretinitis is a common ocular infection that can cause many serious morbidities. (1). Toxoplasma infection in the eye manifests as a necrotizing chorioretinitis that can cause a retinal vascular occlusion(4).

Case Report: A 24-year-old male patient was presented blurred vision and loss of the inferior field in his right eye. His best corrected visual acuity was 20/100 in the right eye and 20/20 in the left eye. Anterior segment examination of the right eye showed no anterior chamber inflammation. Fundus examination of the right eye showed +1 vitritis and a focal area retinitis, optic disc swelling and pallor in the upper half of the macula. This lesion was approximately one disc in diameter and located adjacent to the superotemporal margin of the optic disc. Humphrey visual fields Humphrey visual fields 24-2 showed an inferior altitudinal defect in the right eye. Optical coherence tomography showed the active retinitis lesion. Fundus fluorescein angiography (FFA) of the right eye showed that the superior temporal retinal artery was occluded. Laboratory workup was showed elevated the anti-toxoplasma IgG levels. The patient was placed on a 6-week course of trimethoprim/sulfamethoxazole (1,600/320 mg orally twice daily) and clindamycin (300 mg per os three times daily). Three days after these drugs were started systemic prednisolone (80 mg Daily by tapering doses) was added to the regimen. Active chorioretinitis resolved on the subsequent visit and visually activity in his right was 20/20 however, the lower half visual field defect decreased but became permanent in one area.

Discussion: Toxoplasma chorioretinitis is an important ocular disease. Although retinal artery occlusion is not very common, it can cause permanent eye defects when it does. The damage should be tried to be minimized by early diagnosis and treatment of the disease and by preventing recurrences.

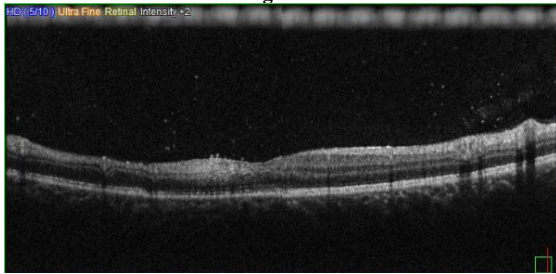Keywords: Toxoplasma, retinal artery occlusion

Figure 1



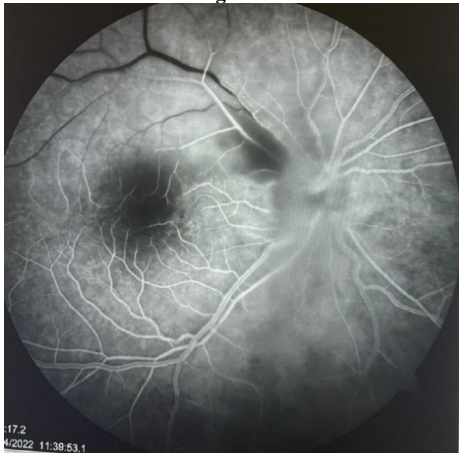color fundus photo

Figure 2



optihal cohorence tomograpyh photo

Figure 3



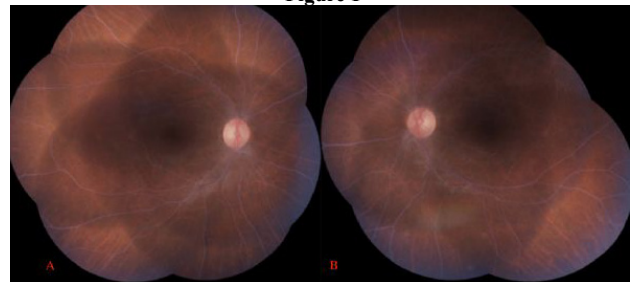
FFA photo

/ dL) and a triglyceride level of 6015.6 mg / dL (normal range, 50-149 mg / dL). After these results, the patient started to use fenofibrate (Lipanthyl® 267 mg capsule) and blood lipid levels were tested again 10 days later. Laboratory examination revealed decreased levels of cholesterol (265 mg / dL) and triglyceride (743 mg / dL) levels. Retinal vessels were clearly observed in the colored fundus image taken during the treatment follow-up (Figure 3).

Lipemia retinalis is a rare presentation of hypertriglyceridemia. To the best of our knowledge, this is the first case in the literature associated with chemotherapeutic drugs. The findings are an indicator of systemic disease and sometimes this is the first diagnosis are placed.

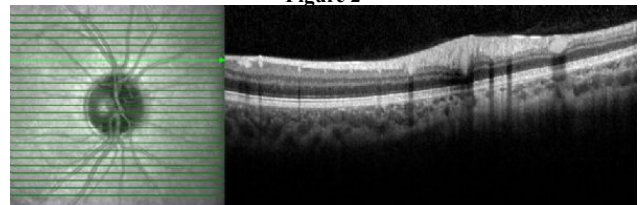
Keywords: AML, Hypertriglyceridemia, Lipemia retinalis

Figure 1



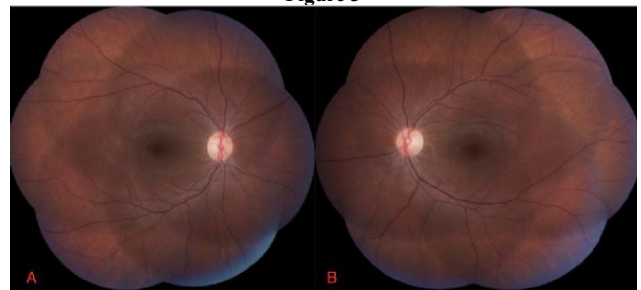
Fundus photograph of right (A) and left (B) eye, Grade 3 Lipemia retinalis. All vessels are creamy white in color. It is difficult to distinguish between arteries and veins.

Figure 2



Spectral-domain optical cohorence tomograpy images showing hyperreflective dots accumulated especially in retinal vessels

Figure 3



Fundus photograph of right (A) and left (B) eye, taken on the 10th day follow-up; Returned to normal in retinal vessels after lipid-lowering therapy

[Abstract:0445]

Lipemia Retinalis Associated Acute Myeloid Leukemia Treatment

Reyhan Hazal Kaplan Koruk, Mehmet Selim Kocabora
Medipol Mega University Hospital Ophthalmology
Department, Istanbul, Türkiye

We report a case of lipemia retinalis presenting secondary to the used chemotherapeutic drug for leukemia.

An 11-year-old girl was diagnosed with acute myeloid leukemia (AML). She was referred to our clinic for an eye examination before stem cell transplantation. Before our ophthalmologic examination, the patient was commenced on a flag-ida protocol (fludarabine, idarubicin, granulocyte-colony stimulating factor, and high-dose cytarabine).

The patient demonstrated normal visual acuity in both eyes. Fundus examination revealed a color change in all retinal vessels and a salmon-pink retina was seen in the left and right posterior poles (Figure 1). Spectral domain-optic coherence tomography (oct) (Spectralis; Heidelberg Engineering, Heidelberg, Germany) revealed high reflective points in the inner retinal layers (Figure 2). After that evaluation we diagnosed the patient with lipemia retinalis. Retinal fundus fluorescein angiography showed normal vascular flow bilaterally. A laboratory assessment for a total serum cholesterol level of 727.6 mg / dL (normal range, 120-220 mg

[Abstract:0487]**Diabetic Retinopathy in Pregnancy**Kshitij Raizada*Dr. Raizada Eye Centre, Bareilly, India*

Pregnancy can lead to worsening of pre-existing Diabetic Retinopathy or could lead to new development of Diabetic Retinopathy owing to Gestational Diabetes Mellitus.

Gestational Diabetes Mellitus could lead to development of permanent Diabetes in mothers as well as fetus. Though Diabetic Retinopathy regresses in most of the cases after childbirth, but in a significant number of women, it is known to progress quite aggressively.

Diabetic Retinopathy in Pregnancy poses a serious risk to the vision of mother and if not treated in time, can lead to deleterious effects. Treatment of Diabetic Retinopathy in pregnancy is intriguing as there is little conviction regarding the safety of the various treatment modalities in mothers as well as fetus. Teratogenic potential of Intra-vitreous Anti-VEGF injections, Intra-Vitreous Steroid implants is not clearly understood.

Through this presentation, we aim to highlight the pathogenesis, clinical features, diagnostic and therapeutic modalities of Diabetic Retinopathy in Pregnancy and elucidate the treatment protocols to be followed during the course of pregnancy and lactation.

The role of Fundus Fluorescein Angiography, Indocyanine Angiography, OCT, OCT-Angiography, Laser

Photocoagulation, Intra-Vitreous Injections, Vitrectomy and Anaesthesia shall be discussed throwing light on their efficacy, usage and safety profile.

Keywords: Diabetic Retinopathy, Pregnancy, Gestational Diabetes Mellitus

[Abstract:0492]**Comparison Of Early Microvascular Changes After Pars Plana Vitrectomy For Idiopathic Epiretinal Membrane With or Without Internal Limiting Membrane**Mahmut Oğuz Ulusoy, Cansu Erseven, Büşra Erel*Ophthalmology Department, Bursa Yüksek İhtisas Research Hospital, Bursa, Turkey*

Purpose: To compare early microvascular changes after pars plana vitrectomy for idiopathic epiretinal membrane (erm) with or without internal limiting membrane (ilm) peeling

Methods: Total of 28 patients enrolled for this study. 17 patients have undergone pars plana vitrectomy and erm peeling with ilm peeling, 11 were without ilm peeling. All patients were analysed with optic coherence tomography (OCT) and

optic coherence tomography angiography (OCTA), before surgery and 3 months after surgery. We evaluated preoperative and postoperative results of central macula thickness (CMT), vessel density (VD) of whole image, superior hemisphere, inferior hemisphere, fovea, parafovea and perifovea for both superficial and deep retinal capillary layer.

Results: There was no significant difference in OCTA parameters, between two groups, before and after surgery. Only postoperative CMT was significantly thinner in non-ILM group. In ILM group, there was no significant difference in OCT and OCTA parameters, before and after surgery. In non-ILM group, whole image and perifoveal VD was significantly decreased after surgery. Postoperative vision recovery is statistically significantly better in only erm peeling group.

Conclusion: All OCTA parameters were decreased after surgery in both groups. However, only some parameters in non-ILM group was statistically significant.

Keywords: epiretinal membrane, internal limiting membrane, optical coherence tomography angiography

[Abstract:0498]**Causes Of Failure In Pneumatic Retinopexy For Retinal Detachments**Umit U Inan¹, Ali Arslan², Elif Ertan Baydemir³, Sibel Inan⁴¹*Department of Ophthalmology, Can Hospital, Izmir, Turkey*²*Department of Ophthalmology, Parkhayat Hospital,**Afyonkarahisar, Turkey*³*Department of Ophthalmology, Basaksehir Cam Sakura City Hospital, Istanbul, Turkey*⁴*Department of Ophthalmology, Health Sciences University Bozoya Training and Research Hospital, Izmir, Turkey*

Purpose: We aimed to detect the causes of failure in patients with retinal detachment who underwent pneumatic retinopexy (PR).

Methods: Patients with retinal detachments due to a tear in the superior retina between the 3 and 9 o'clock quadrants were hospitalized overnight with the appropriate head position after the injection of 0.30 ml of C3F8 gas. Laser retinopexy was applied around the tear in patients whose retinas were attached. The unsuccessful cases were operated with vitreoretinal surgery. Age, gender, visual acuity and intraocular pressure, macular involvement, localization of detachment and tear, complications and additional surgical intervention data were analyzed retrospectively. The reasons for failure were investigated in cases where retinal attachment could not be achieved.

38 patients were included in the study. The mean age was 56.5±12.7 years (19M 19F). Anatomical success was achieved in 29 (76.3%). There was no significant difference in the mean age between the unsuccessful (57.8± 14.3 years) and the successful group (56.1± 12.4 years). There was a significant difference between symptom durations (successful group: 7.4± 9.5 days, unsuccessful group: 18.1± 21.2 days, p<=0.05). In

nine cases (23.7%), surgery was performed with vitreoretinal surgery after a period of 1-4 days, and 13% C3F8 was used as tamponade in all cases. The reasons for unsuccessful PR were the detection of a second tear that was missed in 1 case, the development of a new tear in the inferior quadrant in 2 cases, the detached retina extending to the inferior periphery in 3 cases, and inability to adapt to the head position in 3 cases.

Conclusion: Secondary tears that are overlooked or developed after the PR, the area being more than half of the retina, and the patient's inability to apply the head correctly were the most common causes of failure in our series.

Keywords: failure, pneumatic retinopexy, retinal detachment

PHOTO PRESENTATIONS

[Abstract:0092] PAC-MAN Eating Fovea

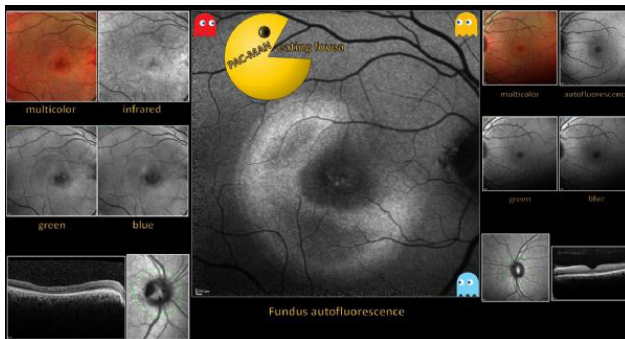
Mehmet Cem Sabaner, Mustafa Dogan, Muberra Akdogan,
Ayse Yesim Oral

Afyonkarahisar Health Sciences University, Faculty of Medicine,
Department of Ophthalmology, Turkey

Image of the patient (56 years, male) who was thought to have a spontaneous regressed of traumatic optic disc pit maculopathy in his right eye is attached. The patient had a history of blunt ocular trauma to the right eye in childhood. The left eye is completely normal. There is no surgical history. Although it is thought to have spontaneous fluid regression, there is an asymmetric ellipsoid zone loss due to optic pit maculopathy damage. Due to this asymmetric loss, a hyper-autofluorescence area was resembled “PAC-MAN” is observed in autofluorescence imaging.

Keywords: optic pit maculopathy, trauma, autofluorescence

PAC-MAN eating fovea



[Abstract:0094] Retinal Butterfly

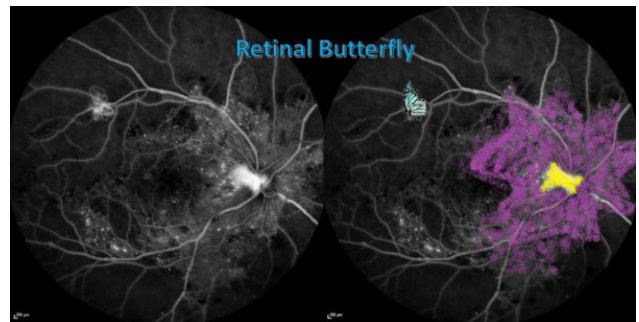
Mehmet Cem Sabaner, Mustafa Dogan, Muberra Akdogan,
Ayse Yesim Oral

Afyonkarahisar Health Sciences University, Faculty of Medicine,
Department of Ophthalmology, Turkey

In fundus fluorescein angiography imaging of a patient with diagnosed PDR, showed a protruding new vascular network (NVE) at the upper temporal arch; it was likened to a butterfly with antennnas and wings. The dense microaneurysms regions were likened to a flower, and the NVD was likened to the flower pollen.

Keywords: DRP, PDR, NVE

Retinal Butterfly



[Abstract:0099] The Intruder

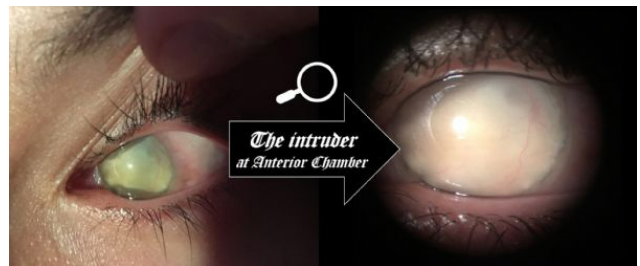Mehmet Cem Sabaner, Mustafa Dogan, Muberra Akdogan,
Ayse Yesim Oral

Afyonkarahisar Health Sciences University, Faculty of Medicine,
Department of Ophthalmology, Turkey

We report a 14-year-old female patient with left eye congenital glaucoma and Coats disease who had undergone vitrectomy and glaucoma surgery four times before. Total retinal detachment, and retina that migrated to the anterior segment were imaged (*The Intruder*). Direct photographing and anterior segment image from biomicroscope ocular were obtained with iphone 6s (Apple Inc., Cupertino, CA, USA) camera.

Keywords: telemedicine, camera, intruder

The intruder

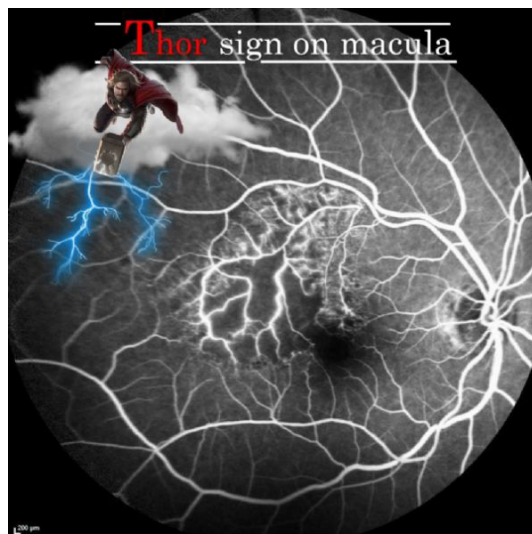


[Abstract:0100]

Thor sign on macula

Mehmet Cem Sabaner, Mustafa Dogan, Muberra Akdogan, Ayse Yesim Oral

Afyonkarahisar Health Sciences University, Faculty of Medicine, Department of Ophthalmology, Turkey

Thor sign on macula

[Abstract:0101]

Retinal Portal to Another Dimension

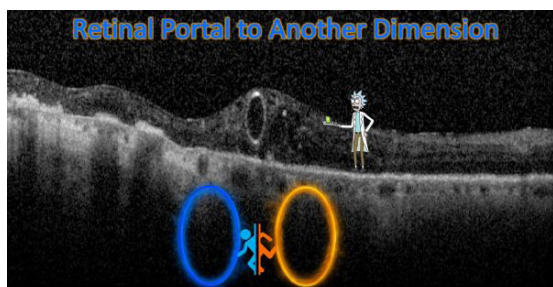Mehmet Cem Sabaner, Mustafa Dogan, Muberra Akdogan, Ayse Yesim Oral

Afyonkarahisar Health Sciences University, Faculty of Medicine, Department of Ophthalmology, Turkey

OCT image of the patient with PDR revealed an intraretinal anteroposterior oval macular lesion with hyperreflective surrounding and hyporefective content, similar to a *portal*. Aneurism? Cyst? PFCL? Outer retinal tubulation? Or opening door to another dimension?

Portal: https://www.youtube.com/watch?v=-cO_DIVuSyQ

Keywords: retina, PDR, oct

Portal

[Abstract:0114]

Venous vascular loop progression to neovascularization in a patient with diabetic retinopathy

Utku Limon

University of Health Sciences Umraniye Training and Research Hospital Eye Clinic Istanbul/Turkey

Venous vascular loop progression to neovascularization in a patient with diabetic retinopathy

Purpose: We describe a case characterized by the transformation of a venous vascular loop to neovascularization during a 3-month period in a patient with proliferative diabetic retinopathy.

Material-Methods: A 46-year-old female patient followed for proliferative diabetic retinopathy was presented for routine control. The left fundus examination showed a venous vascular loop at the superior temporal vascular arch. After 3 months of follow-up, it was observed that the venous vascular loop at the superior temporal vascular arch transformed into neovascularization.

Results: Venous loops are enlargements of veins in a loop shape to bypass the area of non-thrombotic occlusion.

Conclusion: Venous vascular loops are one of the rare manifestations of diabetic retinopathy. Venous vascular loops can transform into neovascularization, they should be followed carefully and retinal laser photocoagulation should be performed when necessary.

Keywords: venous vascular loop

Figure 1

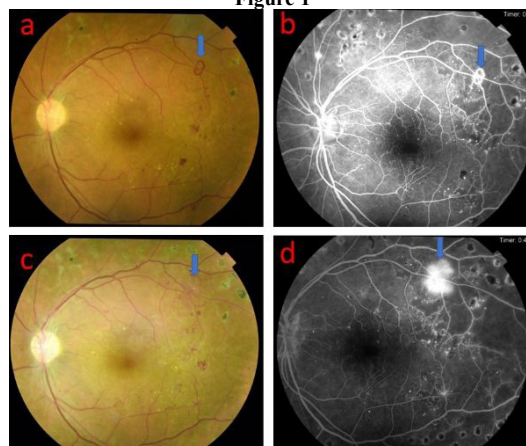


Figure-1: a. Color fundus image of the venous loop (blue arrow). b. Fundus fluorescein angiography image of the venous loop (blue arrow). c. Color fundus image of the patient after 3 months follow up. There is neovascularization on the side of the venous loop (blue arrow). d. Fundus fluorescein angiography image of the venous loop after 3 months follow-up (blue arrow). There is neovascularization on the side of the venous loop (blue arrow).

[Abstract:0115] The Trespassers - Double Crossing Congenital Retinal Macrovasculars

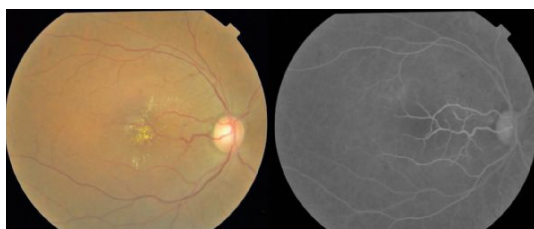Sangeet Mittal

Thind Eye Hospital, Jalandhar

Retinal vessels usually obey the horizontal raphe. Vessels originating superiorly remain superior and those originating inferiorly remain inferior. Congenital Retinal Macrovascular (CRM) is a rare anomaly in which a vessel crosses the horizontal raphe. This is an extremely rare condition and usually there is a single vessel present. In this case two macrovessels are seen criss-crossing each other. There is total absence of FAZ. Hard exudates are associated with these macrovessels. No previous reports of two CRMs in a single eye were found.

Keywords: Congenital Retinal Macrovascular, Vascular Anomaly, Fluorescein Angiography

Congenital Retinal Macrovascular - Double Cross



[Abstract:0116] Fruits of Von Hippel - Retinal Angiomas

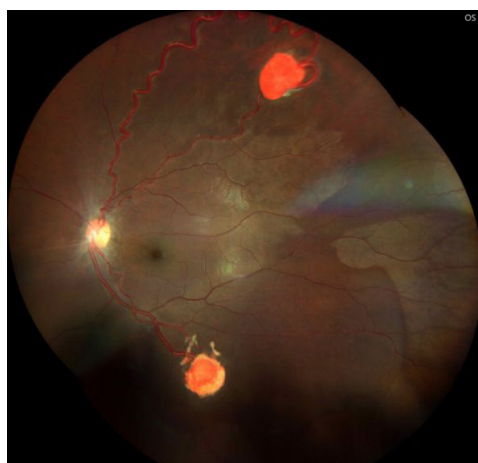Sangeet Mittal

Thind Eye Hospital, Jalandhar

21 year male presented with phthisis bulbi in right eye and angiomatosis retinae in left eye.

Keywords: Angiomatosis, Retinal Angioma

Angiomatosis



[Abstract:0117] The Mounds of Muller: Optic Nerve Head Drusens

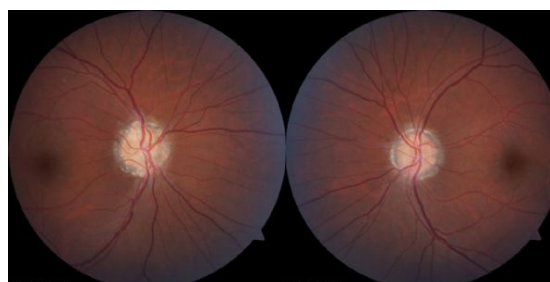
Sangeet Mittal

Thind Eye Hospital, Jalandhar

52-year male, referred for diagnosis of papilledema was seen to have exposed optic nerve head drusens in both eyes

Keywords: Optic Nerve Drusens, Papilloedema

ONH Drusens



[Abstract:0118] Blinding Break Up - Juvenile Retinoschisis

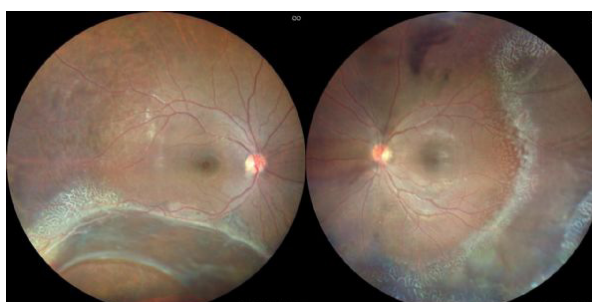Sangeet Mittal

Thind Eye Hospital, Jalandhar

Juvenile Retinoschisis is a rare congenital disease of retina caused by mutations in *RS1* gene. 10 year male presented with decrease of vision in both eyes. Foveal schisis noted as spoke wheel pattern radiating from the fovea is seen in both eyes. White flecks were seen scattered all over posterior pole. Peripheral retinoschisis with localized detachment was seen in both eyes. At the margin of schitic retina subretinal white linear spikes were seen.

Keywords: Juvenile retinoschisis, X-linked retinoschisis, Retinal detachment

Juvenile Retinoschisis



[Abstract:0126]

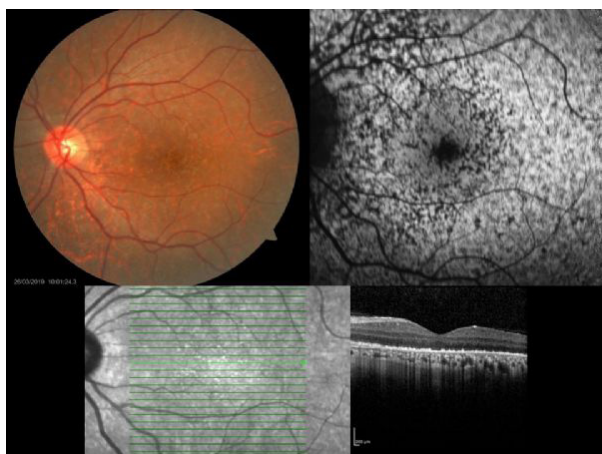
Suicide of The Outer RetinaYasin Sakir Goker

Goker Eye and Retina Center, Ankara, Turkey

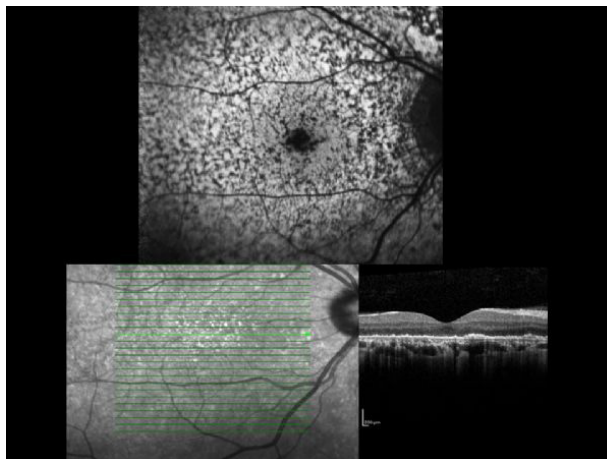
Purpose: To present long-term clinical course of a case of suicide by drinking iodine with the findings of multimodal imaging.

Case: A 42-year-old schizophrenic male patient who works in a salt factory presented to the emergency department with decreased vision in both eyes after a suicide attempt with drinking 2 glasses of pure iodine. Best corrected visual acuity was counting fingers from 2 meters bilaterally and anterior segment was unremarkable. In fundus examination, intense macular and peripheral RPE changes were observed in acute phase (Figure 1-2). In the FAF imaging of the patient, diffuse hypofluorescent islets due to RPE atrophies were present in the retina (Figure 1-2). In the SD-OCT imaging of the patient, diffuse RPE, ellipsoid zone (EZ) and ELM atrophies were observed (Figure 1-2). After 3 years, BCVA was evaluated as 20/200 in both eyes. Subretinal scar formation (Figure 3) was observed in infrared and SD-OCT imaging. High doses of iodine cause irreversible damage to the outer retina, resulting in long-term subretinal scar formation.

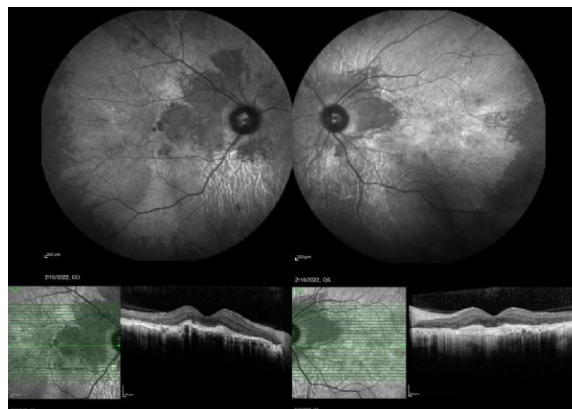
Keywords: Fundus autofluorescence, infrared imaging, iodide retinopathy

Figure 1

Fundus photograph of the left eye showed intense macular and peripheral RPE changes in acute phase. In the patient's FAF imaging, diffuse hypofluorescent islets due to RPE atrophies were present in the retina. On SD-OCT images, diffuse RPE, ellipsoid zone and external limiting membrane atrophies were observed in acute phase.

Figure 2

FAF and SD-OCT imaging of the right eye. Diffuse RPE, ellipsoid zone and external limiting membrane atrophies were also observed in this eye.

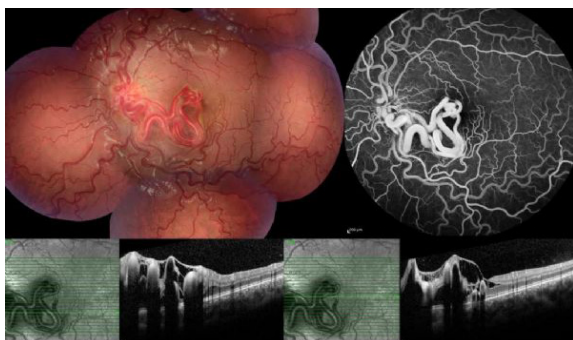
Figure 3

[Abstract:0152]**A Tortuous Condition: Retinal Racemose Hemangioma**Ece Özdemir Zeydanlı¹, Şengül Özdek², Refiye Basdogan¹¹Ankara Retina Clinic, Ankara, Turkey²Ophthalmology Department, Gazi University School of Medicine, Ankara, Turkey

Retinal racemose hemangioma, is a rare sporadic congenital arteriovenous malformation, with unilateral involvement. This photo demonstrates tangles of markedly dilated and tortuous vessels extending from the disc suggestive of racemose angioma that were incidentally found in the left eye on a routine ophthalmological examination of an 11-year-old girl. The best corrected visual acuity was 20/20 in both eyes. OCT showed hyporeflective intraretinal vascular lumens with back shadowing and fluorescein angiography showed rapid filling of the dilated artery and vein, without intervening capillaries and without any leakage into surrounding tissues.

Although retinal racemose hemangioma usually remains asymptomatic, it may rarely lead to retinal and vitreous hemorrhages, vascular occlusion, and secondary glaucoma. Some patients may harbor similar lesions in the brain, facial bones, and skin. Brain MRI should be requested to rule out this condition, known as Wyburn-Mason syndrome.

Keywords: retinal racemose hemangioma

Figure 1**[Abstract:0170]****Silicone Band Intrusion in Vitreous Cavity**

Hussain Khaqan

PGMI, AMC, LGH, Lahore

Purpose: To remove silicone band and manage the complications

Material-Methods: Total 4 cases, male, mean age 16 \pm 1 were included in this study, presented with silicone band intrusion after encircling buckle. Three eyes has associated retinal detachment. All eyes underwent 23 gauge PPV, cutting the band inside vitreous cavity, complete vitrectomy, air fluid oil exchange.

Results: All four eyes retina attached, in three eyes silicone oil

was removed after 04 months. Silicone band internal part has no complications, mean follow up is 18 months.

Conclusion: Cutting the silicone band inside the vitreous cavity with horizontal cutting scissor is novel & safe technique in experts hands to prevent the further complications.

Keywords: Silicone, Band, Intrusion

[Abstract:0230]**"Horseshoe" at the vitreal side of the posterior capsule?**

İmren Akkoyun, Dilek D Altınörs, Bahadır Azizagaoglu, Gülsah Gökgöz, Sibel Oto

Baskent University Faculty of Medicine, Department of Ophthalmology, Ankara, Turkey

7 years old boy with anterior posterior Persistent Fetal Vasculature (PFV).

Anterior segment: cataract, adhesive retinal pigment epithelium (RPE) at the vitreal side of the posterior capsule (PC) as extension of retinal tissue (pathological tissue analysis).

Posterior segment: stalk connecting the PC and optic nerve head, nasal peripheral retinal tissue including RPE with extension to the vitreal side of the PC, with tractional hyperpigmented retina in this area.

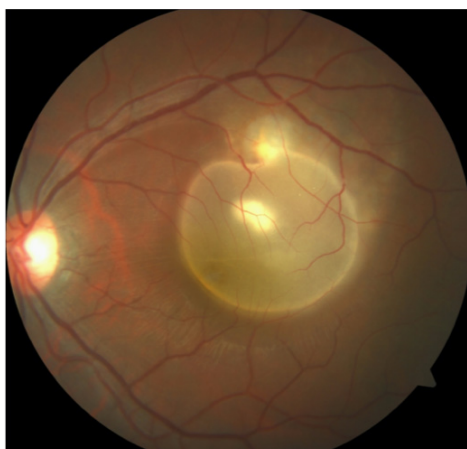
Proccede: extraction of cataract, sever of RPE including retinal tissue from the posterior capsule saving PC, pars plana vitrectomy, laserphotocoagulation, C3F8 implantation, sec. IOL implantation with posterior capsulorhexis.

Keywords: anterior PFV, Posterior PFV, vitrectomy

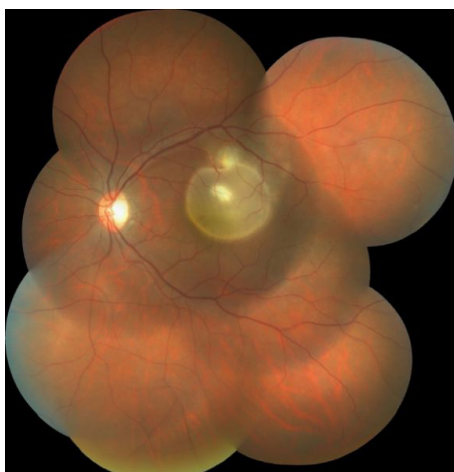
[Abstract:0253]**The Pearl in the Retina - Subretinal cysticercus cyst**Manisha Agarwal*Dr Shroff's Charity Eye Hospital*

A 30 year old young male presented with history of sudden diminution of vision in the left eye for past 10 days associated with headache. Fundus examination revealed a sub macular pearl white dome shaped lesion approximately 4 disc diameter in size with a visible dense white opacity (scolex). With these clinical findings, a submacular cysticercus cyst was thus diagnosed.

Keywords: cysticercus cyst

Pearl in the Retina

Color fundus photo of the left eye showing a sub macular pearl white dome shaped lesion approximately 4 disc diameter in size with a visible central dense white (scolex) suggestive of cysticercus cyst

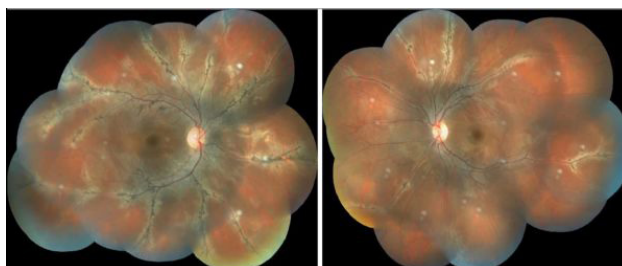Pearl in the Retina

Color fundus photo of the left eye showing a sub macular pearl white dome shaped lesion approximately 4 disc diameter in size with a visible central dense white opacity (scolex) suggestive of subretinal cysticercus cyst

[Abstract:0254]**Paravenous Chorioretinal atrophy (PPCRA)**Manisha Agarwal*Dr Shroff's Charity Eye Hospital*

A 14 year old male, presented to our clinic for regular ophthalmic examination. Both eyes best corrected visual acuity was 6/6, N6. The indirect ophthalmoscopic examination revealed an incidental finding in both eyes with patches of chorioretinal atrophy and pigment clumps along the veins consistent with pigmented paravenous chorioretinal atrophy (PPCRA) with early attenuation of retinal vessels, normal discs and macula. The patient was counselled and explained the nature of his condition. He was asked to be in yearly follow up.

Keywords: PPCRA

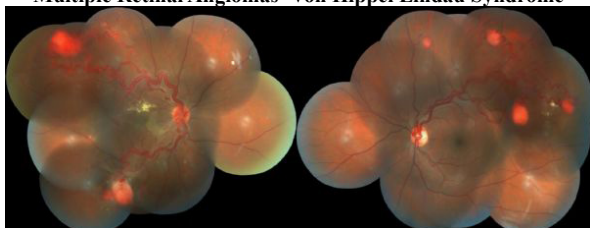Paravenous chorioretinal atrophy

Color fundus photo of both the eyes showing paravenous chorioretinal atrophy with attenuated retinal vessels

[Abstract:0255]**Multiple Retinal Angiomas- Von Hippel Lindau Syndrome**Manisha Agarwal*Dr Shroff's Charity Eye Hospital*

A 25 year old male presented with chief complaints of diminution of vision in right eye for past 2 weeks. Best corrected visual acuity in right eye was 6/12, N8 and left eye was 6/6, N6. Indirect ophthalmoscopy revealed thin epiretinal membrane causing traction over the macula in the right eye with both eyes showing multiple capillary hemangiomas. On PET- CT multiple metabolically inactive cystic lesions were noted in the pancreas and seminal vesicle with low grade metabolically active cystic lesion with enhancing septations present in kidneys which were suspicious for malignant etiology. MRI brain showed presence of a small cystic lesion anterior to cerebellar vermis suggestive of CNS hemangioblastoma. A diagnosis of Von Hippel-Lindau syndrome was made and the patient is under oncologist care for suspected RCC

Keywords: Von Hippel Lindau

Multiple Retinal Angiomas- Von Hippel Lindau Syndrome

Color fundus photo of both the eyes showing multiple retinal angiomas suggestive of Von Hippel Lindau with epiretinal membrane in the right eye

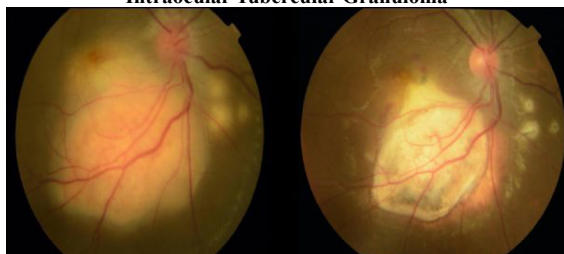
[Abstract:0256]**Intraocular Tubercular Granuloma**

Manisha Agarwal

Dr Shroff's Charity Eye Hospital

A 13 year young female presented to our opd with chief complaints of diminution of vision in her right eye. Her best corrected visual acuity on presentation was 6/60, N60. on indirect ophthalmic examination a large choroidal granuloma was noted along the inferotemporal arcade involving the posterior pole. CECT chest revealed presence of bilateral miliary Koch's parenchyma. Patient was started on oral antitubercular treatment and oral steroids along with weekly intravitreal injection of Avastin and Moxifloxacin. On week 4 complete regression of tuberculoma was noted with best corrected visual acuity of 6/9, N6.

Keywords: tubercular granuloma

Intraocular Tubercular Granuloma

Color fundus photo of the right eye showing a large active choroidal tubercular granuloma and then the regressed granuloma after treatment

[Abstract:0310]**A sanguine tale**

Monisha Apte, Manjula Shankar, Hemanth Murthy, Muralidhar Naveenam

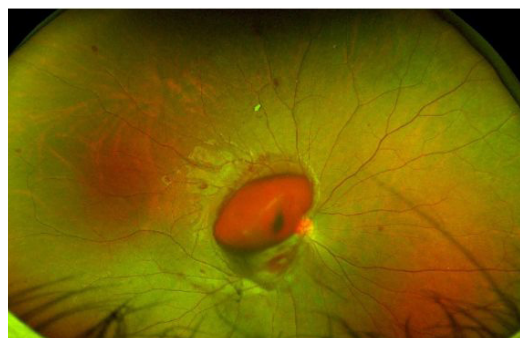Retina institute of Karnataka

A 26 year old otherwise healthy male presented with diminution of vision in right eye since 1 day. Best corrected visual acuity in right eye was counting fingers close to face. Examination showed quiet anterior chamber. Posterior segment examination showed premacular haemorrhage. Left eye examination was normal. Valsalva retinopathy was suspected and it was decided to observe aiming for spontaneous resolution. After 10 days YAG Capsulotomy was attempted. Examination after a week

showed improvement in vision to CF ½ metres with fundus examination showing resolving premacular haemorrhage with area of macular infarct with new blotchy haemorrhages along superotemporal arcade. Diagnosis of preretinal haemorrhage with occlusive retinal vasculitis was made and investigated thoroughly including TB. All systemic investigations came out to be normal. Fundus fluorescein angiography was done showing blocked fluorescence due to haemorrhage and with peripheral perivascular staining in the superotemporal quadrant with capillary non perfusion areas. He was started on a course of oral steroids at a dose of 40 mg/kg with gradual tapering. An extended thrombophilia testing was done for this patient which came out to be normal except for raised serum homocysteine levels. The patient was asked to continue oral steroids helping in improvement in visual acuity to Finger counting 3m with resolution of preretinal haemorrhage and resolving blotchy vasculitis haemorrhages

Conclusion: This case is unique as it presented as premacular haemorrhage which appeared to be Valsalva retinopathy but ultimately turning out to be occlusive vasculitis with hyperhomocystinemia being one of the predisposing factor

Keywords: haemorrhage

Sanguine Tale**[Abstract:0348]****Eye Looking Through Eye**

Mahmut Oğuz Ulusoy, Yusuf Duru, Tuğba Çağlar

Department of Ophthalmology, Bursa Yüksek İhtisas Research Hospital, Bursa, Turkey

During the fundus fluorescein angiography of 60 years old female patient with proliferative diabetic retinopathy, the 'eye' image was seen on one of the late phase photos.

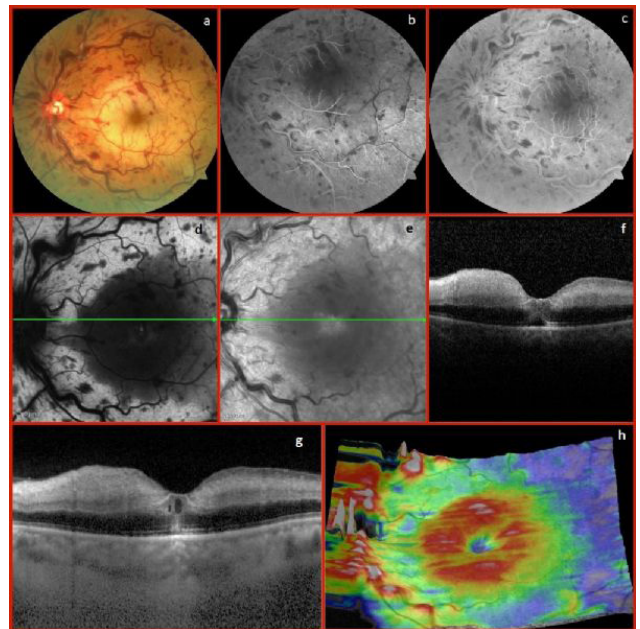
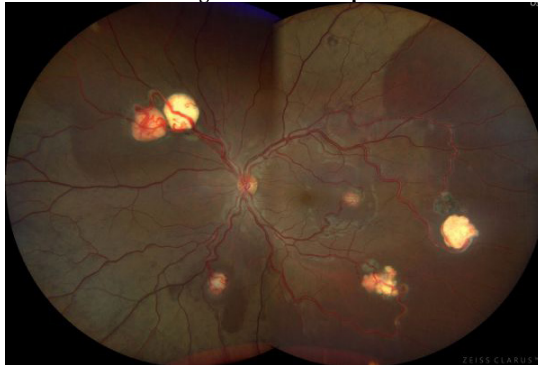
Keywords: fundus fluoroscein angiography

[Abstract:0406]**Strawberry Garden - Multiple Retinal Angiomas**Sangeet Mittal

Thind Eye Hospital, Jalandhar

24 year male presented with multiple retinal angiomas in left eye.

Keywords: Angiomatosis retinae

Angiomatosis Multiple

In this photographic presentation, multimodal images of a case with a combined central retinal artery and vein occlusion are presented and it is desired to draw attention to the appearance of the inner layer of the vascular retina in optical coherence tomography wide-angle mode and three-dimensional view. Picture 1 a- Color fundus photograph b- Fundus autofluorescence c- Fluorescein angiography in the early period d- Fluorescein angiography in the late period e- Infrared photography f- Spectral-domain optical coherence tomography imaging g- optical coherence tomography wide-angle and three-dimensional mode, the view of the inner layer of the retina

[Abstract:0482]**Flared and reddened inner retina in combined central retinal artery and vein occlusion**Mehmet Citirik

University of Health Sciences, Ankara Etlik City Hospital

In this photographic presentation, multimodal images of a case with a combined central retinal artery and vein occlusion are presented and it is desired to draw attention to the appearance of the inner layer of the vascular retina in optical coherence tomography wide-angle mode and three-dimensional view.

Picture 1

- a- Color fundus photograph
- b- Fundus autofluorescence
- c- Fluorescein angiography in the early period
- d- Fluorescein angiography in the late period
- e- Infrared photography
- f- Spectral-domain optical coherence tomography imaging
- g- optical coherence tomography wide-angle and three-dimensional mode, the view of the inner layer of the retina

Keywords: combined central retinal artery and vein occlusion, inner retina, imaging

Figure 1



European
VitreoRetinal
Society

