





An international collaborative evaluation of central serous chorioretinopathy: different therapeutic approaches and review of literature. The European Vitreoretinal Society central serous chorioretinopathy study

Mario R Romano,¹  Barbara Parolini,² Davide Allegrini,¹  Zosia Mickalewska,³ 
Ron Adelman,⁴ Stefanos Bonovas,⁵  Silvia Bopp⁶ and EVRS study group

¹Department of Ophthalmology, Gavazzeni - Castelli Hospital, Humanitas University, Rozzano, Italy

²Department of Ophthalmology, Istituto Clinico S. Anna, Brescia, Italy

³Department of Ophthalmology, Klinika Okulistyczna, Lodz, Poland

⁴Department of Ophthalmology, Yale University, New Haven, Connecticut, USA

⁵Department of Biomedical Sciences, Humanitas University, Pieve Emanuele, Milan, Italy

⁶Department of Ophthalmology & Visual Science, Yale University School of Medicine, New Haven, Connecticut, USA

ABSTRACT.

Purpose: To study and compare the efficacy of different therapeutic options for the treatment of central serous chorioretinopathy (CSCR).

Methods: This is a nonrandomized, international multicentre study on 1719 patients (1861 eyes) diagnosed with CSCR, from 63 centres (24 countries). Reported data included different methods of treatment and both results of diagnostic examinations [fluorescein angiography and/or optical coherent tomography (OCT)] and best-corrected visual acuity (BCVA) before and after therapy. The duration of observation had a mean of 11 months but was extended in a minority of cases up to 7 years. The aim of this study is to evaluate the efficacy of the different therapeutic options of CSCR in terms of both visual (BCVA) and anatomic (OCT) improvement.

Results: One thousand seven hundred nineteen patients (1861 eyes) diagnosed with CSCR were included. Treatments performed were nonsteroidal anti-inflammatory eye drops, laser photocoagulation, micropulse diode laser photocoagulation, photodynamic therapy (PDT; Standard PDT, Reduced-dose PDT, Reduced-fluence PDT), intravitreal (IVT) anti-vascular endothelial growth factor injection (VEGF), observation and other treatments. The list of the OTHERS included both combinations of the main proposed treatments or a variety of other treatments such as eplerenone, spironolactone, acetazolamide, beta-blockers, anti-anxiety drugs, aspirin, folic acid, methotrexate, statins, vitis vinifera extract medication and pars plana vitrectomy. The majority of the patients were men with a prevalence of 77%. The odds ratio (OR) showed a partial or complete resolution of fluid on OCT with any treatment as compared with observation. In univariate analysis, the anatomical result (improvement in subretinal fluid using OCT at 1 month) was favoured by age <60 years ($p < 0.005$), no previous observation ($p < 0.0002$), duration less than 3 months ($p < 0.0001$), absence of CSCR in the fellow eye ($p = 0.04$), leakage outside of the arcade ($p = 0.05$) and fluid height $>500 \mu\text{m}$ ($p = 0.03$). The OR for obtaining partial or complete resolution showed that anti-VEGF and eyedrops were not statistically significant; whereas PDT (8.5), thermal laser (11.3) and micropulse laser (8.9) lead to better anatomical results with less variability. In univariate analysis, the functional result at 1 month was favoured by first episode ($p = 0.04$), height of subretinal fluid $>500 \mu\text{m}$ ($p < 0.0001$) and short duration of observation ($p = 0.02$). Finally, there was no statistically significant difference among the treatments at 12 months.

Conclusion: Spontaneous resolution has been described in a high percentage of patients. Laser (micropulse and thermal) and PDT seem to lead to significant early anatomical improvement; however, there is little change beyond the first month of treatment. The real visual benefit needs further clarification.

Key words: central serous chorioretinopathy – laser – PDT

Acta Ophthalmol.

© 2019 Acta Ophthalmologica Scandinavica Foundation. Published by John Wiley & Sons Ltd

doi: 10.1111/aos.14319

Introduction

Central serous chorioretinopathy (CSCR) is an acquired chorioretinal disorder that was first described by Von Graefe in 1866 as recurrent central syphilitic retinitis. (Kitzmann et al. 2008) It is characterized by serous detachment of the neurosensory retina, usually at the posterior pole. The incidence is greater in men than women (Kitzmann et al. 2008) between the ages of 20 and 50 years (Gass 1977; Gilbert et al. 1984; Yannuzzi 1986).

The aetiology of CSCR is unknown, but the pathogenesis seems to involve dysfunction of the choroid (the major blood vessel complex feeding the outer portion of the retina) and retinal pigment epithelium (RPE) (Prünte & Flammer 1996). The current hypothesis of the pathophysiology of CSCR is that choroidal vascular hyperpermeability is the principal cause of the increased tissue hydrostatic pressure beneath the RPE that eventually leads to disintegration of the RPE (Uyama et al. 1999).

The location and amount of subretinal fluid determine what symptoms are experienced. Central serous chorioretinopathy (CSCR) is commonly associated with fluid accumulation under the macula as well as the detachment of the neurosensory retina (Wang et al. 2008). When the detachment occurs in the central macula, the most common clinical features are reduction in best-corrected visual acuity (BCVA), metamorphopsia, micropsia, blurred vision and mild dyschromatopsia. There may be no symptoms when the fluid is located outside the macula.

One diagnostic tool for CSCR is fluorescein angiography (FA) that shows typical focal leakage spots (Bujarborua et al. 2010). At late stages of CSCR, it is possible to observe dye pooling in the sub-RPE space. Another tool is indocyanine green angiography (ICGA), which may show the dilated choroidal vasculature corresponding with choroidal hyperpermeability in

the late phase of CSCR (Spaide et al. 1996; Iida et al. 1999). Optical coherent tomography (OCT) can demonstrate neurosensory retinal detachment and areas of pigment epithelium detachment. Enhanced depth imaging OCT in the areas corresponding to the neurosensory retinal detachment was found to be thicker, providing additional evidence that CSCR may be caused by increased hydrostatic pressure in the choroid (Imamura et al. 2009).

The natural history of CSCR in most patients is self-limiting (Klein et al. 1974). Subretinal fluid may disappear in 2–3 months without any treatment, and the prognosis is often good. Therefore, observation may be utilized instead of treatment during the first months of onset. Cases that do not resolve spontaneously might turn into chronic CSCR.

There have been different therapies for CSCR. At present, there is no consensus on the management of CSCR. The aim of this study is to compare the relative effectiveness of interventions for this disorder.

Material and Methods

The European Vitreoretinal Society (EVRS) CSCR Study was a nonrandomized, observational multicentre study in which the goal was to analyse the effects of various treatments for CSCR on functional and anatomical outcomes.

The research adhered to the tenets of the Declaration of Helsinki. Members of EVRS contributed to the study by reporting on individual cases of CSCR and their management from 2006 to 2015. A portal was created on the EVRS website where reporting questionnaires were available to be filled out for each patient treated. At the end of the reporting period, the study organizers received complete data on 1719 patients (1861 eyes) diagnosed with CSCR from 63 centres (24 countries). The results were analysed

independent of investigators by the Prof. Stefanos Bonovas, Department of Biomedical Sciences, Humanitas University, Milan.

Central serous chorioretinopathy (CSCR) was defined as idiopathic serous retinal detachment in the macular area associated with RPE changes or leakage on FA. The inclusion criterion was diagnosis of CSCR, and the exclusion criterion was any eye surgery in the 6 months prior to diagnosis of CSCR.

Patients' age, gender, refractive error and first episode or recurrence of CSCR were recorded. At baseline, all patients had a complete ophthalmological examination, including measurements of BCVA and intraocular pressure by Goldmann tonometry, slit-lamp examination, FA and OCT. The questionnaire also asked patients about the presence of concomitant systemic pathologies and whether they were considered a high-stress personality.

For patients with CSCR, the questionnaire predetermined to choose certain treatment options: topical eye drops, laser photocoagulation, micropulse diode laser photocoagulation, photodynamic therapy (PDT; standard PDT, reduced-dose PDT and reduced-fluence PDT), intravitreal (IVT) anti-vascular endothelial growth factor (VEGF), observation or 'other treatment'. Other treatment could vary from combinations of the main proposed treatments to completely different treatments such as eplerenone, spironolactone, acetazolamide, beta-blocker, anti-anxiety drugs, aspirin, folic acid, methotrexate, statins, vitis vinifera extract medication and pars plana vitrectomy. At baseline and 1, 3, and 12 months after treatment, BCVA was measured and OCT was performed. At the final time point, BCVA was measured, OCT was used and FA in some cases.

The regulations and institutional review board requirements were different in each of the 24 countries. Every

Table 1. Characteristics of the study population (*n* = 1719).

Gender		
Female	393/1719 (22.9%)	
Male	1326/1719 (77.1%)	
Ethnic group		
Caucasian	1242/1719 (72.3%)	
Asian	368/1719 (21.4%)	
African	1/1719 (0.1%)	
Middle Eastern	65/1719 (3.8%)	
Indian	43/1719 (2.5%)	
Precipitating factors		
Unknown	1043/1719 (60.1%)	
Missing	116/1719 (6.7%)	
Stressed personality	552/570 (96.8%)	
Pregnancy	7/570 (1.2%)	
Systemic disorders		
Hypertension	253/1719 (14.7%)	
Diabetes mellitus	51/1719 (3.0%)	
Cardiac disorders	17/1719 (1.0%)	
Renal failure	9/1719 (0.5%)	
Malignancy	15/1719 (0.9%)	
Bone marrow transplantation	2/1719 (0.1%)	
Steroid treatment received during the last 6 months	134/1719 (7.8%)	Systemic, 80% Intravitreal, 1% Periocular, 7% Topical, 12%

participant was responsible for following the rules and regulations of each individual country and institution. In addition, the EVRS Ethics and Study Design Committee approved the design and ethical aspects of the study.

After cleaning the database, a global worksheet was sent to each contributor, masking the name of the other contributors, so that cleaning accuracy could be agreed upon.

Patients

This is an observational, retrospective cohort study of 1719 patients (1861 eyes) diagnosed with CSCR, from 63 centres (24 countries). Each centre contributed an average of 27.3 patients (median, 16; range, 2–185). The CSCR diagnosis was confirmed by FA or OCT in all patients. The majority of patients were men (77.1%) and of Caucasian race (72.3%). The characteristics of the study cohort are summarized in Table 1. The patient cohort was followed up for [mean ± SD; median (interquartile ranges (IQR))] 18.1 ± 15.6; 14 (6–24) months.

Seven-hundreds seventy-one cases came from Turkey, South Korea and Germany. Poland and Italy accounted for more than 50% of cases; therefore, Asia and Europe were mainly represented.

The mean age of patients was 47.0 ± 10.4. The average age for men was 46 and for women was 40.

For 57% of patients, there were not reported data relating to the presence of systemic diseases. Among the 26% of patient for whom we have information, hypertension was reported in more than 70% of them. Only for 33.2% of patients we have information about the contributing factors (60.1% unknown and 6.7% missing), and the majority (96.8%) of this 33.2% were reported to have type A personality. Although steroid use is known to be one of the risk factors, in this group the vast majority had not used steroids in the previous 6 months. Among the 8% that reported steroid use, the majority had systemic use.

Among the 1861 eyes diagnosed with CSCR, it was the first episode for 68% of participants. The estimated duration of the episode had high variation (<3 months in 48%, 3–6 months in 19%, more than 6 months in 25%, unknown in 8%). In 27% of cases, the fellow eye demonstrated residues of previous CSCR episodes. With regard to the refractive status at initial presentation of CSCR, myopia (20%), hyperopia (32%), emmetropia (35%) or unknown (13%) were reported. Visual acuity (VA) at presentation was [mean ± SD; median (IQR)] 0.26 ± 0.25; 0.2 (0.1–0.4).

Among those where FA was used (1493 eyes), 1–2 focal leakage areas were shown in 69% of cases, 3 or more in 15% and diffuse leakage in 16%.

The leak was within the arcade in 87% of the eyes, while it extended outside the arcade less frequently (13%). Other findings were RPE detachment (49%), window defects (46%) and choroidal neovascularization (CNV, 4%). Among those where OCT was used (1836 eyes), subfoveal fluid was shown in 94%, while the height of retinal detachment had high variation (<50 µm in 8% of cases, 50–100 µm in 13%, 100–200 µm in 25%, 200–500 µm in 46% and more than 500 µm in 8%). Other findings were RPE detachment (71%), CNV (4%) and other retinal pathologies (25%). Only about 10% of cases had simultaneously bilateral involvement. For both women and men, it was the first episodes in almost 70% of cases while it was a recurrence for 30% of them. The number of episodes was 2–4.

The first treatment was anti-VEGF medications in 164 cases (Avastin 143, Lucentis 19 and Eylea 2; 8.8% in total); thermal laser in 219 (11.8%), PDT in 341 (18.3%), micropulse laser in 37 (2.0%), topical eye drops in 292 (15.7%), other treatments in 358 (19.2%) and observation (no therapy) in 450 (24.2%). Those eyes undergoing PDT were treated as follows: full-dose, 12%; half-dose, 38%; half-fluence, 31%; FA-guided, 1%; ICGA-guided, 6% and unknown, 11%.

Statistical methods

Summary statistics are presented with means ± standard deviations (SD), medians and IQR or percentages when appropriate. The Shapiro–Wilk test was used to determine if the variables of interest were normally distributed. Nonparametric methods (the Wilcoxon matched-pairs signed-ranks test, the Pearson chi-squared test and the Kruskal–Wallis [equality-of-populations] rank test) were used for the statistical evaluations.

For hypothesis testing, a probability level lower than 0.05 was considered to be statistically significant. All statistical tests were two-sided. Stata software was used for all statistical analyses (Stata Corp., College Station, TX, USA).

Results

Data on VA measurements, OCT results and further treatments received were collected and analysed (Table 2).

Visual acuity (VA) was statistically significantly lower at 1, 3 and 12 months, and at the final follow-up compared with baseline. In total, an average of 0.6 recurrences per patient (median, 0; IQR, 0–1) was reported.

The relatively large number of treatment options available for CSCR and the lack of standardization in the integration of these treatment regimens presented some challenges. Given these limitations, we decided to present the results as trend lines displaying improvement in VA and retinal thickness over time. The trend lines, therefore, can be used to classify the efficiency of each treatment and must be considered as indicators of comparative results; they are not a precise measure of exact number of lines of improvement in vision.

Anatomical results

In univariate analysis, the anatomical result (change in subretinal fluid using OCT at 1 month) was favoured by age <60 years ($p < 0.005$), no previous observation ($p < 0.0002$), duration <3 months ($p < 0.0001$), absence of CSCR in the fellow eye ($p = 0.04$), FA leakage outside the arcades ($p = 0.05$) and fluid height >500 μm ($p = 0.03$). In multivariate analysis, the anatomical result was favoured by age <60 years ($p = 0.03$), duration <3 months ($p < 0.0001$), FA outside the arcade ($p = 0.02$), fluid height >500 μm ($p = 0.005$) and any treatment versus observation. Furthermore, the use of thermal laser, micropulse, PDT is superior to anti-VEGF, others and drops therapy.

The OR for obtaining partial or complete resolution (95% confidence limits) between treatment versus observation show that anti-VEGF and eye-drops did not show a statistically significant effect. Instead, PDT (8.5), thermal laser (11.3) and micropulse laser (8.9) lead to better anatomical results and with less variability.

The analyses of the time-points of 3 and 12 months do not show any significant variation with respect to 1 month when considering one single treatment at baseline and no change of treatment.

Functional results

In univariate analysis, the functional result (change in VA at 1 month) is

favoured by first episode ($p = 0.04$), height of subretinal fluid >500 μm ($p < 0.0001$) and short duration of observation ($p = 0.02$). In multivariate analysis, the same functional result is favoured by the first episode, subfoveal fluid height >500 and any treatment.

There was a statistically significant different pattern of VA at the four time-points for the five considered treatments (interaction of time by treatments: $p = 0.0037$). For all treatments, there was a statistically significant increase in VA from baseline; there is a curvilinear trend with a significant improvement in VA between baseline and 3 months. Instead from 3 and 12 months there is a slight decrease in VA for thermal and micropulse laser, practically no change for PDT and anti-VEGF, and a further slight increase for observation and topical eye drops. Finally, there was no statistically significant difference among any of the treatments at 12 months.

It seems that every choice brings an improvement around 1 logMar line, but the variability of results is very wide for every treatment (Figs 1 and 2).

Summary statistics for pre- and posttreatment VA and OCT and respective changes by treatment group are presented in Table 2. Results (VA and OCT) differed between the treatment groups. However, these comparisons should be interpreted with great caution for several reasons: the study was retrospective and observational (i.e., not randomized), VA was different between treatment groups at baseline, and there were a lot of missing values.

Discussion

The treatment of CSCR is much debated in the literature, and it is not clear whether, when and how it should be treated. This is the first collaborative international study investigating a large number of patients (1719 patients, 1861 eyes).

Regards the study population, the wide range of patient's age (20–83 years) could open the discussion on differential diagnosis between age-related macular degeneration (AMD) and late-onset CSCR or just residues of CSCR in older patients who had had CSCR at a younger age. Therefore, taking into account the advanced age of

a small minority of patients and that ICGA examination for differential diagnosis was not required for study inclusion, their diagnosis may be a matter of dispute.

Fifty-seven percent of patients could not identify concomitant disorders, which may be because ophthalmologists did not collect a thorough medical history. Central serous chorioretinopathy (CSCR) is a disease that is known to occur mainly in patients with good health. However, among the 26% of patient for whom we had information, hypertension was reported in more than 70%. In Europe, the prevalence of hypertension is 35–45% and in South Korea it is 25% (Singh et al. 2000; Mancina et al. 2013). Therefore, in the CSCR group, the prevalence is high.

The estimated duration of the disease at presentation to the doctor was usually less than 3 months. Most of the eyes were emmetropic, whereas only 26% were hyperopic. As previously shown, a diagnosis can be made just with OCT; however, more than 80% of physicians performed FA to confirm the diagnosis. A limitation of this study is that ICGA was not required. The reported cases were mostly confined within the arcades and limited to 1 or 2 spots visible in FA.

Information related to 'other findings' was only available for 30% of patients. In some of these cases, CNV was detected, which may have led to the problem of differential diagnosis with AMD. They could be cases of CNVs or polypoidal choroidal vasculopathy that simultaneously appeared after previous treatment. No ICGA exams were required in the study, so AMD cases may have been incorrectly diagnosed as CSCR.

Considering that current study is not a randomized trial, there is a risk of selection bias with regard to the cases reported on by each physician. Based on the recommendation by the Institute of Statistics of Humanitas University, this risk was limited by always comparing the results obtained with different treatment modalities as opposed to presenting individual values of visual improvement at different time-points along the trend lines. Furthermore, the large number of reported cases and participating physicians in each treatment group worked to reduce selection bias.

Table 2. Summary statistics for pre- and posttreatment VA and OCT and respective changes by treatment group.

	Anti-VEGF (n = 164)	Thermal laser (n = 219)	PDT (n = 341)	Micropulse laser (n = 37)	Topical eye drops (n = 292)	Other therapies (n = 358)	No therapy (n = 450)	Total cohort (n = 1861)	Comparison between groups (p)
Baseline									
VA measurement	0.36 ± 0.28; 0.3 (0.2–0.5)	0.26 ± 0.22; 0.2 (0.1–0.3)	0.31 ± 0.26; 0.3 (0.1–0.4)	0.23 ± 0.22; 0.2 (0.1–0.3)	0.24 ± 0.24; 0.2 (0.1–0.3)	0.26 ± 0.23; 0.2 (0.1–0.4)	0.22 ± 0.26; 0.2 (0.1–0.4)	0.26 ± 0.25; 0.2 (0.1–0.4)	<0.001
Month 1									
VA measurement	0.29 ± 0.25; 0.2 (0.1–0.4)	0.15 ± 0.18; 0.1 (0.0–0.2)	0.25 ± 0.25; 0.2 (0.1–0.4)	0.16 ± 0.21; 0.1 (0.0–0.3)	0.20 ± 0.23; 0.1 (0.0–0.3)	0.21 ± 0.20; 0.2 (0.1–0.3)	0.22 ± 0.29; 0.1 (0.0–0.3)	0.22 ± 0.24; 0.2 (0.1–0.3)	<0.001
Comparison versus baseline (p)	<0.001	<0.001	<0.001	<0.001	<0.001	<0.001	<0.001	<0.001	
OCT: CR/PR/NC (%)	12/58/30	42/50/8	53/38/9	48/41/10	17/58/26	15/59/26	15/39/46	27/49/24	<0.001
New treatment (%)	41	4	11	3	23	18	16	17	<0.001
Month 3									
VA measurement	0.25 ± 0.24; 0.2 (0.1–0.4)	0.13 ± 0.20; 0.1 (0.0–0.2)	0.22 ± 0.24; 0.1 (0.0–0.3)	0.15 ± 0.25; 0.1 (0.0–0.2)	0.17 ± 0.23; 0.1 (0.0–0.2)	0.18 ± 0.20; 0.1 (0.0–0.3)	0.17 ± 0.25; 0.1 (0.0–0.2)	0.18 ± 0.23; 0.1 (0.0–0.3)	<0.001
Comparison versus baseline (p)	<0.001	<0.001	<0.001	0.005	<0.001	<0.001	<0.001	<0.001	
OCT: CR/PR/NC (%)	32/40/29	71/22/7	59/31/10	70/19/1	43/40/17	33/17/30	36/39/25	46/35/19	<0.001
New treatment (%)	48	16	20	0	26	21	14	23	<0.001
Month 12									
VA measurement	0.23 ± 0.24; 0.1 (0.1–0.3)	0.14 ± 0.21; 0.1 (0.0–0.2)	0.20 ± 0.26; 0.1 (0.0–0.3)	0.31 ± 0.39; 0.1 (0.1–0.5)	0.14 ± 0.21; 0.1 (0.0–0.2)	0.17 ± 0.24; 0.1 (0.0–0.2)	0.13 ± 0.21; 0.1 (0.0–0.2)	0.17 ± 0.24; 0.1 (0.0–0.2)	<0.001
Comparison versus baseline (p)	<0.001	<0.001	<0.001	0.55	<0.001	<0.001	<0.001	<0.001	
OCT: CR/PR/NC (%)	51/28/21	72/23/5	69/24/7	57/14/29	70/16/14	62/26/12	49/30/21	63/24/13	<0.001
New treatment (%)	31	28	16	11	15	13	10	17	<0.001
Last follow-up									
VA measurement	0.23 ± 0.27; 0.1 (0.0–0.3)	0.12 ± 0.21; 0.0 (0.0–0.2)	0.21 ± 0.27; 0.1 (0.0–0.3)	0.17 ± 0.26; 0.1 (0.0–0.2)	0.13 ± 0.19; 0.1 (0.0–0.2)	0.16 ± 0.24; 0.1 (0.0–0.2)	0.15 ± 0.22; 0.1 (0.0–0.2)	0.17 ± 0.24; 0.1 (0.0–0.2)	<0.001
Comparison versus baseline (p)	<0.001	<0.001	<0.001	0.002	<0.001	<0.001	<0.001	<0.001	
Recurrences	1.00 ± 1.49; 1 (0–1)	0.66 ± 0.99; 0 (0–1)	0.63 ± 1.05; 0 (0–1)	0.25 ± 0.44; 0 (0–0.5)	0.85 ± 1.17; 0 (0–1)	0.29 ± 0.63; 0 (0–0)	0.51 ± 0.87; 0 (0 –1)	0.60 ± 1.02; 0 (0–1)	<0.001
Persistence (%)	45	20	18	35	28	42	39	32	<0.001
SFH in OCT	125 ± 127; 95 (0–238)	31 ± 67; 0 (0–30)	123 ± 128; 83 (0–214)	214 ± 114; 234 (177–277)	105 ± 115; 75 (0–200)	156 ± 132; 174 (0–256)	63 ± 94; 0 (0–90)	108 ± 123; 54 (0–214)	<0.001
A/FL/DL/NS in FA (n = 274)	38/19/19/23	44/22/9/25	48/18/13/21	50/17/33/0	31/15/8/46	31/29/27/13	52/14/19/15	42/19/16/22	0.035

Data are presented as means ± standard deviations; medians and interquartile ranges in parentheses, or percentages when appropriate. Nonparametric methods (Wilcoxon matched-pairs signed-ranks test; Pearson chi-squared and Kruskal–Wallis [equality-of-populations] rank test) were used for the statistical evaluations.

A/FL/DL/NS = atrophy/focal leakage/diffuse leakage/no scar, CR/PR/NC = complete resolution/partial resolution/no change, FA = fluorescein angiography, OCT = optical coherence tomography, PDT = photodynamic therapy, SFH = subfoveal fluid height, VA = visual acuity, VEGF = vascular endothelial growth factor.

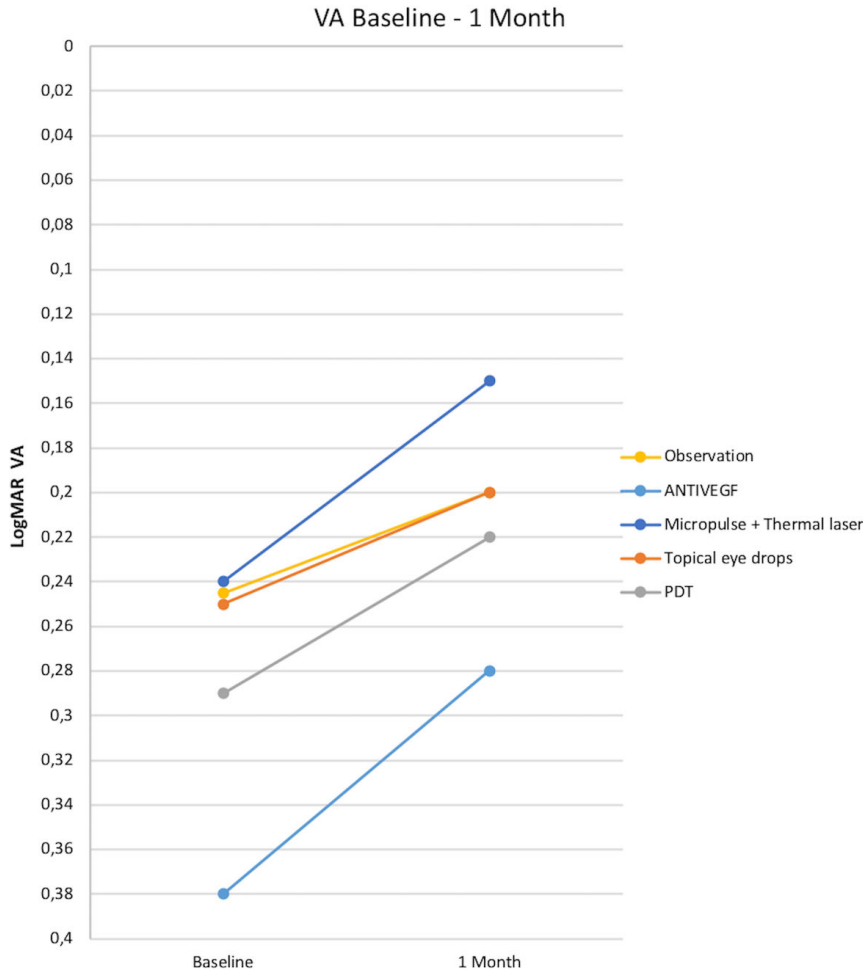


Fig. 1. Improvement in BCVA from baseline to 1 month.

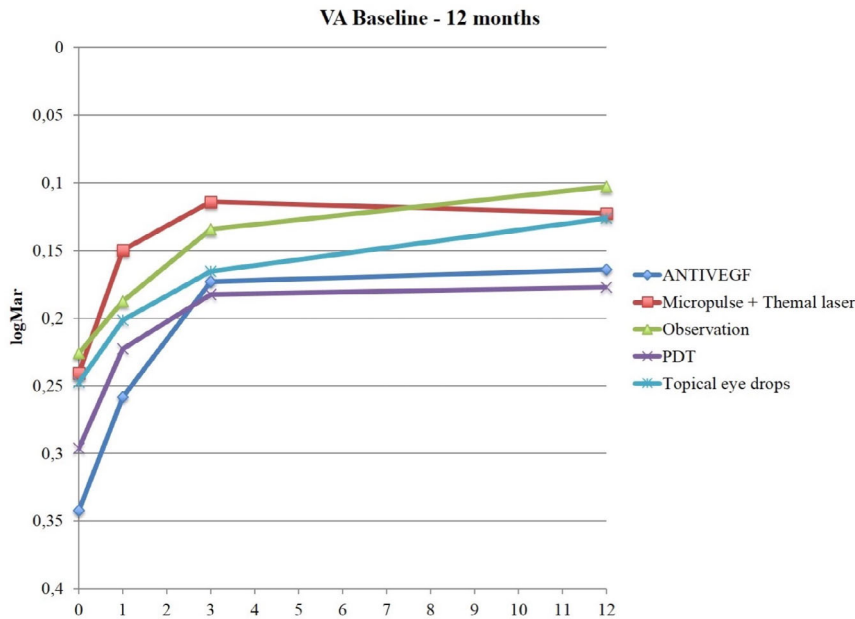


Fig. 2. Improvement in BCVA from baseline to 12 months.

The analysis of combinations of treatments is not presented due to a difficult statistical interpretation and missing data.

Argon laser treatment

Focal photocoagulation can occlude leaks through defects in Bruch's

membrane. Lower intensity laser with longer duration and moderate spot size (100–200 μm) reduce the risk of rupture of Bruch's membrane, development of CNV and progressive atrophy of the area of the laser treatment (Robertson & Ilstrup 1983). Usually, laser spots have as a target the focal leakage spot, which has been identified in FA and which is the point from which the subretinal fluid originates.

Spitznas hypothesized an inversion of fluid transport across the anomalous RPE from the choroid towards the neuroretina. (Miller & Farber 1984; Spitznas 1986) Photocoagulation could lead to the improvement of CSCR by obliterating the anomalous focus of RPE leading to a migration of adjacent epithelial cells towards the treatment site and repairing the area of focus 'leakage'.

Focal photocoagulation of the leakage spots does not affect VA negatively (Leaver & Williams 1979; Robertson & Ilstrup 1983). Robertson & Ilstrup (1983) showed that there was a reduction in CSCR recurrences and duration of the presence of subretinal fluid with direct argon laser treatment compared with sham after 18 months of observation. In a review, it was emphasized that argon laser treatment is effective when the focal leakage in FA is extrafoveal. If it is juxta- or subfoveal, there is the risk of injury to the foveal photoreceptors (Wang et al. 2008).

Controversely, Dellaporta (1976) observed that recurrences were 3.3 times more frequent in treated eyes compared with untreated. Gilbert et al. (1984) have performed a retrospective study on CSCR patients treated with argon laser photocoagulation and untreated eyes and showed no difference in VA and recurrence rate between the two groups. The discordant results of these studies could be explained by different follow-up time and treatment techniques. Robertson (1986) proposed an early laser photocoagulation when VA is 20/40 or less to reduce recurrences. Wang recommended an early argon laser treatment regardless of VA to shorten the duration of CSCR symptoms (Wang et al. 2008).

In a prospective randomized trial of argon laser photocoagulation in the management of CSCR, long-term follow-up (6.4–12.1 years) revealed no evidence that treatment significantly

influenced visual outcomes. Treatment did not reduce either the recurrence rate or the prevalence of chronic disease. The justification for argon laser photocoagulation appears to be limited to the hastening of symptomatic relief by earlier resolution of serous detachment (Ficker et al. 1988).

The OR (11.3) for obtaining a partial or complete resolution with argon laser treatment compared with observation showed statistically significant results in favour of photocoagulation treatment. Best-corrected VA (BCVA) improved from baseline to 1 month and then decreased from 3 months to 12 months (Figs 1 and 2). The number of recurrences at 1 year was fewer than in the observation group. The percentage of persistent CSCR in the argon laser group at the end of the follow-up was better than in the observation group, 20% and 39%, respectively (Table 2).

Limits to evaluate the role of the laser treatment in our study were that no differentiation was made in subgroups for the different types of lasers (green, red and yellow), and no standard parameters were used for the treatment (spot diameter and treatment area).

Photodynamic therapy with verteporfin

Verteporfin PDT has been recommended to treat acute CSCR and to avoid recurrences (Nicholson et al. 2013). The mechanism of PDT treatment in chronic forms is not known. It is supposed that PDT acts in CSCR by inducing choroidal hypoperfusion, vascular narrowing and remodelling in order to negate choroidal hyperpermeability which is often found in CSCR, ultimately leading to a reduction in choroidal congestion, vascular hyperpermeability and extravascular leakage (Chan et al. 2003a,b). Others have proposed that PDT also contributes to repair the blood-retina barrier (Tarrantola et al. 2008). PDT therapy is effective on the permeability and perfusion of the choroid; therefore, it has been used in the treatment of CSCR (Husain et al. 1999; Chan et al. 2003a,b). This aspect has been shown by Maruko, who described reduction in choroidal thickness and hyperpermeability in ICGA after PDT (Maruko et al. 2010).

Photodynamic therapy (PDT) usually is applied in cases of CSCR inside

the arcades or in cases that have not benefitted from other treatments or observation. PDT complications are dose-dependent and consist of CNV, choriocapillaris ischaemia, RPE tear and development of RPE atrophy (Schlötzer-Schrehardt et al. 2002; Schmidt-Erfurth et al. 2002; Cardillo Piccolino et al. 2003). Some authors have reported on studies of CSCR the use of PDT therapy with modified parameters, such as reduced dose of verteporfin, time of exposure and fluency, so as to reduce the risk while maintaining the treatment benefit (Lai et al. 2006; Chan et al. 2008; Reibaldi et al. 2010).

Photodynamic therapy (PDT) therapy is effective on the permeability and perfusion of the choroid; therefore, it has been used in the treatment of CSCR (Husain et al. 1999; Chan et al. 2003a,b). This aspect has been shown by Maruko, who described reduction in choroidal thickness and hyperpermeability in ICGA after PDT (Maruko et al. 2010).

Cases of CSCR patients were described, which after conventional PDT therapy (in accordance with the Treatment of Age-related Macular Degeneration with PDT guidelines) (1999 presented transient reduction in macular function by mERG, showed RPE atrophy or developed a CNV (Cardillo Piccolino et al. 2003; Chan et al. 2003a,b; Lai et al. 2004; Tzekov et al. 2006).

Lai has used modified parameter for PDT treatment, both the verteporfin dosage and the time between its administration and execution of the laser, and demonstrated to reduce collateral damage and maintain the same effectiveness (Lai et al. 2006). Zhao et al. (2009) observed that 30% of the standard dose was the minimum amount of verteporfin to maintain the same treatment effectiveness as the full dose.

In a prospective nonrandomized study, Reibaldi compared standard PDT with low-fluence PDT, the latter with reduced energy/exposed area/exposure time. Results of the 2 groups were similar in terms of the disappearance of subretinal fluid and improvement in VA (Reibaldi et al. 2010).

In our study, the OR (8.5) for obtaining a partial or complete resolution with PDT treatment compared with observation showed statistically significant results in favour of PDT.

BCVA improved from baseline to 1 month, but there was practically no change from 3 to 12 months (Figs 1 and 2). The number of recurrences at 1 year was less compared with the observation group. The percentage of persistent CSCR in the PDT group at the end of the follow-up was inferior to all the groups studied and was 18% (Table 2).

Many aspects are unclear: the efficacy and safety of a specific setting of the PDT protocol, the studies' outcomes refer to a relatively short-term follow-up, moreover, the effects of PDT on chorioretinal atrophy, the role of PDT on the rate of recurrences and the cumulative effect of repeated treatments.

Limits to evaluate the role of PDT treatment in our study were that no differentiation was made in subgroups for the different types of PDT (standard, low-fluence and half-dose) and no standard parameters were used for the treatment.

Intravitreal anti-VEGF

The target of anti-VEGF therapy is to regress neovascular vessels and reduce vascular permeability. Therefore, anti-VEGFs could be effective in eyes with CSCR that are complicated by secondary CNV. The role of IVT in acute and chronic CSCR that is not complicated by CNV is based on the theory that choroidal hyperpermeability is associated with increased expression of VEGF, although increased levels of VEGF have not been found in the aqueous humour of eyes with CSCR (Schaal et al. 2009; Seong et al. 2009; Lim et al. 2010; Shin & Lim 2011). However, Jung et al. (2014) showed that CSCR patients who responded to IVT bevacizumab had higher VEGF levels in aqueous humour compared with those who did not respond.

There are various anti-VEGF agents used in ophthalmology, but none of these has been approved specifically for use in the treatment of CSCR. Reports about treatment of CSCR with IVT of bevacizumab are uncontrolled, have a small number of patients and a short follow-up period (Torres-Soriano et al. 2008; Huang et al. 2009; Schaal et al. 2009; Seong et al. 2009).

In our study, the OR (1.9) for obtaining a partial or complete resolution of subretinal fluid (SRF) with IVT

anti-VEGF compared with observation did reach statistical significance in favour of injections. BCVA improved from baseline to 1 month and there was practically no change from 3 to 12 months (Figs 1 and 2). Compared with the observation group, the number of recurrences was higher. Same is valid for the percentage of persistent CSCR in the IVT group at the end of the follow-up, which was 45% and higher compared with all other groups studied. Interpretation of the outcome in this subgroup with anti-VEGF treatment is difficult. As a lower VA at baseline, a greater tendency for recurrences and persistence of the disease (Table 2) was stated, some cases with AMD misdiagnosed for CSRC might have been included.

Micropulse laser photocoagulation

Micropulse diode or argon laser treatment includes a succession of repetitive ultrashort laser pulses targeting the RPE (Sivaprasad et al. 2010). The aim of treatment is to improve RPE function. Direct effects at the points of leakage identified in FA are obtained on the RPE and only a minor thermal energy is released to the choroid and neurosensory retina, and thus avoiding to damage to those structures (Ricci et al. 2004; Chen et al. 2008; Roisman et al. 2013). Traditionally, aiming at focal leakage outside the macula with argon laser photocoagulation was more commonly used; however, treatment with micropulse laser is now increasing in use.

Chen et al. (2008) examined 26 CSCR eyes. At the end of follow-up, the average preoperative foveal thickness was reduced by more than half. A gain in VA of three lines or more was achieved in 58% of eyes, and a gain of between one and three lines was achieved in 23% of eyes.

Ricci et al. (2004) described a case series of seven patients presenting with CSCR with well-defined active leaking sites suitable for laser treatment and with serous retinal detachment persisting for 6 or more months. At 4–8 weeks after micropulse laser, the neuroepithelial detachment had completely resolved in five patients and reduced in two patients. At the 12-month follow-up visits, no recurrence had occurred.

Only one randomized clinical trial has assessed diode micropulse laser versus argon laser photocoagulation

in acute CSCR. Patients in both groups had complete resolution of subretinal fluid at 12 weeks follow-up. No patients had scotomas in the micropulse group compared with 3 out of 15 patients in the argon laser group who had persistent scotomas. Contrast sensitivity was also significantly better in the micropulse laser group (Verma et al. 2004).

In our study, the OR (8.9) for obtaining a partial or complete resolution with micropulse laser treatment compared with observation showed that this treatment offers the best results with less variability compared with other groups. Best-corrected VA (BCVA) improved from baseline to 1 month, and there was practically no change from 3 to 12 months (Figs 1 and 2). The number of recurrences at 1 year was less compared with other treatment and the observation group. The percentage of persistent CSCR in the micropulse group at the end of the follow-up was inferior to the observation group with 35% and 39%, respectively (Table 2).

Possible limitations of micropulse laser photocoagulation evaluation in our study were that the type of laser (diode versus yellow) and parameters used for the treatment (spot diameter and treatment area) were not specifically noted.

Nonsteroidal anti-inflammatory eye drops

Central serous chorioretinopathy (CSCR) damage is thought to be caused by abnormal choroidal permeability, ischaemia and inflammation (Liegl & Ulbig 2014), with consequent exudative changes and neurosensory retinal detachment. Therefore, choroidal circulation could have an important role in CSCR pathogenesis due to abnormal coagulation and platelet aggregation leading to microthrombus formation and increased blood viscosity (Caccavale et al. 2011). Topical nonsteroidal anti-inflammatory therapies have been shown to inhibit prostaglandin (PG) synthesis and platelet aggregation and to stabilize cell membranes (Zhao et al. 2012).

Anti-inflammatory eye drops have usually been used in ophthalmology to control postoperative pain and posterior segment inflammatory diseases such as uveitis and cystoid macular oedema (Jones & Francis 2009; Wang et al. 2013). Topical nonsteroidal anti-

inflammatory therapies reduce production of cyclooxygenase enzymes and subsequent formation of PGs, acting on the iris and ciliary body and preventing vasodilation, blood–ocular barrier disruption, leucocyte migration and pain (Kim et al. 2010; Russo et al. 2013). Therefore, topical anti-inflammatory therapies may inhibit choroidal inflammation and ischaemic processes that may be involved in CSCR pathogenesis.

In our study, the OR (1.8) for obtaining a partial or complete resolution with nonsteroidal anti-inflammatory therapies compared with observation was not statistically significant. Best-corrected VA (BCVA) improved from baseline to 1 month. The eye drops and observation groups were the only ones that had a slight increase in BCVA from 3 to 12 months, probably because patients with a less severe disease were selected in these groups (Figs 1 and 2). The number of recurrences was higher than in the observation group. The percentage of persistence of CSCR in the eye drops group at the end of the follow-up was less compared with the observation group with 28% and 39%, respectively (Table 2).

Limitations to evaluate the effect of nonsteroidal anti-inflammatory eye drops in our study were that no differentiation was made in subgroups for the different nonsteroidal anti-inflammatory medications (bromfenac, nepafenac and fluorometholone) and no standard parameters were used for treatment (number of daily applications and therapy period).

Other therapies

The OR (2.7) for obtaining a partial or complete resolution with other treatments compared with observation showed no statistically significant results. The number of recurrences at 1 year was less than in the observation group, but the percentage of persistent CSCR in other groups at the end of the follow-up was higher compared with the observation group with 42% and 39%, respectively (Table 2).

As more than 15 different therapeutic regimes were performed, statistical analysis was not possible and meaningful results could not obtain.

In conclusion, decision-making of CSCR treatment remains difficult for

ophthalmologists and therapeutic option remain controversial. Spontaneous resolution has been described in a high percentage of patients, but the individual course is unpredictable. In fear of irreversible functional and structural damage in long-standing or chronic disease, different treatments modalities have been suggested and proposed as being efficaciously.

This is the first study evaluating different treatment options of CSCR in a large number of patients. Laser (micropulse and thermal) and PDT apparently lead to significant anatomical improvements; however, there is little change beyond the first month of treatment. Limitations of this study are their retrospective, nonrandomized character, and that treatment criteria and the choice of therapy did not follow a strict protocol. Thus, despite the large number of cases, the question on effective treatment(s) needs further investigations. In view of the high proportion of improvements and resolution of SRF even in the long run, setting up a study design for CSCR remains difficult.

References

- Bujarborua D, Nagpal PN & Deka M (2010): Smokestack leak in central serous chorioretinopathy. *Graefes Arch Clin Exp Ophthalmol* **248**: 339–351.
- Caccavale A, Romanazzi F, Imparato M, Negri A, Morano A & Ferentini F (2011): Central serous chorioretinopathy: a pathogenetic model. *Clin Ophthalmol* **5**: 239–243.
- Cardillo Piccolino F, Eandi CM, Ventre L, Rigault de la Longrais RC & Grignolo FM (2003): Photodynamic therapy for chronic central serous chorioretinopathy. *Retina* **23**: 752–763.
- Chan W-M, Lam DSC, Lai TYY, Tam BSM, Liu DTL & Chan CKM (2003a): Choroidal vascular remodelling in central serous chorioretinopathy after indocyanine green guided photodynamic therapy with verteporfin: a novel treatment at the primary disease level. *Br J Ophthalmol* **87**: 1453–1458.
- Chan WM, Lam DSC, Lai TYY, Yuen KSC, Liu DTL, Chan CKM & Chen WQ (2003b): Treatment of choroidal neovascularization in central serous chorioretinopathy by photodynamic therapy with verteporfin. *Am J Ophthalmol* **136**: 836–845.
- Chan W-M, Lai TYY, Lai RYK, Liu DTL & Lam DSC (2008): Half-dose verteporfin photodynamic therapy for acute central serous chorioretinopathy. *Ophthalmology* **115**: 1756–1765.
- Chen S-N, Hwang J-F, Tseng L-F & Lin C-J (2008): Subthreshold diode micropulse photocoagulation for the treatment of chronic central serous chorioretinopathy with juxtafoveal leakage. *Ophthalmology* **115**: 2229–2234.
- Dellaporta A (1976): Central serous retinopathy. *Trans Am Ophthalmol Soc* **74**: 144–151.
- Ficker L, Vafidis G, While A & Leaver P (1988): Long-term follow-up of a prospective trial of argon laser photocoagulation in the treatment of central serous retinopathy. *Br J Ophthalmol* **72**: 829–834.
- Gass JD (1977): Photocoagulation treatment of idiopathic central serous choroidopathy. *Trans Sect Ophthalmol Am Acad Ophthalmol Otolaryngol* **83**: 456–467.
- Gilbert CM, Owens SL, Smith PD & Fine SL (1984): Long-term follow-up of central serous chorioretinopathy. *Br J Ophthalmol* **68**: 815–820.
- Huang W-C, Chen W-L, Tsai Y-Y, Chiang C-C & Lin J-M (2009): Intravitreal bevacizumab for treatment of chronic central serous chorioretinopathy. *Eye* **23**: 488–489.
- Husain D, Kramer M, Kenny AG, Michaud N, Flotte TJ, Gragoudas ES & Miller JW (1999): Effects of photodynamic therapy using verteporfin on experimental choroidal neovascularization and normal retina and choroid up to 7 weeks after treatment. *Invest Ophthalmol Vis Sci* **40**: 2322–2331.
- Iida T, Kishi S, Hagimura N & Shimizu K (1999): Persistent and bilateral choroidal vascular abnormalities in central serous chorioretinopathy. *Retina* **19**: 508–512.
- Imamura Y, Fujiwara T, Margolis R & Spaide RF (2009): Enhanced depth imaging optical coherence tomography of the choroid in central serous chorioretinopathy. *Retina* **29**: 1469–1473.
- Jones J & Francis P (2009): Ophthalmic utility of topical bromfenac, a twice-daily nonsteroidal anti-inflammatory agent. *Expert Opin Pharmacother* **10**: 2379–2385.
- Jung SH, Kim K-A, Sohn SW & Yang SJ (2014): Cytokine levels of the aqueous humor in central serous chorioretinopathy. *Clin Exp Optom* **97**: 264–269.
- Kim SJ, Flach AJ & Jampol LM (2010): Nonsteroidal anti-inflammatory drugs in ophthalmology. *Surv Ophthalmol* **55**: 108–133.
- Kitzmann AS, Pulido JS, Diehl NN, Hodge DO & Burke JP (2008): The incidence of central serous chorioretinopathy in Olmsted County, Minnesota, 1980–2002. *Ophthalmology* **115**: 169–173.
- Klein ML, Van Buskirk EM, Friedman E, Gragoudas E & Chandra S (1974): Experience with nontreatment of central serous choroidopathy. *Arch Ophthalmol (Chicago, Ill 1960)* **91**: 247–250.
- Lai TYY, Chan W-M & Lam DSC (2004): Transient reduction in retinal function revealed by multifocal electroretinogram after photodynamic therapy. *Am J Ophthalmol* **137**: 826–833.
- Lai TYY, Chan W-M, Li H, Lai RYK, Liu DTL & Lam DSC (2006): Safety enhanced photodynamic therapy with half dose verteporfin for chronic central serous chorioretinopathy: a short term pilot study. *Br J Ophthalmol* **90**: 869–874.
- Leaver P & Williams C (1979): Argon laser photocoagulation in the treatment of central serous retinopathy. *Br J Ophthalmol* **63**: 674–677.
- Liegl R & Ulbig MW (2014): Central serous chorioretinopathy. *Ophthalmologica*, **232**: 65–76.
- Lim JW, Kim MU & Shin M-C (2010): Aqueous humor and plasma levels of vascular endothelial growth factor and interleukin-8 in patients with central serous chorioretinopathy. *Retina* **30**: 1465–1471.
- Mancia G, Fagard R, Narkiewicz K et al. (2013): 2013 ESH/ESC Guidelines for the management of arterial hypertension. *Blood Press* **22**: 193–278.
- Maruko I, Iida T, Sugano Y, Ojima A, Ogasawara M & Spaide RF (2010): Subfoveal choroidal thickness after treatment of central serous chorioretinopathy. *Ophthalmology* **117**: 1792–1799.
- Miller S & Farber D (1984): Cyclic AMP modulation of ion transport across frog retinal pigment epithelium. Measurements in the short-circuit state. *J Gen Physiol* **83**: 853–874.
- Nicholson B, Noble J, Forooghian F & Meyerle C (2013): Central serous chorioretinopathy: update on pathophysiology and treatment. *Surv Ophthalmol* **58**: 103–126.
- Photodynamic therapy of subfoveal choroidal neovascularization in age-related macular degeneration with verteporfin: one-year results of 2 randomized clinical trials—TAP report. Treatment of age-related macular degeneration with photodynamic therapy (TAP) Study Group (1999): *Arch Ophthalmol (Chicago, Ill 1960)* **117**: 1329–1345.
- Prünke C & Flammer J (1996): Choroidal capillary and venous congestion in central serous chorioretinopathy. *Am J Ophthalmol* **121**: 26–34.
- Reibaldi M, Cardascia N, Longo A et al. (2010): Standard-fluence versus low-fluence photodynamic therapy in chronic central serous chorioretinopathy: a nonrandomized clinical trial. *Am J Ophthalmol* **149**: 307–315.e2.
- Ricci F, Missiroli F & Cerulli L (2004): Indocyanine green dye-enhanced micropulsed diode laser: a novel approach to subthreshold RPE treatment in a case of central serous chorioretinopathy. *Eur J Ophthalmol* **14**: 74–82.
- Robertson D (1986): Argon laser photocoagulation treatment in central serous chorioretinopathy. *Ophthalmology* **93**: 972–974.
- Robertson DM & Ilstrup D (1983): Direct, indirect, and sham laser photocoagulation in the management of central serous chorioretinopathy. *Am J Ophthalmol* **95**: 457–466.
- Roisman L, Magalhães FP, Lavinsky D, Moraes N, Hirai FE, Cardillo JA & Farah ME (2013): Micropulse diode laser

- treatment for chronic central serous chorioretinopathy: a randomized pilot trial. *Ophthalmic Surg Lasers Imaging Retina* **44**: 465–470.
- Russo A, Costagliola C, Delcassi L, Parmegiani F, Romano MR, Dell’Omo R & Semeraro F (2013): Topical nonsteroidal anti-inflammatory drugs for macular edema. *Mediators Inflamm* **2013**: 476525. <https://doi.org/10.1155/2013/476525> [Epub ahead of print].
- Schaal KB, Hoeh AE, Scheuerle A, Schuett F & Dithmar S (2009): Intravitreal bevacizumab for treatment of chronic central serous chorioretinopathy. *Eur J Ophthalmol* **19**: 613–617.
- Schlötzer-Schrehardt U, Viestenz A, Naumann GOH, Laqua H, Michels S & Schmidt-Erfurth U (2002): Dose-related structural effects of photodynamic therapy on choroidal and retinal structures of human eyes. *Graefes Arch Clin Exp Ophthalmol* **40**: 748–757.
- Schmidt-Erfurth U, Michels S, Barbazetto I & Laqua H (2002): Photodynamic effects on choroidal neovascularization and physiological choroid. *Invest Ophthalmol Vis Sci* **43**: 830–841.
- Seong HK, Bae JH, Kim ES, Han JR, Nam WH & Kim HK (2009): Intravitreal bevacizumab to treat acute central serous chorioretinopathy: short-term effect. *Ophthalmologica* **223**: 343–347.
- Shin MC & Lim JW (2011): Concentration of cytokines in the aqueous humor of patients with central serous chorioretinopathy. *Retina* **31**: 1937–1943.
- Singh RB, Suh IL, Singh VP et al. (2000): Hypertension and stroke in Asia: prevalence, control and strategies in developing countries for prevention. *J Hum Hypertens* **14**: 749–763.
- Sivaprasad S, Elagouz M, McHugh D, Shona O & Dorin G (2010): Micropulsed diode laser therapy: evolution and clinical applications. *Surv Ophthalmol* **55**: 516–530.
- Spaide RF, Hall L, Haas A et al. (1996): Indocyanine green videoangiography of older patients with central serous chorioretinopathy. *Retina* **16**: 203–213.
- Spitznas M (1986): Pathogenesis of central serous retinopathy: a new working hypothesis. *Graefes Arch Clin Exp Ophthalmol* **224**: 321–324.
- Tarantola RM, Law JC, Recchia FM, Sternberg P & Agarwal A (2008): Photodynamic therapy as treatment of chronic idiopathic central serous chorioretinopathy. *Lasers Surg Med* **40**: 671–675.
- Torres-Soriano ME, García-Aguirre G, Konjara V, Ustariz-González O, Abraham-Marín M, Ober MD & Quiroz-Mercado H (2008): A pilot study of intravitreal bevacizumab for the treatment of central serous chorioretinopathy (case reports). *Graefes Arch Clin Exp Ophthalmol* **246**: 1235–1239.
- Tzekov R, Lin T, Zhang K-M et al. (2006): Ocular changes after photodynamic therapy. *Invest Ophthalmol Vis Sci* **47**: 377–385.
- Uyama M, Matsunaga H, Matsubara T, Fukushima I, Takahashi K & Nishimura T (1999): Indocyanine green angiography and pathophysiology of multifocal posterior pigment epitheliopathy. *Retina* **19**: 12–21.
- Verma L, Sinha R, Venkatesh P & Tewari HK (2004): Comparative evaluation of diode laser versus argon laser photocoagulation in patients with central serous retinopathy: a pilot, randomized controlled trial [ISRCTN84128484]. *BMC Ophthalmol* **4**: 15.
- Wang M, Munch IC, Hasler PW, Prunte C & Larsen M (2008): Central serous chorioretinopathy. *Acta Ophthalmol* **86**: 126–145.
- Wang QW, Yao K, Xu W et al. (2013): Bromfenac sodium 0.1%, fluorometholone 0.1% and dexamethasone 0.1% for control of ocular inflammation and prevention of cystoid macular edema after phacoemulsification. *Ophthalmologica* **229**: 187–194.
- Yannuzzi LA (1986): Type A behavior and central serous chorioretinopathy. *Trans Am Ophthalmol Soc* **84**: 799–845.
- Zhao M-W, Zhou P, Xiao H-X, Lv Y-S, Li C-A, Liu G-D & Li X-X (2009): Photodynamic therapy for acute central serous chorioretinopathy. *Retina* **29**: 1155–1161.
- Zhao L, Qu Y, Li M & Wang Y (2012): Quantitative evaluation by optical coherence tomography of prophylactic efficiency of Pranopulin on macular edema after cataract surgery. *Chin Med J* **125**: 4523–4525.
- Antonia Striebe, Nicolas Feltgen, Hans Hoerauf, Umit Ubeyt Inan, Ivan Tanev, Agnieszka Dyrda, Andreas Schüler, Klaus Lucke, Silvia Bopp, Alexandra Brix, Stefanie Pape, Christine Kusserow-Napp, P Angela Loo, Ayşe Yağmur Kanra, Aylin Ardagil Akçakaya, Sevil Arı Yaylalı, SH Bae, HK Kim, SJ Kim, JR Han, WH Nam, Dominik Odrobina, Eleonora Lavague, Enrico Bertelli, Stefano Coser, Focke Ziemssen, Matteo Forlini, Caterina Benatti, Gian Maria Cavallini, Jana Stefanickova, Jean-Paul Berrod, Stanislav Saksonov, Lyubomyr Lytvinchuk, Magdy Moussa, Maria Stefanidou, Eleni Christodoulou, Mohamed Amin Zayed, Ozay Oz, Paolo Tassinari, Philippe Koch, Christophe Declercq, Richard Johnston, Stepan Rusnak, Susana Penas, Sengul Ozdek, Yucel Ucgul, Slawomir Cisiecki, Krzysztof Dziegielewski, Dobromila Klimczak, Zofia Michalewska, Janusz Michalewski, Zofia Nawrocka, Jerzy Nawrocki, Katarzyna Ornafeł, Zbigniew Pikulski, Maciej Maciej, Nur Acar, Maha M Elshafei, Frédéric Hamon, Rita Soyeur, Idriss Badat, Bénédicte Brousseau, Elisabeth Hermouet, Enrico Peiretti, Jung-Ho Lee, Natalia Ferreira, Hee-Seong Yoon, Wajeeha I Alkhars, Ajay Dudani, R Minu, Omkar Telang, Vrunda G MorePatil, Maria João Furtado, Young-Joon Jo, FC Piccolino, Barbara Parolini, Alessandro Finzi.

Appendix 1

Mehmet Citirik, Kemal Tekin, Ivan Fiser, Camiel JF Boon, Van Dijk EHC, Giuseppe Donvito, Hülya Güngel, Sezin Özdoğan Erkul, Erkan Ünsal, Özen Osmanbaşoğlu, Nurhan Dinçer, Nimet Yeşim Erçalık, Nursal Melda Yenerel, Jean-Paul Amar, Anton Ennemoser, Gianluca Besozzi, Ahmed AB Sallam, Abdallah A Ellabban, Woo-hyok Chang, Chiara Maria Eandi, Mehmet Demir, Mario R Romano, Jieun Lee, Kangyeun Pak, Luis Arrevola, Agata Sloka, Krzysztof Morawski, Agnieszka Kulig - Stochmal, Bożena Romanowska - Dixon, Nina-

Received on January 9th, 2019.
Accepted on November 2nd, 2019.

Correspondence:
Davide Allegrini
Humanitas Gavazzeni, Humanitas University
Via M Gavazzeni 21- 20135 Bergamo
Italy
Tel/Fax: + 39 035 280820
Email: davideallegrini@yahoo.it

See Appendix 1.

This research was partly funded by Novartis Pharma GmbH, Germany. The funder had no role in study design, data analysis, decision to publish or preparation of the manuscript.